

Treatment and outcomes of ureter injuries due to ovariohysterectomy complications in cats and dogs

B. L. Plater* and V. J. Lipscomb^{1,*}

*Queen Mother Hospital for Animals, Royal Veterinary College, University of London, Hatfield, Hertfordshire AL9 7TA, UK

Corresponding author email: vlipscomb@rvc.ac.uk

Objectives: To describe the presentation, treatment and outcome of unilateral and bilateral ureter injuries resulting from ovariohysterectomy complications in cats and dogs. **Materials and Methods:** Retrospective case series of cats and dogs with ureteric injuries resulting from an ovariohysterectomy complication. Patient signalment, history, presenting clinical signs, clinical pathology, imaging, diagnosis, treatment and outcome were obtained from the medical records and telephone contact with the owners.

Results: Fourteen female cats and five female dogs were included. Eleven (58%) exhibited clinical signs immediately after recovery from ovariohysterectomy, six (32%) had a median onset of clinical signs of 3days (range 1 to 16days), and two (10%) were referred immediately because of a known complication during surgery. Five of seven animals with bilateral ureter injury presented with anuria. Three animals died or were euthanased without definitive surgery. Surgical repair included ureteroneocystostomy (eight cats, one dog), ureteronephrectomy (four cats, two dogs), subcutaneous ureteral bypass placement (three cats) and ureteral stent (one cat). Of the 16 operated animals, seven (44%) that were discharged from the hospital experienced major complications requiring one or more additional surgeries. Overall outcome was excellent in 13 (68%), good in one (5%), fair in one (5%) and poor in four (22%) animals.

Clinical Significance: A key indicator of a ureteric injury is an animal failing to recover normally or becoming unwell shortly after ovariohysterectomy. Anuria is likely in animals with bilateral ureter injury. Excellent outcomes are possible following surgical treatment.

Introduction:

Ureteric injury is a recognised complication of neutering surgeries, especially ovariohysterectomy (Van Goethem et al. 2006, Adin 2011, Haimade 2016). However, there are few published reports on the presentation and types of ureter injury that can occur, as well as the treatment options and

outcome following these injuries. Case reports have described the presentation and treatment of one or two female cats or dogs suffering from ureter ligation and/or transection (Nwadike et al. 2000, Mehl & Kyles 2003, Kang et al. 2007, Ávila Filho et al. 2014, Johnson et al. 2015, Wormser et al. 2015), concurrent ureter and bladder ligation (Ewers & Holt 1992), ureter resection (Kyles et al. 1996) and ureter occlusion secondary to adhesions or granuloma formation at the ovarian or cervical stumps (Ruiz de Gopegui et al. 1999, Kanazono et al. 2009, Cerqueira da Silva 2016) following ovariohysterectomy. The repair methods used in these case reports were variable, including end-to-end ureter anastomosis with or without stent placement (Mehl & Kyles 2003, Kanazono et al. 2009, Wormser et al. 2015), ureteronephrectomy (Kyles et al. 1996, Kang et al. 2007, Ávila Filho et al. 2014, Cerqueira da Silva 2016), ureteroneocystostomy (Nwadike et al. 2000) and subcutaneous ureteral bypass (SUB) placement (Johnson et al. 2015). One dog with bilateral ureter injuries, end-stage renal failure and concurrent adrenal neoplasia was euthanased (Ruiz de Gopegui et al. 1999), and a cat with bilateral ureter transection was successfully treated with bilateral neoureterostomy (Nwadike et al. 2000). The other reports involved animals with unilateral ureter injuries, all of which survived corrective surgeries with only minor complications (Kyles et al. 1996, Mehl & Kyles 2003, Kang et al. 2007, Kanazono et al. 2009, Ávila Filho et al. 2014, Johnson et al. 2015, Wormser et al. 2015, Cerqueira da Silva 2016). Animals in which the ureter was ligated or transected were treated within 3 weeks (Ewers & Holt 1992, Kyles et al. 1996, Nwadike et al. 2000, Mehl & Kyles 2003, Kang et al. 2007, Ávila Filho et al. 2014, Johnson et al. 2015, Wormser et al. 2015), whereas those in which ureter obstruction was secondary to adhesions and/or granuloma formation were not detected until years after the neutering surgery when end-stage renal failure developed (Ruiz de Gopegui et al. 1999, Kanazono et al. 2009, Cerqueira da Silva 2016). The clinical presentation and clinical pathology of animals with ureteric obstruction are variable depending on whether the obstruction is partial or complete, unilateral or bilateral (Shipov & Segev 2013, Haimade 2016). Ureter injury as a result of ovariohysterectomy surgery is a serious complication, which is probably under-recognised and/or under-reported (Adin 2011, Haimade 2016). These types of complications also have the potential to cause significant emotional impact for the owners and veterinarians involved, especially if the surgery was elective. This impact may be compounded by the financial costs of further surgical intervention, especially if the animal presents as an emergency or is critically ill. Due to the sparse literature and variety of presentations, there is little guidance for the identification of ureteric injuries caused by ovariohysterectomy; the treatment options available; or the expected outcomes for the animal, especially if the injuries are bilateral. Therefore, the aim of this study was to describe the presentation, treatment and outcome of unilateral and bilateral ureteric injuries caused by ovariohysterectomy complications in a series of cats and dogs.

Materials and Methods

Medical records at our institution were searched for cats and dogs that were treated for a ureteric injury caused by ovariectomy or ovariohysterectomy surgery complication between January 2010 and July 2018. Patient signalment, history, presenting clinical signs, clinical pathology, imaging, diagnosis, treatment and outcome were obtained from the medical records. Owners of animals that were discharged from the hospital were contacted to establish the cause of death if that patient was no longer alive. Complications of surgical interventions performed to treat ureteric injury were defined as major if they resulted in further unplanned surgery; all other complications were classed as minor. The outcome for each animal was categorised as either excellent (clinically normal, no azotaemia), good (clinically normal but with azotaemia), fair (persistent clinical signs, with or without azotaemia) or poor (died or euthanased as a consequence of the initial ureteric injury). Data were assessed for normality, and data that were not normally distributed were described using median and range.

Results

Fourteen female cats and five female dogs were included in the study. The median age of cats at the time of neutering was 179 days (range 129 to 543 days). Cat breeds included 12 domestic shorthairs, one British shorthair and one ragdoll. The median age of dogs at the time of neutering was 1111 days (range 352 to 3102 days). Dog breeds were a Maltese terrier, Staffordshire bull terrier, Irish red and white setter, cavalier King Charles spaniel and a Chihuahua. Ovariohysterectomy was the neutering procedure in all animals, which was elective in all 14 cats and two of the five dogs. Details of the original surgeries performed are outlined in Table 1. Median time from neutering to referral was 5 days for cats (range 0 to 33 days) and 3 days for dogs (range 0 to 14 days). The presenting clinical signs are described in Table 1. Anuria was observed in five of the seven animals with bilateral ureter obstruction, although it was not always recognised as a critical finding in a timely manner. With the exception of bradycardia and palpably enlarged kidney(s), which were only reported in cats, there were no notable differences between species in relation to these signs. Eleven (58%) animals exhibited clinical signs from recovery from the ovariohysterectomy surgery; six (32%) animals had delayed onset of clinical signs with a median time to onset of 3 days (range 1 to 16 days). Two animals (10%) were referred immediately because of known complications during surgery, irrespective of the development of clinical signs. All animals received a complete blood count and biochemistry panel on presentation to our institution. In cats, median creatinine was 149 $\mu\text{mol/L}$ (range 92 to 1782 $\mu\text{mol/L}$), and median potassium was 5.0 mmol/L (range 3.8 to 11.1 mmol/L). In

dogs, median creatinine was 457 μ mol/L (range 84 to 1237 μ mol/L) and median potassium was 5.86mmol/L (range 5.4 to 6.4mmol/L). In animals with unilateral ureter injury, median creatinine was 106 μ mol/L (range 84 to 993 μ mol/L), and median potassium was 4.91mmol/L (range 3.8 to 6mmol/L). In animals with bilateral ureter injury, median creatinine was 1092 μ mol/L (range 457 to 1782 μ mol/L), and median potassium was 6.3mmol/L (range 5.4 to 11.1mmol/L). Four of five dogs (80%) had leucocytosis compared with only one cat (7%). Eleven cats had metabolic acidosis (79%) compared with none of the dogs. Eighteen animals underwent imaging of the urinary tract after presentation to our institution with at least one abnormality detected on every study that was performed, the details of which are outlined in Table 1. The diagnosis and nature of ureter injury (Table 2) was confirmed at surgery in 13 cats (Fig. 1) and at post mortem examination in one cat (Fig. 2). Unilateral ureter injury occurred in nine of 14 cats (64%), of which seven affected the left ureter. Ureter injury resulted in uroabdomen (Fig. 1) in five cats (36%) and urinoma in four cats (29%). The surgical interventions the cats received are outlined in Table 2. The diagnosis and nature of ureter injury (Table 2) was confirmed at surgery in four dogs and at post mortem examination in one dog. Unilateral ureter injury occurred in three of five dogs (60%), of which two affected the right ureter. The two dogs with bilateral ureter injury also had concurrent bladder neck ligation. Ureter injury resulted in uroabdomen in two dogs (40%). The surgical intervention the dogs received is outlined in Table 2. Of the 16 animals that were discharged from the hospital, six cats and one dog (7 of 16, 44%) required one or more additional surgeries due to major complications (Table 2). Major complications occurred in 3 of 12 (25%) unilateral ureter injuries and in 4 of 4 (100%) bilateral ureter injuries in animals that survived to discharge (Table 2). All seven animals (100%) that had a major complication had undergone a neoureterostomy surgery (Table 2). Minor complications following surgery were sterile cystitis in one cat and seroma formation in one dog. All 16 animals that survived to discharge were followed up from medical records and telephone contact with their owners for a median of 475days (range 91 to 1946days). One dog died of unrelated causes, one dog was euthanased for chronic pyelonephritis in the remaining kidney, and the remaining animals are still alive. The overall outcome for the 19 animals was excellent in 13 (68%), good in one (5%), fair in one (5%) and poor in four (22%). Outcome in relation to median creatinine values at presentation, time from neutering to admission, types of surgery performed and whether the ureter injury was unilateral or bilateral is described in Table 3.

Discussion

This is the first retrospective study describing in detail the presentation, treatment and outcome of unilateral and bilateral ureter injuries caused by an ovariohysterectomy complication in a series of

cats and dogs. The need to enter the abdominal cavity for ovariohysterectomy procedures, along with the close proximity of the female reproductive tract and ureters in the abdomen, gives rise to the possibility of injury to one or both ureters during this surgery (Adin 2011, Haimade 2016). All female neutering procedures in this study were ovariohysterectomies, reflecting the common surgical practice in this population of animals, with both cats and dogs demonstrating a range of proximal and distal ureteric trauma injuries. In a previous study of 109 dogs undergoing elective ovariohysterectomy, two dogs suffered proximal ureter ligation within the ovarian pedicle, and three dogs suffered distal ureter ligation within the cervical pedicle (Okkens et al. 1981). Elective ovariectomy may be preferable to elective ovariohysterectomy because it eliminates the risk of a distal ureter injury, although overall complication rates for both surgeries are low (Van Goethem et al. 2006). Cats predominated in this study for reasons that are unclear, although it is possible that it could be because of their generally smaller size. It is interesting to note that all cats underwent an elective neutering surgery and that complications occurred in cats following both flank or midline ovariohysterectomy approaches. In contrast, some dogs had undergone ovariohysterectomy for non-elective reasons such as concurrent Caesarean or pyometra. While abdominal incision length, and therefore exposure, may often be greater for non-elective ovariohysterectomy, these surgeries may also present a greater challenge compared with elective ovariohysterectomy because of the increased size of the vasculature, as well as the size and weight of the altered reproductive tract within the abdominal cavity. Similar to previous case reports, presenting clinical signs of ureter injury following neutering in this study were non-specific (e.g. anorexia, vomiting, lethargy) with no single sign shared by all animals, although five of seven animals with bilateral ureter obstruction were anuric. The other two animals with complete bilateral ureter obstruction must have been anuric, but this was likely forgotten or not mentioned in the patient history. Importantly, the clinical signs consistently developed immediately or shortly after neutering in the vast majority of animals. Therefore, the appearance of one or more clinical signs following neutering should raise suspicion that a neutering complication has occurred, prompting careful further history-taking, including enquiring about urination, a thorough clinical examination and further investigations as appropriate. It is also helpful to think of the opposite scenario when considering an animal's recovery from an uncomplicated elective ovariohysterectomy where the effects of the surgery and anaesthesia have usually disappeared by the following day, resulting in a rapid return to normal. Therefore, attributing ongoing non-specific signs of lethargy, anorexia and vomiting over several days to an elective neutering procedure or anaesthetic will result in animals being diagnosed with a problem later than necessary and, in the case of ureteric injury, this can have a huge impact

on the potential for renal recovery (Kerr 1956, Fink et al. 1980). A few animals with unilateral ureter injuries in this study had extremely delayed presentations and excellent outcomes following ureteronephrectomy, which occurred despite renal function on the affected side being destroyed. Increased serum creatinine associated with bilateral ureter injuries or uroabdomen is a useful indicator of the severity or urgency of the problem (Adin 2011, Shipov & Segev 2013, Haimade 2016) also noted in our study. Some animals presenting with marked azotaemia had excellent outcomes, so this should not preclude surgical treatment. The most reliable tool for the diagnosis of ureter obstruction before surgery is imaging (Adin 2011, Shipov & Segev 2013, Haimade 2016), which demonstrated abnormalities in all animals in this study and was critical for surgical planning. In this study, ureteroneocystostomy was the initial procedure whenever possible. Ureteronephrectomy at initial surgery was reserved for an “end-stage” kidney or if the ureter was damaged in a proximal location or to such an extent that re-implantation or resection and anastomosis was not possible, similar to recommendations by others (Adin 2011, Haimade 2016). Ureteroneocystostomy surgery was life-saving in cats with bilateral ureteric injury and preserved renal function in other cats with unilateral injury but was associated with a high major complication rate that necessitated further surgery. Seven of nine animals that underwent ureteroneocystostomy surgery had a major complication, but six of these nine still had an excellent outcome. The complication rate associated with ureteroneocystostomy in these cats is unsurprising given the frequently inflamed tissues following the previous complicated neutering surgery, the often bilateral nature of the problem and the small feline ureter diameter, meaning the potential for stricture formation is high even when performed by experienced surgeons using surgical magnification. In this study, three of the cats with bilateral ureter injury also received an SUB for stabilisation at their initial surgery (alongside a subsequent ureteroneocystostomy), and all of them had the SUB removed at a further surgery. An alternative to SUB placement would be the use of temporary nephrostomy tubes (Nwadike et al. 2000) to stabilise cats with bilateral ureteric injuries before definitive ureteroneocystostomy in an attempt to avoid some of the problems that were associated with SUB placement, such as chronic infection and reduction of the available space around the bladder apex for ureter re-implantation. Overall, in our study, the majority of animals (68%) had an excellent outcome that is encouraging given the physiological damage that can occur; on the other hand, 22% of animals died or were euthanased due to the severity of their condition. Owners should be carefully counselled about the prognosis and treatment options, including being offered euthanasia where appropriate, although all owners in this study were committed to referral for their pet and keen to explore all possible treatment options. Ureteric injury caused by ovariohysterectomy is an entirely

preventable complication (Adin 2011, Haimade 2016). Although beyond the scope of this report, it appears reasonable to speculate that lack of visibility or exposure during surgery through a small incision or due to haemorrhage, surgical inexperience or variations in reproductive tract anatomy might be factors implicated in accidental ureter injury. Recommendations to avoid ureter injury during ovariohysterectomy (Kyles et al. 1996, Adin 2011, Haimade 2016) include: (a) a thorough knowledge of normal abdominal anatomy; (b) awareness of the close anatomical relationship between the ureters and female reproductive tract and appropriate surgical training; (c) emptying the bladder before surgery; (d) enlarging the abdominal incision, using retractors, excising the falciform fat; (e) using suction to remove blood or adjusting the surgical lighting to improve visibility during surgery; (f) enlisting the help of a surgical assistant or asking a colleague for advice if difficulties are encountered during surgery; and (g) realising it is probably safer to close the animal without completing the ovariohysterectomy if there is uncertainty or the correct anatomy cannot be identified. There are some limitations to this report. Due to the retrospective nature, the sample size and type of data collected could not be controlled, meaning that there were small groups and statistical comparisons between groups, or analysis for risk factors was not possible. The surgeries in this study, although from one institution, were performed by multiple surgeons alongside multiple critical care clinicians and anaesthetists. Conversely, because all animals were treated at a single tertiary referral centre, the data may not be representative of a larger population. In conclusion, we believe that ureter injuries following neutering are likely to be currently under-recognised, underreported and, therefore, under-treated. We hope that awareness is raised by this report, alongside provision of additional information on the presentation, diagnosis, treatment and prognosis of ureter injuries following neutering. A key indicator for suspicion of ureter injury is an animal failing to recover normally or becoming unwell shortly following neutering. Veterinarians should consider the possibility of ureteric injury and act quickly to obtain a diagnosis and reduce the risk of permanent loss of renal function. Animals with bilateral ureteric injury are likely to be anuric and azotaemic. A high serum creatinine or a long delay after neutering should not necessarily preclude treatment. Ureteroneocystostomy is preferred to ureteronephrectomy to preserve renal function and is usually a requirement for bilateral ureteric injuries but carries a high complication rate resulting in additional surgery (and therefore costs), albeit often with an excellent final outcome.

Acknowledgements

The authors thank the owners and referring veterinary surgeons of the animals in this study, as well as the other veterinary surgeons who operated on them at the Royal Veterinary College.

Conflict of interest

None of the authors of this article has a financial or personal relationship with other people or organisations that could inappropriately influence or bias the content of the paper

References

Adin, C. (2011) Complications of ovariohysterectomy and orchietomy in companion animals. *The Veterinary Clinics of North America* 41, 1023-1039

Ávila Filho, S. H., Silva, C. C. L., Moura, R. S., et al. (2014) Iatrogenic (ovariohysterectomy) hydronephrosis and hydroureter in a female boxer dog: case report.

Onderstepoort Journal of Veterinary Research 18, 369-376

Cerqueira da Silva, E. A. (2016) Postoperative complication of ovariohysterectomy in a female dog. *Brazilian Journal of Veterinary Medicine* 38, 9-16

Ewers, R. S. & Holt, P. E. (1992) Urological complications following ovariohysterectomy in a bitch. *The Journal of Small Animal Practice* 33, 236-238

Fink, R. L., Caridis, D. T., Chimile, R., et al. (1980) Renal impairment and its reversibility following variable periods of complete ureteral obstruction. *The Australian and New Zealand Journal of Surgery* 50, 77-83

Haimade, A. (2016) Chapter 71 Ovariectomy and ovariohysterectomy. In: *Complications in Small Animal*. Eds D. Griffon and A. Hamaide. Wiley Blackwell, Ames, IA

Johnson, C. M., Culp, W. T. N., Palm, C. A., et al. (2015) Subcutaneous ureteral bypass device for treatment of iatrogenic ureteral ligation in a kitten. *Journal of the American Veterinary Medical Association* 247, 924-931

Kanazono, S., Aikawa, T. & Yoshigae, Y. (2009) Unilateral hydronephrosis and partial ureteral obstruction by entrapment in a granuloma in a spayed dog. *Journal of the American Animal Hospital Association* 45, 301-304

Kang, B. T., Park, C., Jung, D. I., et al. (2007) Iatrogenic hydroureter and hydronephrosis following hysterotomy with ovariohysterectomy in a pregnant dog. *Korean Journal of Veterinary Research* 47, 213-217

Kerr, W. S. (1956) Effects of complete ureteral obstruction in dogs on kidney function. *American Physical Society* 184, 521-526

Kyles, A. E., Douglass, J. P. & Rottman, J. B. (1996) Pyelonephritis following inadvertent excision of the ureter during ovariohysterectomy in a bitch. *The Veterinary Record* 139, 471-472

Mehl, M. L. & Kyles, A. E. (2003) Ureteroureterostomy after proximal ureteric injury during an ovariohysterectomy in a dog. *The Veterinary Record* 153, 469-470

Nwadike, B. S., Wilson, L. P. & Stone, E. A. (2000) Use of bilateral temporary nephrostomy catheters for emergency treatment of bilateral ureter transection in a cat. *Journal of the American Veterinary Medical Association* 217, 1862-1965

Okkens, A. C., van de Gaag, I., Biewenga, W. J., et al. (1981) Urological complications following ovariohysterectomy in dogs. *Tijdschrift voor Diergeneeskunde* 106, 1189-1198

Ruiz de Gopegui, R. R., Espada, Y. & Majo, N. (1999) Bilateral hydroureter and hydronephrosis in a nine-year-old female German shepherd dog. *The Journal of Small Animal Practice* 40, 224-226

Shipov, A. & Segev, G. (2013) Ureteral obstruction in dogs and cats. *Israel Journal of Veterinary Medicine* 68, 71-77

Van Goethem, B., Schaefers-Okkens, A. & Kirpenstein, J. (2006) Making a rationale choice between ovariectomy and ovariohysterectomy in the dog: a discussion of the benefits of either technique. *Veterinary Surgery* 35, 136-143

Wormser, C., Clarke, D. L. & Aronson, L. R. (2015) End-to-end ureteral anastomosis and double-pigtail ureteral stent placement for treatment of iatrogenic ureteral trauma in two dogs. *Journal of the American Veterinary Medical Association* 247, 92-97

FIG 1. (a) Ventro-dorsal radiograph of an intravenous urogram demonstrating leakage of contrast from a traumatised left distal ureter in cat 13 following ovariohysterectomy. (b) Intra-operative photograph of the same cat showing the traumatised left distal ureter before transection through normal ureter further proximally at the level marked with an asterisk in order to perform a neoureterostomy

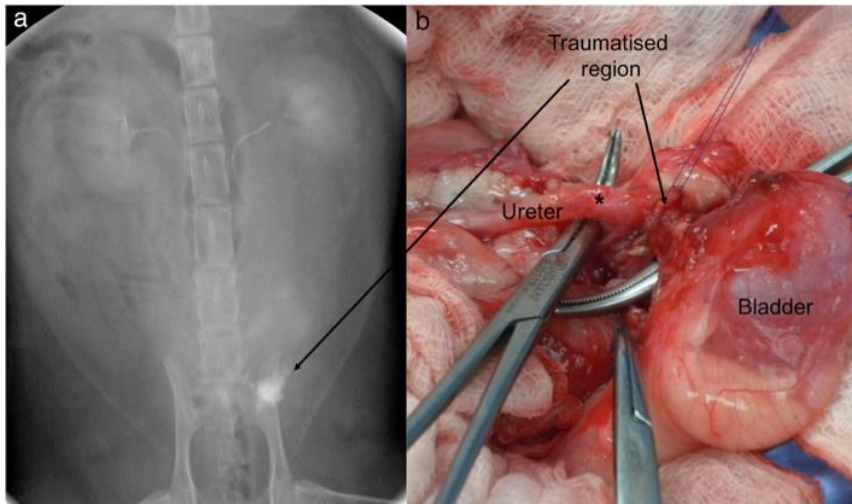


FIG 2. Post mortem examination picture of cat 14 with ligatures on both ureters and bilateral hydronephrosis following ovariohysterectomy. This cat died shortly after admission before any surgery could be performed.

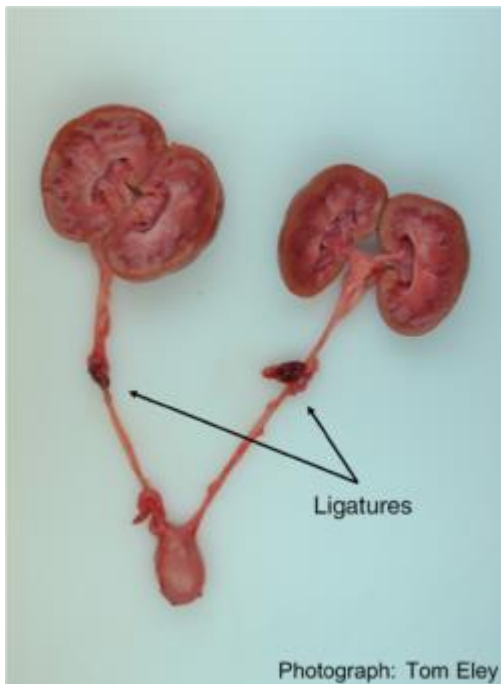


Table 1: Details of the original OVH surgery, clinical signs and imaging findings for each animal (IVU Intravenous urogram, P Pyelogram, OVH Ovariohysterectomy)

Details of original OVH surgery		Presenting clinical signs of ureteral injury	Ultrasound findings	IVU, P or CT IVU findings
Cat 1	Elective flank OVH	Anorexia, lethargy, abdominal pain, abdominal distension	Left hydronephrosis and retroperitoneal fluid accumulation (urinoma),	-

			peritoneal effusion	
Cat 2	Elective flank OVH	Anorexia, lethargy, abdominal pain, bradycardia, anuria	Bilateral hydronephrosis. Suture material around both mid-ureters visible.	IVU: Right kidney enlarged, right ureter dilated and fills irregularly.
Cat 3	Elective flank OVH	Referred immediately, so no signs noted	-	IVU: Left kidney enlarged, contrast does not enter left renal pelvis or ureter.
Cat 4	Elective flank OVH	Lethargy, abdominal distension	Left hydronephrosis and proximal ureteral dilation. Urinoma next to left kidney.	P: Contrast enters urinoma from ruptured left ureter.
Cat 5	Elective flank OVH	Anorexia, lethargy, vomiting	Left renal pelvis and proximal ureteral dilation. Uroperitoneum (confirmed on aspiration of fluid).	IVU: Left renal pelvis and ureter dilation, contrast extravasation from ruptured left ureter.
Cat 6	Elective flank OVH	Anorexia, lethargy, abdominal pain, bradycardia, anuria	Bilateral hydronephrosis, and proximal ureter dilation, peritoneal effusion, bladder empty.	P: abrupt stop to contrast in ureters bilaterally indicating obstruction.
Cat 7	Elective flank OVH followed by midline approach to address difficulties at the flank surgery	Referred immediately, so no signs noted	Left pyelectasia, left ureter cannot be followed.	P: Contrast fills dilated left renal pelvis and proximal left ureter only.
Cat 8	Elective flank OVH followed by midline approach to address difficulties at the flank surgery	Anorexia, lethargy, abdominal distension	Peritoneal fluid, difficult to visualise ureters.	IVU: Right proximal ureter rupture and left mid-ureter rupture causing leakage of contrast into abdomen.
Cat 9	Elective flank OVH followed by midline approach to address difficulties at the flank surgery	Anorexia, lethargy, bradycardia, anuria	-	P: Bilateral dilated renal pelvises and proximal ureters. No contrast entering distal ureters or bladder.
Cat 10	Elective flank OVH followed by midline approach to address difficulties at the flank surgery	Anorexia, vomiting, lethargy, enlarged kidneys on palpation	Right hydronephrosis and ureteral dilation. Left renal agenesis.	P: Dilated right renal pelvis. Right ureter dilated and tortuous, with contrast reaching bladder.
Cat 11	Elective flank OVH and flank incisional hernia repair 7 days later	Anorexia, vomiting, lethargy, pyrexia, abdominal pain	Left hydronephrosis and proximal ureteric dilation	-
Cat 12	Elective midline OVH	Anorexia, vomiting, lethargy, pyrexia, abdominal distension	Left kidney displaced by urinoma, mild dilation of left renal pelvis and proximal ureter. Left	P and CT IVU: Left ureter merges with urinoma. Contrast entering

			ureter merges with urinoma. Peritoneal effusion.	urinoma with some leakage of contrast into peritoneal cavity.
Cat 13	Elective midline OVH	Anorexia, lethargy, abdominal pain, dysuria, enlarged painful left kidney on palpation	Left-sided uroretroperitoneum (confirmed on aspiration).	IVU: left uroretroperitoneum caused by distal left ureteral injury.
Cat 14	Elective midline OVH and midline incisional hernia repair 4 days later	Anorexia, vomiting, lethargy, anuria	Bilateral hydronephrosis and proximal ureteric dilation. Ureters only visible to mid-ureter. Peritoneal effusion.	-
Dog 1	Elective midline OVH	Lethargy, abdominal pain	-	-
Dog 2	Elective midline OVH	Anorexia, vomiting, lethargy, abdominal pain, abdominal distension, seizures, was presented comatose	Bilateral hydronephrosis and ureteric dilation. Bladder not identifiable.	-
Dog 3	Midline OVH for pyometra	Anorexia, vomiting, lethargy, pyrexia, abdominal pain	Right hydronephrosis and proximal ureteral dilation.	CT IVU: Right hydronephrosis and partial right proximal ureteric obstruction.
Dog 4	Midline OVH following caesarean section	Anorexia, vomiting. Lethargy	Bilateral pyelectasia and dilated ureters. Peritoneal effusion.	CT IVU: Left ureter dilated and obstructed with no contrast entering bladder. Right ureter dilated but patent.
Dog 5	Midline OVH following caesarean section	Anorexia, vomiting, lethargy, anuria	Bilateral renal pelvis and ureteral dilation. No bladder identifiable.	-

Table 2: Details of the ureteral injury, original surgical interventions performed, follow-up surgeries performed to address major complications and outcome for each animal

(OVH Ovariohysterectomy, SUB subcutaneous ureteral bypass)

Unilateral or bilateral		Level of ureter injury	Description of ureteral injury at surgery or post-mortem examination	Original treatment and surgical interventions	Outcome
Cat 1	Unilateral	Proximal	Left ureteronephrectomy	-	Excellent
Cat 2	Bilateral	Proximal	Bilateral SUB placement followed by left ureteroneocystostomy and left renal descensus the following day.	Left SUB blocked. Bilateral SUB removal and right ureteronephrectomy.	Excellent
Cat 3	Unilateral	Proximal	Left ureteroneocystotomy, left cystonephropexy, and	Left ureteronephrectomy due to left ureteral	Excellent

			left renal descensus. Both ovaries removed.	obstruction	
Cat 4	Unilateral	Proximal	Left ureteroneocystostomy, left cystonephropexy.	Left ureteronephrectomy due to chronic pyelonephritis	
Cat 5	Unilateral	Distal	Left ureteroneocystostomy	-	Excellent
Cat 6	Bilateral	Distal	Bilateral SUB placement followed by bilateral ureteroneocystostomy 36 hours later.	Bilateral SUB removal due to chronic urinary tract infection, followed by right ureteronephrectomy due to right ureteral obstruction at a later date.	Good
Cat 7	Unilateral	Proximal and distal	Left ureteronephrectomy	-	Excellent
Cat 8	Bilateral	Proximal and distal	Left ureteral stent and right ureteroneocystostomy, right cystonephropexy, right renal descensus.	Left ureteral stent removal and bilateral SUB placement due to ureteral stent causing sterile cystitis signs, non-healing of left ureter rupture over stent and right ureter obstruction.	Excellent
Cat 9	Bilateral	Distal	Bilateral SUB placement followed by bilateral ureteroneocystostomy the following day	Bilateral SUB removal due to chronic urinary tract infection	Excellent
Cat 10	Unilateral	Proximal	Coeliotomy only, imaging findings confirmed no definitive treatment required.	-	Excellent
Cat 11	Unilateral	Proximal and distal	Left ureteronephrectomy. Removal of the remaining right ovary and right uterine horn.	-	Excellent
Cat 12	Unilateral	Proximal	Left ureteronephrectomy	-	Excellent
Cat 13	Unilateral	Distal	Left ureteronephrectomy	-	Fair (sterile cystitis)
Cat 14	Bilateral	Proximal	Arrested and died on induction of anaesthesia before any surgery.	N/A, died	Poor
Dog 1	Unilateral	Proximal	Right ureteronephrectomy	-	Excellent
Dog 2	Bilateral	Distal	Euthanasia performed after imaging without any surgery. Post mortem examination confirmed imaging findings.	N/A, died	Poor
Dog 3	Unilateral	Proximal	Right ureteronephrectomy		Excellent
Dog 4	Unilateral	Distal	Left ureteroneocystostomy and left lateral bladder repair.	Left ureteronephrectomy and later euthanased for chronic pyelonephritis in right kidney.	Poor

Dog 5	Bilateral	Distal	Euthanasia performed during surgery as injuries not treatable.	N/A, died	Poor
----------	-----------	--------	--	-----------	------