

This author's accepted manuscript may be used for non-commercial purposes in accordance with [Wiley Terms and Conditions for Self-Archiving](#).

The full details of the published version of the article are as follows:

TITLE: Variations in surgical technique for adrenalectomy with caudal vena cava venotomy in 19 dogs

AUTHORS: Knight RC, Lamb CR, Brockman DJ, Lipscomb VJ

JOURNAL: Veterinary Surgery

PUBLISHER: Wiley

PUBLICATION DATE: 25 January 2019 (online)

DOI: <https://doi.org/10.1111/vsu.13168>

1 **Full Title**

2 Variations in surgical technique for adrenalectomy with caudal vena cava venotomy in 19  
3 dogs

4

5 **Author Names**

6 Rebekah C. Knight BVetMed

7 Christopher R. Lamb MA, VetMB, Dipl.ACVR, Dipl.ECVDI

8 Daniel J. Brockman BVSc, Dipl.ACVS, Dipl.ECVS

9 Victoria J. Lipscomb MA, VetMB, Dipl.ECVS

10

11 **Institutional Affiliation**

12 Royal Veterinary College, London, UK

13

14 **Corresponding Author**

15 Victoria J. Lipscomb

16 Queen Mother Hospital for Animals, Hawkshead Lane, Hatfield, Hertfordshire, AL97TA

17 [vlipscomb@rvc.ac.uk](mailto:vlipscomb@rvc.ac.uk)

18

19 This data was presented as an oral abstract at the 2018 European College of Veterinary

20 Surgeons Annual Scientific Meeting in Athens.

21 **Abstract**

22 **Objective:** To describe variations in surgical technique and caval occlusions times in  
23 dogs undergoing adrenalectomy with caval venotomy.

24 **Study Design:** Retrospective case series.

25 **Animals:** Dogs undergoing adrenalectomy with caval venotomy from 2010 to 2018.

26 **Methods:** Medical records of dogs undergoing adrenalectomy with caval venotomy were  
27 reviewed for signalment, perioperative management, surgical details, perioperative  
28 complications, mortality, and histopathology. Computed tomography images were  
29 reviewed to describe tumor morphology and signs of thrombus extension.

30 **Results:** There were 19 dogs with adrenal tumor thrombi extending into the pre-hepatic  
31 (14 dogs, 74%), hepatic (3 dogs, 16%) and post-hepatic (2 dogs, 11%) caudal vena cava.  
32 The left adrenal gland (58%) was more commonly affected than the right (42%). Median  
33 caval occlusion was 6.5 minutes, ranging from 2 to 25 minutes. Between two and six  
34 vascular tourniquets were used. Venotomy closure was performed under full caval  
35 occlusion in 58% and using a partial occlusion clamp in 42%. Left ureteronephrectomy  
36 was performed in 26%. Peri-operative mortality rate was 21%.

37 **Conclusions:** Ureteronephrectomy is much more likely to be required on the left side.  
38 Venotomy closure under full occlusion was performed more commonly for right adrenal  
39 tumors. Number of vascular tourniquets used reflected the location of phrenicoabdominal  
40 vein insertion on the cava and length of the caval tumor thrombus. Longer caval  
41 occlusion than previously reported may be tolerated in some clinical cases.

42 ***Clinical Significance:*** Review of surgical technique for adrenalectomy with caval  
43 venotomy, including differences between right and left tumors, should provide useful  
44 information for surgeons planning this procedure.

45 **Introduction**

46 Extension of a tumor thrombus into the caudal vena cava (CVC) is reported in canine  
47 pheochromocytomas and adrenocortical adenocarcinomas. This finding adds complexity  
48 to the surgical procedure, and extends the surgical time because of the need for venotomy  
49 to remove the intracaval tumor thrombus (Figure 1).<sup>1-2</sup> There is conflicting data in the  
50 literature regarding CVC thrombus extension as a possible risk factor for perioperative  
51 mortality during adrenalectomy, probably reflecting variations in the extent of CVC  
52 thrombus between studies.<sup>2-7</sup> Also, there are few descriptions of the nature and extent of  
53 CVC invasion or the surgical techniques required to treat this, such as use of vascular  
54 tourniquets, partial versus complete occlusion, and methods of venotomy closure. There  
55 are no clinical studies that report the caval occlusion times required or tolerated during  
56 venotomy by any technique for dogs undergoing adrenalectomy.

57

58 One report of 10 dogs with adrenal tumors described the extent of CVC thrombus; eight  
59 dogs with pre-hepatic and one dog with an intra-hepatic CVC thrombus were treated by  
60 temporary CVC occlusion using two vascular tourniquets followed by CVC venotomy  
61 closure over a partial occlusion clamp, and one dog with an extensive intra-hepatic CVC  
62 thrombus, which was deemed non-resectable, died during surgery.<sup>2</sup> In a larger study of  
63 27 dogs with adrenal tumors invading the CVC, some dogs had a venotomy entirely  
64 performed over a partial occlusion clamp and others had venotomy closure over a partial  
65 occlusion clamp after the thrombus had been removed under full CVC occlusion.<sup>4</sup> The  
66 details of how many dogs were treated by each method, the number and location of  
67 vascular tourniquets, the duration of CVC occlusion and extent of the CVC thrombus

68 (pre, intra or post-hepatic CVC) were not reported.<sup>4</sup> In another report, three dogs had a  
69 CVC venotomy closed over a partial occlusion clamp.<sup>1</sup> The extent of tumor thrombi in  
70 these three dogs was not described, but two dogs also received a median sternotomy to  
71 help “milk” the tumor thrombus out through an abdominal CVC incision, which was  
72 performed separately to the adrenalectomy, i.e. the thrombus was not removed en bloc  
73 with the primary adrenal tumour.<sup>1</sup> In two reports, CVC venotomies for adrenal tumor  
74 removal were performed under full CVC occlusion, although neither describe the extent  
75 of the CVC invasions.<sup>5,6</sup> One study described seven dogs with adrenal tumor thrombus  
76 extension confined to the pre-hepatic CVC and seven dogs with CVC thrombus  
77 extending beyond the hepatic hilus, but no details of the surgical techniques used to  
78 excise the thrombi were included.<sup>3</sup>

79

80 The degree of thrombus extension (pre-hepatic, hepatic, post-hepatic), affected adrenal  
81 (left or right), location of the insertion of the phrenicoabdominal vein on the CVC (Figure  
82 2), width of the phrenicoabdominal vein (distended by tumor) and type of tumor invasion  
83 into the CVC (direct phrenicoabdominal vein extension, direct CVC wall invasion or  
84 extension via the renal vein) affects the complexity that extraction of the tumor via CVC  
85 venotomy represents and thus the surgical techniques employed, including the number  
86 and location of tourniquets for CVC occlusion (Figures 3 and 4), length of CVC  
87 occlusion time and choice of venotomy technique. The aim of the present study was to  
88 describe variations in surgical technique, with a rationale for doing so where appropriate,  
89 and the duration of temporary CVC occlusion in a series of dogs undergoing  
90 adrenalectomy with CVC venotomy for treatment of adrenal neoplasia.

91 **Materials and Methods**

92 Medical records were searched for dogs that had adrenalectomy with CVC venotomy for  
93 treatment of primary adrenal gland neoplasia between October 2010 and May 2018. Dogs  
94 were included if CVC venotomy was performed for adrenal tumor thrombectomy and  
95 pre-operative computed tomography (CT) images were available for review. Dogs with  
96 adrenal tumors and phrenicoabdominal vein invasion treated by adrenalectomy with  
97 phrenicoabdominal vein ligation only were excluded. Details of signalment, presenting  
98 clinical signs, pre-operative endocrine testing, pre-operative medication, anesthetic  
99 management and surgical technique (including number and location of tourniquets,  
100 length of CVC occlusion time and venotomy closure method), hospitalization time,  
101 perioperative complications, mortality, and histopathological analysis were recorded.  
102 Pre-operative CT examinations were acquired using a multi-slice scanner (MX8000 IDT,  
103 Phillips, Best, The Netherlands) and images reviewed using a proprietary DICOM viewer  
104 (Image Viewer Version 4.1, Visbion Ltd, Chertsey, UK). CT settings were helical  
105 acquisition, slice thickness up to 3mm, medium frequency ('soft tissue') reconstruction  
106 algorithm, with post-contrast CT images acquired 60 seconds after the start of  
107 intravenous injection of 2ml/kg of iohexol 300mg/ml (Omnipaque 300, GE Healthcare,  
108 Oslo, Norway). CT images were reviewed by a board-certified radiologist to determine  
109 size, shape and attenuation (Hounsfield units, HU) of the primary tumor, extent of  
110 vascular invasion, signs of invasion of other structures, and signs of metastasis. Length of  
111 extension of tumor thrombus into the CVC was categorized as pre-hepatic, hepatic or  
112 post-hepatic CVC.

113

114 *Pre-operative Management*

115 Initial evaluation included complete blood count, biochemistry and urine analysis.  
116 Endocrine testing was performed using the adrenocorticotrophic hormone (ACTH)  
117 stimulation test, low-dose dexamethasone suppression test, urine cortisol to creatinine  
118 ratio, and measurement of serum metanephrine and normetanephrine levels. Abdominal  
119 ultrasound was used in some cases for identification of the adrenal tumor, with thoracic  
120 and abdominal CT performed in all dogs for staging and surgical planning. Based on the  
121 results of endocrine testing dogs were treated medically prior to surgery with trilostane (if  
122 hyperadrenocorticism was confirmed) or phenoxybenzamine (if a pheochromocytoma  
123 was confirmed or suspected).

124

125 *Anesthetic Management*

126 The anesthetic protocol was tailored for each dog at the discretion of a board-certified  
127 anesthesiologist. Cefuroxime or amoxicillin-clavulanate (20mg/kg intravenously [IV])  
128 was administered at least 20 minutes prior to the first incision and every two hours during  
129 general anesthesia. Dogs with a cortisol secreting tumor were administered a constant  
130 rate intravenous infusion of hydrocortisone at 0.5 mg/kg/h from one hour pre-operatively  
131 and throughout surgery. Severe intra-operative hypertension and/or arrhythmias were  
132 treated with nitroprusside or lidocaine if necessary. Management of hypotension was by  
133 rapid expansion of volume by crystalloids, colloids and/or blood products, as well as  
134 administration of dopamine, dobutamine or epinephrine when required.

135

136 *Surgery*



137 A ventral midline celiotomy and full abdominal exploration was performed in all dogs,  
138 with extension to a median sternotomy in one dog. The adrenal mass was isolated from  
139 the surrounding tissues using a combination of blunt and sharp dissection with Mixer  
140 forceps, Metzenbaum scissors, hemoclips and diathermy until the only remaining  
141 attachment was the insertion of the phrenicoabdominal vein on the CVC (Figure 3). Left-  
142 sided tumors were passed underneath the mesentery so as to be the same side of the  
143 abdomen as the CVC to optimize exposure for the venotomy (Figure 4). Rummel  
144 tourniquets were placed around the abdominal CVC cranial and caudal to the tumor  
145 thrombus (Figure 3) and in some cases around one or both renal veins (Figure 4), the  
146 thoracic CVC and the portal vein and hepatic artery together at the level of the epiploic  
147 foramen (Pringle maneuver) depending on the location of insertion of the  
148 phrenicoabdominal vein on the CVC and the extent of the CVC thrombus. The plan for  
149 the CVC occlusion, venotomy and vein closure was summarized by the lead surgeon and  
150 confirmed with the surgical and anesthesia teams before starting the theatre clock for  
151 timing of the CVC occlusion. Renal vein tourniquets were tightened before CVC  
152 tourniquets, and caudal CVC were tightened before cranial CVC tourniquets. CVC  
153 venotomy was performed using a combination of a number 11 scalpel and Potts scissors  
154 around the insertion of the phrenicoabdominal vein and extended along the CVC as  
155 required to allow removal of the tumor thrombus. Some venotomy closures were  
156 performed under partial occlusion with a tangential clamp placed parallel to the incision  
157 and the Rummel tourniquets released, taking care that the edges of the vein within the  
158 clamp were matched correctly to each other and sufficiently wide to accept good bites of  
159 suture. Alternatively, some venotomies were sutured under complete CVC occlusion, in

160 which case the starting knot of the continuous suture pattern was pre-placed and tied  
161 prior to starting the CVC occlusion and performing the venotomy. Venotomies were  
162 closed under complete CVC occlusion if the venotomy was too large for the tangential  
163 clamp to be placed around it or if the location of the phrenicoabdominal vein insertion  
164 and subsequent venotomy precluded space for a clamp. A single or double simple  
165 continuous suture line with 4-0, 5-0 or 6-0 polypropylene was used for venotomy closure,  
166 with an absorbable hemostatic agent (Surgicel, Ethicon, Somerville, NJ) applied in some  
167 dogs at the discretion of the surgeon. Concurrent ureteronephrectomy was performed in  
168 some dogs during initial dissection of the adrenal tumor due to tumor invasion of the  
169 kidney (Figure 5) and/or renal vein or, at a later stage, due to irreparable damage to the  
170 renal vein during CVC venotomy.

171

#### 172 *Post-operative Care*

173 All dogs were monitored in the intensive care unit post-operatively until fully recovered  
174 from anesthesia and considered stable enough to be transferred to the surgical ward until  
175 discharge from the hospital. Post-operative analgesia was provided at the discretion of the  
176 anesthesiologist, based on pain scoring.<sup>8</sup> Dogs with a cortisol secreting tumor had their  
177 constant rate intravenous infusion of hydrocortisone reduced to 0.25 mg/kg/h at the end  
178 of surgery and continued for a further 24 hours. Oral prednisolone treatment was then  
179 initiated, with dosing gradually tapered over the following months based on progress at  
180 re-examination and subsequent ACTH stimulation tests. Dogs on pre-operative  
181 phenoxybenzamine did not continue with this medication post-operatively.

182 **Results**

183 *Signalment and Presentation*

184 Nineteen dogs met the inclusion criteria for the study; 10 were males (9 neutered), and 9  
185 were females (8 neutered). Median age was 11.3 years (range 6.7-14 years) and median  
186 bodyweight was 12.2 kg (range 5.7-41.3 kg). Thirteen breeds were represented and there  
187 were six crossbreeds. There were ten males (nine neutered) and nine females (eight  
188 neutered) dogs. Presenting clinical signs, complete blood count, biochemistry testing and  
189 urine analysis were largely non-specific and consistent with other reports of dogs  
190 presenting with functional adrenal tumors. Endocrine testing confirmed  
191 hyperadrenocorticism in three dogs (16%), was consistent with pheochromocytoma in 14  
192 dogs (74%), with a progesterone-secreting tumor in one dog (5%) and with a non-  
193 functional tumor in one dog (5%). Dogs with hyperadrenocorticism were treated with  
194 trilostane pre-operatively, with a median dose of 2 mg/kg (range 1.4-2.4 mg/kg) once  
195 daily. Twelve of 14 dogs with suspected pheochromocytoma were treated with  
196 phenoxybenzamine, with a median dose of 0.5 mg/kg (range 0.27-2.5 mg/kg) twice daily  
197 for between 4 and 21 days pre-operatively.

198

199 *Diagnostic Imaging*

200 Thoracic and abdominal CT was performed in all dogs, as per the inclusion criteria. The  
201 left adrenal gland (11 dogs, 58%) was more frequently affected than the right (eight dogs,  
202 42%). Median transverse diameter of adrenal neoplasms on CT was 22 mm (range 12-63  
203 mm). The contralateral adrenal gland was considered normal size in 68%, subjectively  
204 enlarged in 16% and subjectively small (compatible with atrophy) in 16% cases. On the

205 basis of CT, neoplasms were rounded (14/19) or lobular (5/19), all except one had a well-  
206 defined outline, 12 of 19 dogs had a regular border, 4 of 19 had an irregular border, and 3  
207 of 19 had signs of infiltration into the adjacent retroperitoneal fat. According to pre-  
208 contrast CT images, adrenal tumors appeared homogeneous (12/19, heterogeneous (1/19)  
209 or calcified (7/19). The median pre-contrast attenuation was 48 HU (range 39-67 HU)  
210 and median post-contrast attenuation was 102 HU (range 44-220 HU), with a median  
211 increase of 47 HU (range 10-162 HU) after contrast administration. Degree of contrast  
212 enhancement was classified as slight (<60 HU) in 13 of 19, moderate (60-110 HU) in 4 of  
213 19, and marked (>110 HU) in 2 of 19 dogs. After contrast administration, adrenal tumors  
214 appeared equally homogeneous (9/19) and heterogeneous (10/19).

215

216 Extension of tumor into the CVC and phrenicoabdominal vein was visible on the CT in  
217 all dogs, with left renal vein invasion identified in 16% (three dogs), all with  
218 pheochromocytomas. On the basis of the extent of the intraluminal filling defect in post-  
219 contrast images, the thrombus extended to the pre-hepatic (14 dogs, 74%), hepatic (3  
220 dogs, 16%) or post-hepatic (2 dogs, 11%) CVC, with a median length 15 mm (range 3-  
221 120 mm) cranial to the adrenal mass. In one dog the thrombus completely obstructed the  
222 CVC. There was evidence of tumor invasion into the adjacent retroperitoneum in one  
223 dog, and invasion into the diaphragm and epaxial muscles in one dog.

224

### 225 *Surgical Details*

226 Surgery was performed by four board-certified surgeons, with one surgeon performing  
227 nine procedures, one performing six procedures, and the remaining two surgeons each

228 performed two procedures. Median surgical time was 190 minutes (range 130-420  
229 minutes) and median anesthetic time was 265 mins (range 190-490 mins). Regional  
230 analgesia was provided with epidural morphine in 14 dogs and a transverse abdominis  
231 plane block using ropivacaine in two dogs. Methadone (0.1-0.3 mg/kg IV) was  
232 administered to all dogs perioperatively and 14 dogs also received a fentanyl or  
233 remifentanyl constant rate infusion intra-operatively. A single dose of heparin sodium  
234 solution for injection (50 I.U./kg [IV]) was administered to all dogs 5-10 minutes before  
235 starting the CVC venotomy.

236

237 Two Rummel tourniquets were used on the pre-hepatic CVC cranial and caudal to the  
238 thrombus (Figure 3) in 11 of 19 dogs (58%), four left sided and seven right sided tumors.  
239 Three Rummel tourniquets with an additional tourniquet on the left renal vein were used  
240 in one dog (5%) with a left adrenal tumor. Four Rummel tourniquets around the pre-  
241 hepatic CVC and both renal veins (Figure 4) were used in six dogs, (32%), all with left  
242 adrenal tumors. Six tourniquets were placed in one dog with a right adrenal tumor, with  
243 the additional Rummel tourniquets placed on the post-hepatic thoracic CVC and portal  
244 vein and hepatic artery together at the level of the epiploic foramen (Pringle maneuver).  
245 Overall median CVC occlusion time (n = 15) was 6.5 minutes (range 2 to 25 minutes).  
246 Median CVC occlusion time for venotomies sutured over a partial occlusion clamp (n =  
247 5) was 3.83 minutes (range 2 to 5.5 minutes). Median CVC occlusion time for  
248 venotomies sutured under full occlusion was 7.88 minutes (range 6 to 25 minutes). Four  
249 dogs had extended CVC occlusion times of 9.85, 10, 17 and 25 minutes. The extended  
250 occlusion time of 9.85 minutes in one dog result from blockage of the suction machine

251 and subsequent poor visibility during the venotomy. The occlusion times of 10, 17, and  
252 25 minutes in three other dogs resulted from the extensive nature or length of the tumor  
253 thrombus requiring additional time to remove the tumor thrombus and perform the  
254 venotomy.

255

256 CVC venotomy closure was performed under complete occlusion in 11 dogs (58%), five  
257 left sided and six right sided tumors. CVC venotomy closure was performed under  
258 partial occlusion with a tangential clamp in 8 of 19 dogs (42%), six left sided and two  
259 right sided tumors. Closure was performed with 4-0 (1 dog; 5%), 5-0 (14 dogs; 74%), or  
260 6-0 (4 dogs; 21%) polypropylene in a single (13 dogs; 68%) or double (6 dogs; 32%)  
261 simple continuous pattern. An absorbable hemostatic agent (Surgicel, Ethicon) was  
262 applied over the suture line in 12 dogs (63%).

263

264 Concurrent left ureteronephrectomy was performed in five dogs (26%) due to extension  
265 of the tumor thrombus into the left renal vein (one dog), tumor growth incorporating the  
266 left renal vein and kidney (two dogs) (Figure 5), and intra-operative damage to the left  
267 renal vein (two dogs). One dog with a right sided tumor required resection of a portion of  
268 the diaphragm to facilitate dissection of a large primary adrenal mass.

269

270 Histopathology was performed in 17 dogs, which confirmed pheochromocytomas (12  
271 dogs; 71%) and adrenocortical adenocarcinomas (5 dogs; 29%). Vascular invasion was  
272 evident on histopathology in all tumors, with one dog having direct invasion through the  
273 CVC wall as well as via extension from the phrenicoabdominal vein.

274

275 *Perioperative Complications and Mortality*

276 Intra-operative complications were observed in 14 of 19 dogs (74%), including  
277 hypotension (n=12), hypertension (n=2), arrhythmias (n=3) hemorrhage (n=6), break in  
278 asepsis (n=1), and temporary jejunal ischemia due to occlusion of the cranial mesenteric  
279 artery during dissection of large left sided tumors that enveloped this artery (n =2)  
280 (Figure 6). Packed red blood cell transfusions were performed in five dogs after intra-  
281 operative hemorrhage, and two dogs received fresh frozen plasma. One dog died intra-  
282 operatively at the end of surgery after excision of the tumor and thrombus; the adrenal  
283 tumor was large and highly adherent, requiring prolonged dissection. There were multiple  
284 periods of hypotension and ventricular arrhythmias, which progressed to ventricular  
285 fibrillation and cardiopulmonary arrest. Resuscitation was attempted but was  
286 unsuccessful.

287

288 Post-operative complications occurred in 13 of 18 dogs (68%) including refractory  
289 hypotension (n=2), acute kidney injury (n=2), and one each of: pulmonary  
290 thromboembolism, hemoperitoneum, aspiration pneumonia, hypovolemia, self-resolving  
291 peripheral edema, persistent hypertension, a single episode of abdominal pain, and  
292 anorexia with hypoglycemia. Refractory hypotension developed in one dog immediately  
293 post-operatively on recovery from anesthesia and in another a few hours post-operatively.  
294 Both cases progressed to cardiac arrest and resuscitation was unsuccessful. Pulmonary  
295 thromboembolism was confirmed on post-mortem examination in one dog following  
296 respiratory arrest four days post-operatively. Repeat exploratory laparotomy was

297 performed in the dog with hemoperitoneum, in which a retroperitoneal hematoma was  
298 found near the site of ureteronephrectomy, but no specific source of hemorrhage could be  
299 identified (the renal vessel pedicles and CVC venotomy sites were not bleeding).

300 Autotransfusion was performed and the dog recovered with no further complications.

301

302 Median time to discharge was four days (range 3-11 days), and median time in the  
303 intensive care unit was two days (range 1-5 days). The 4 dogs with prolonged CVC  
304 occlusion times all survived to discharge. Overall perioperative mortality rate was 21%  
305 (four dogs). These dogs all had pheochromocytomas, with a median tumor size 28 mm  
306 (range 20-63 mm). The CVC thrombi were all pre-hepatic in these four dogs, extending  
307 3-13 mm cranial to the adrenal mass. No dogs were euthanized intra-operatively due to  
308 the technical difficulties or the tumor being considered inoperable.



309 **Discussion**

310 This report describes variations in surgical technique in dogs undergoing adrenalectomy  
311 with CVC venotomy for treatment of adrenal neoplasia, including the duration of  
312 temporary CVC occlusion tolerated. CVC occlusion for up to eight minutes has been  
313 reported to be safe in healthy experimental dogs,<sup>9</sup> but there is no information regarding  
314 CVC occlusion times in dogs with adrenal tumors. Most dogs in this study had a CVC  
315 occlusion time less than eight minutes, but four dogs had longer occlusion times of 9.85,  
316 10, 17 and 25 minutes. These dogs all survived to discharge, suggesting that longer  
317 occlusion may be tolerated in selected patients, without adverse effects, presumably  
318 because in many cases gradual occlusion of the CVC to a significant extent by the tumor  
319 prior to surgery affords a degree of tolerance to full temporary occlusion during surgery.  
320 Further investigation is needed to determine safe or optimal CVC occlusion times in  
321 clinical patients and to improve our understanding of the factors involved.

322

323 Left (11/19) adrenal tumors occurred more frequently than right (42%) in this study,  
324 similar to one other report,<sup>5</sup> but not others.<sup>2,3,6,10</sup> A difference for surgeons to note when  
325 operating on left sided adrenal tumors, which is likely performed by others but has not  
326 been reported before, is the need to move the dissected out left adrenal tumor over to the  
327 right side of the abdomen prior to CVC venotomy to optimize exposure for this part of  
328 the procedure (Figure 4). The use of more than two Rummel tourniquets for vascular  
329 occlusion in dogs undergoing CVC venotomy for removal of adrenal tumors has also not  
330 been reported before, although it may seem an obvious possibility (Figure 4). The more  
331 distal insertion of the left phrenicoabdominal in close proximity to the left renal vein

332 insertion on the CVC (Figure 2) and the presence of tumor means that the caudal CVC  
333 tourniquet often has to be placed distal to the left renal vein insertion, therefore also  
334 requiring right and left renal vein tourniquets to create a blood-free field during the CVC  
335 venotomy for left-sided tumors. In contrast the more cranial right phrenicoabdominal  
336 vein insertion (Figure 2) means that two CVC tourniquets cranial and caudal to the tumor  
337 thrombus in the CVC will usually suffice for right-sided tumors (Figure 3). One dog with  
338 a post-hepatic CVC thrombus required extension of the surgical approach to include a  
339 median sternotomy and six vascular tourniquets to additionally isolate the thoracic post-  
340 hepatic CVC and hepatic inflow (portal vein and hepatic artery).

341

342 Previous studies report closure of the CVC venotomy using a partial occlusion clamp,<sup>1,2,4</sup>  
343 whereas in others the CVC venotomy and closure was performed under full occlusion,<sup>5,6</sup>  
344 although the reason for selection of either technique is not clear. In this study both  
345 methods of CVC venotomy closure were used, with the venotomy being sutured under  
346 full occlusion if the venotomy was too large to accommodate a tangential clamp or if the  
347 positioning of the clamp was impractical. For right-sided tumors, the cranial insertion of  
348 the right phrenicoabdominal vein and subsequent proximity of the venotomy to the  
349 hepatic hilus (Figure 2) precluded easy clamp placement in some cases. Despite pre-  
350 placement (prior to venotomy) of the starting knot, performing the venotomy and vein  
351 closure under full CVC occlusion resulted in a longer median CVC occlusion time  
352 compared to using a partial occlusion clamp although this method appeared to be equally  
353 well tolerated.

354

355 Use of various suture sizes (4-0 to 5-0), material (silk, polypropylene, polydioxanone)  
356 and patterns (simple continuous, cruciate continuous) have been reported in the literature  
357 for performing the CVC venotomy closure.<sup>1,2,4-6</sup> This study did not differ much in this  
358 respect, although the suture line was oversewn with a second simple continuous suture  
359 pattern (6/19 dogs) if felt necessary at the discretion of the surgeon.

360

361 Authors of one study found a significantly higher risk of perioperative mortality if  
362 concurrent ureteronephrectomy was required as it indicated a larger, more invasive  
363 tumor,<sup>7</sup> although ureteronephrectomy has not been identified as a risk factor in other  
364 studies.<sup>3</sup> In this study ureteronephrectomy was performed in 5/19 dogs (26%) because of  
365 neoplastic invasion of the renal vein/kidney (Figure 5) or intra-operative damage to the  
366 left renal vein because of close proximity of the tumor. Knowledge that  
367 ureteronephrectomy was only performed with left-sided tumors in this study is useful for  
368 preoperative surgical planning and discussion with owners. Among the four dogs that  
369 died in the peri-operative period, one dog had a ureteronephrectomy performed and it is  
370 not possible from our limited data to evaluate if ureteronephrectomy is a risk factor for  
371 mortality in dogs undergoing adrenalectomy.

372

373 Information in the literature on the presentation and treatment of the most extensive  
374 adrenal tumor CVC thrombi is very limited. One study reported the extent of adrenal  
375 tumor CVC thrombus as a risk factor for perioperative mortality, with an overall  
376 mortality rate of 72% for 14 dogs undergoing CVC venotomy and 100% mortality for the  
377 seven dogs with a CVC thrombus extending beyond the hepatic hilus.<sup>3</sup> This contrasts

378 with the results of this study where all five dogs with a thrombus extending to the hepatic  
379 or post-hepatic CVC survived to discharge. The overall 21% (4/19 dogs) mortality rate in  
380 this study is similar to other studies involving venotomy,<sup>1,2,11</sup> and all four dogs that died  
381 had pre-hepatic tumor thrombi. Successful outcomes for a number of dogs in this study  
382 were dependent on the availability of blood products, and all were dependent on  
383 receiving specialist anesthesia and critical care. The results of this study overall supports  
384 attempting surgical resection of many different types of invasive adrenal tumors,  
385 especially given the excellent long-term outcome expected from the published literature  
386 if the peri-operative period is survived.<sup>1-7</sup> However, owners should be made fully aware  
387 of the risks and complications.

388

389 The intra-operative (14/19 dogs, 74%) and post-operative (13/18 dogs, 72%)  
390 complication rates in this study were high, which is similar to other studies.<sup>1-7,10</sup> The  
391 types of complications reported are also similar, including surgical hemorrhage,  
392 anesthetic complications, pancreatitis, azotemia/renal failure and thromboembolic  
393 complications.<sup>1-7</sup> Very limited information is available regarding anticoagulation  
394 strategies for the prevention or treatment of thromboembolic disease in canine patients  
395 undergoing adrenalectomy with venotomy, despite pheochromocytoma, venotomy and  
396 blood transfusion all being reported as factors that increase the risk of disseminated  
397 intravascular coagulation in dogs undergoing adrenalectomy.<sup>3</sup> In contrast to the single  
398 pre-venotomy heparin dose given in this study, one study reports the administration of  
399 heparin in plasma during surgery with continued heparin doses tapering over several  
400 days,<sup>2</sup> but there are no studies reporting decreased incidence of thromboembolism with

401 any anticoagulation protocol. Application of a topical anticoagulation solution (ice-cold  
402 lidocaine, heparin and saline) to thoroughly flush a venotomy site prior to closure is  
403 recommended in one surgical textbook.<sup>12</sup> One uncommon complication seen in this study  
404 was temporary jejunal ischemia due to occlusion of the cranial mesenteric artery in two  
405 dogs during dissection of large left sided tumors that enveloped this artery. The ligature  
406 was removed in both cases reversing the problem but necessitating a longer dissection to  
407 preserve this artery. This problem was anticipated prior to surgery as the cranial  
408 mesenteric artery was seen to be enveloped by the left sided adrenal tumor on computed  
409 tomography (Figure 6) . Discoloration of the small intestine during adrenal tumor  
410 dissection without the cause identified has been mentioned in two other studies, one as a  
411 temporary event where the dog recovered<sup>11</sup> and one in which fatal permanent jejunal  
412 necrosis was described.<sup>10</sup>

413

414 This study had substantial limitations. Because of the retrospective nature, the sample  
415 size, completeness and type of data collected could not be controlled, and there was a  
416 smaller population of dogs with CVC thrombi extending beyond the hepatic hilus  
417 compared to those within the pre-hepatic CVC. The surgeries in this study, although from  
418 one institution, were non-standardized and performed by multiple board-certified  
419 surgeons and anesthesiologists. Multi-institutional prospective studies with predefined  
420 surgical, anesthesia, endocrine, and anticoagulation protocols would substantially  
421 enhance the power and quality of the data that could be captured regarding surgical  
422 treatment of adrenal tumors with CVC invasion in dogs.

423

424 In conclusion, CVC occlusion times up to eight minutes appear to be well tolerated in  
425 clinical cases of dogs undergoing adrenalectomy with CVC venotomy, similar to that  
426 reported in experimental healthy dogs, and additionally longer CVC occlusion times may  
427 also be well tolerated in some clinical cases. In contrast to other reports, dogs with CVC  
428 tumor thrombi extending beyond the hepatic hilus can survive the perioperative period.  
429 The variation in presentation of adrenal tumor thrombi and the details of surgical  
430 techniques used to treat them in this study, particularly the differences between right and  
431 left sides, provides useful additional information for surgeons planning and operating on  
432 these types of cases. Pre-operative planning is particularly important to minimize surgery  
433 time in these types of cases that are at risk of unstable anesthetics and may need a long or  
434 difficult dissection to remove the adrenal tumor, although the venotomy aspect of the  
435 procedure is very controlled and always relatively short in relation to the rest of the  
436 surgery.

437

#### 438 **Disclosure Statement**

439 The authors declare no conflict of interest related to this report.

440 **References**

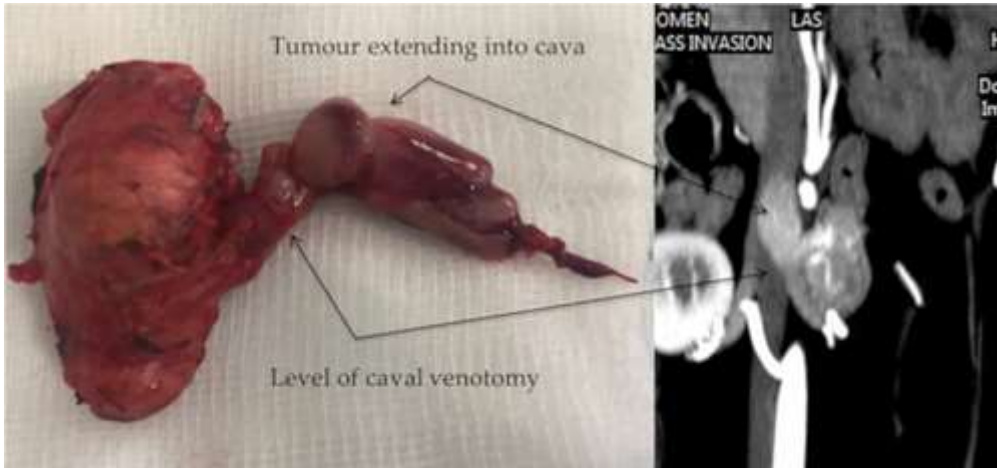
- 441 1. Gilson SD, Withrow SJ, Orton EC. Surgical treatment of pheochromocytoma:  
442 technique, complications, and results in six dogs. *Vet Surg.* 1994;23(3):195-200.
- 443 2. Kyles AE, Feldman EC, Cock HEV De, et al. Surgical management of adrenal  
444 gland tumors with and without associated tumor thrombi in dogs: 40 cases (1994–  
445 2001). *J Am Vet Med Assoc.* 2003;223(5):654-662.
- 446 3. Barrera JS, Bernard F, Ehrhart EJ, Withrow SJ, Monnet E. Evaluation of risk  
447 factors for outcome associated with adrenal gland tumors with or without invasion  
448 of the caudal vena cava and treated via adrenalectomy in dogs: 86 cases (1993-  
449 2009). *J Am Vet Med Assoc.* 2013;242(12):1715-1721.
- 450 4. Herrera MA, Mehl ML, Kass PH, Pascoe PJ, Feldman EC, Nelson RW.  
451 Predictive factors and the effect of phenoxybenzamine on outcome in dogs  
452 undergoing adrenalectomy for pheochromocytoma. *J Vet Intern Med.*  
453 2008;22(6):1333-1339.
- 454 5. Lang JM, Schertel E, Kennedy S, Wilson D, Barnhart M, Danielson B. Elective  
455 and Emergency Surgical Management of Adrenal Gland Tumors: 60 Cases  
456 (1999–2006). *J Am Anim Hosp Assoc.* 2011;47(6):428-435.
- 457 6. Massari F, Nicoli S, Romanelli G, Buracco P, Zini E. Adrenalectomy in dogs with  
458 adrenal gland tumors: 52 cases (2002-2008). *J Am Vet Med Assoc.*  
459 2011;239(2):216-221.
- 460 7. Schwartz P, Kovak JR, Koprowski A, Ludwig LL, Monette S, Bergman PJ.  
461 Evaluation of prognostic factors in the surgical treatment of adrenal gland tumors  
462 in dogs: 41 cases (1999–2005). *J Am Vet Med Assoc.* 2008;232(1):77-84.

- 463 8. Reid J, Nolan AM, Hughes J, Lascelles D, Pawson P, Scott EM. Development of  
464 the short-form Glasgow Composite Measure Pain Scale (CMPS-SF) and  
465 derivation of an analgesic intervention score. *Anim Welf.* 2007;16:97-104.
- 466 9. Hunt GB, Malik R, Bellenger CR, Pearson MRB. A new technique for surgery of  
467 the caudal vena cava in dogs using partial venous inflow occlusion. *Res Vet Sci.*  
468 1992;52(3):378-381.
- 469 10. Anderson C, Birchard S, Powers B, Belandria G, Kuntz C, Withrow S. Surgical  
470 treatment of adrenocortical tumors: 21 cases (1990-1996). *J Am Anim Hosp Assoc*  
471 2001;37:93-97.
- 472 11. Mayhew PD, Culp WTN, Balsa IM, Zwingenberger AL. Phrenicoabdominal  
473 venotomy for tumor thrombectomy in dogs with adrenal neoplasia and suspected  
474 vena caval invasion. *Vet Surg.* 2018;47(2):227-235.
- 475 12. Phillips H, and Aronson L. Vascular Surgery. In Tobias KM, Johnston SA, eds:  
476 *Veterinary Surgery Small Animal.* St. Louis, MO: Elsevier Saunders; 2018:2093-  
477 2108.



478 **Figure Legends**

479 Fig 1. Adrenal tumors typically extend down phrenicoabdominal (PA) vein and into  
480 caudal vena cava but do not adhere to the walls of the cava itself.

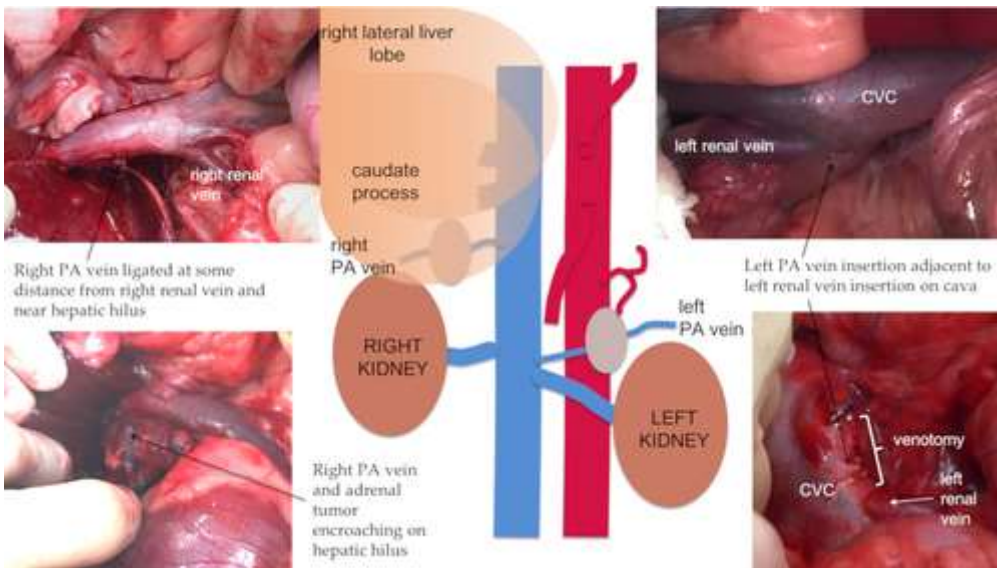


481

482

483

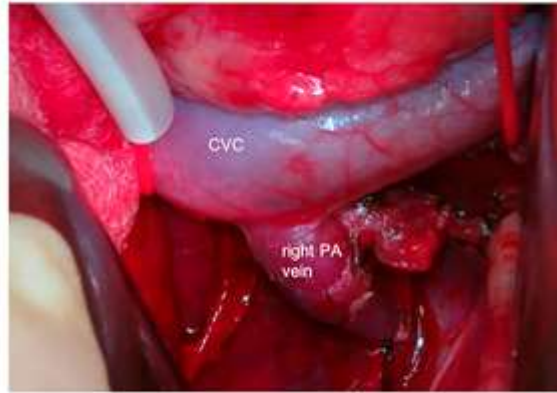
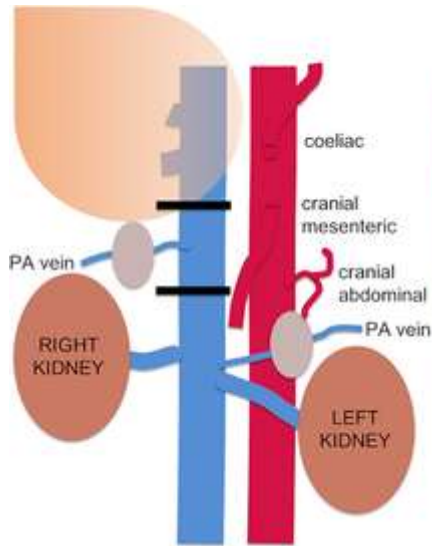
484 Fig 2. Illustrations show the more distal insertion of the left phrenicoabdominal (PA) vein  
485 adjacent to the insertion of the left renal vein on the caudal vena cava (CVC) and the  
486 proximity of the right PA vein to the hepatic hilus.



487

488

489 Fig 3. Right sided adrenal tumors with caval extension usually only need 2 tourniquets to  
490 isolate them. The right adrenal tumor has been dissected out until it only remains attached  
491 by the right phrenicoabdominal (PA) vein insertion on the caudal vena cava (CVC).

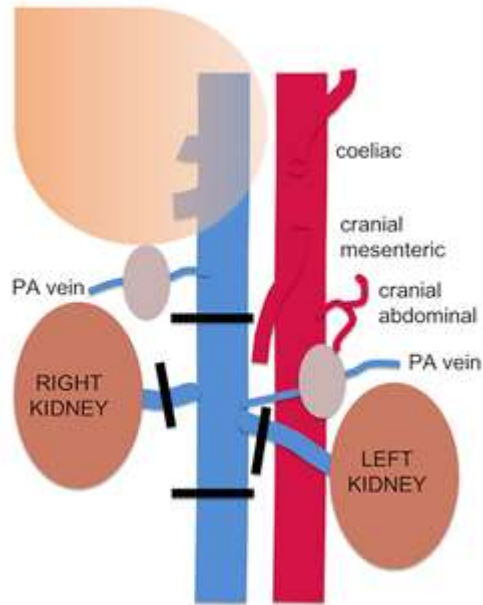
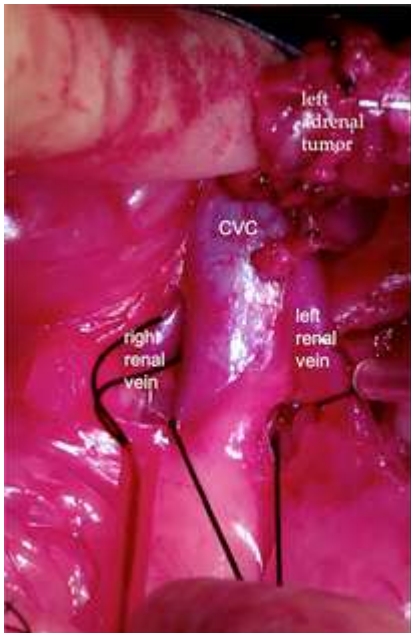


492

493

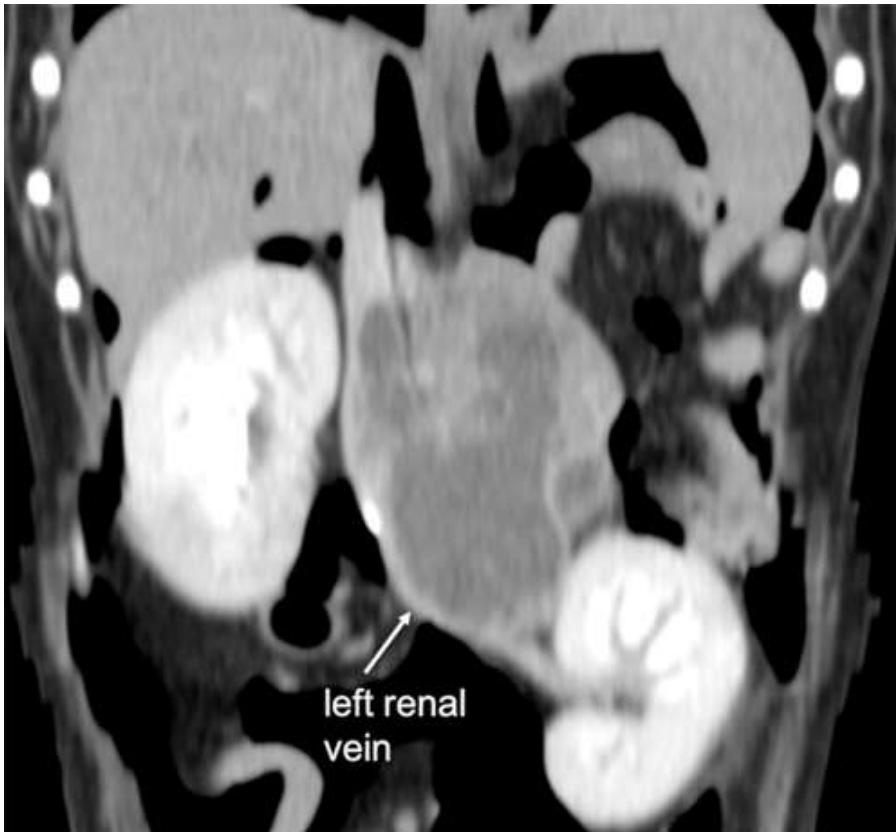494

495 Fig 4. Left sided adrenal tumors with caval extension usually require 3 to 4 tourniquets to  
496 isolate them. After dissection of the left adrenal tumor it is passed underneath the  
497 mesentery so as to be on the same side as the caudal vena cava (CVC) to facilitate final  
498 exposure for the venotomy.



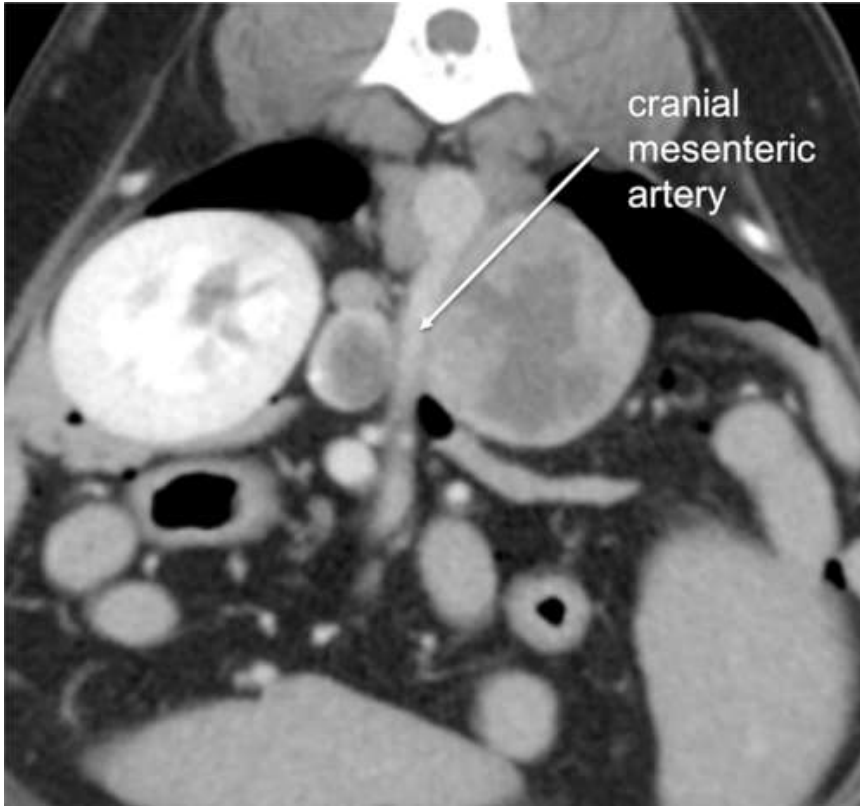
499  
500  
501

502 Fig 5. Left adrenal tumor compressing/invading left renal vein. A left reteronephrectomy  
503 was planned from the outset in this case.



504  
505

506 Fig 6. Left adrenal tumor enveloping cranial mesenteric artery.



507