

This author's accepted manuscript may be used for non-commercial purposes in accordance with [Wiley Terms and Conditions for Self-Archiving](#).

The full details of the published version of the article are as follows:

TITLE: Surgical management of chronic otitis secondary to craniomandibular osteopathy in three West Highland white terriers

AUTHORS: L. Beever, F. Swinbourne, S. L. Priestnall, G. Ter Haar, D. J. Brockman

JOURNAL: Journal of Small Animal Practice

PUBLISHER: Wiley

PUBLICATION DATE: 16 April 2018 (online)

DOI: <https://doi.org/10.1111/jsap.12839>

**Surgical management of chronic otitis secondary to Craniomandibular Osteopathy in three
West Highland White Terriers**

L. Beever¹, F. Swinbourne², S. L. Priestnall³, G. Ter Haar¹, D. J. Brockman¹

¹Department of Clinical Sciences and Services, The Royal Veterinary College, Hertfordshire AL9 7TA

² Willows Referral Service, Highlands Road, Shirley, Solihull, West Midlands B90 4NH

³Department of Pathobiology and Population Sciences, The Royal Veterinary College, Hertfordshire
AL9 7TA

Authors

Lee Beever BVetMed (Hons) MRCVS

Faye Swinbourne BVM&S MVetMed DipECVS MRCVS

Simon Priestnall BSc (Hons) BVSc PhD PGC(VetEd) FHEA DipACVP FRCPath MRCVS

Gert Ter Haar DVM PhD DipECVS MRCVS

Daniel Brockman BVSc DipACVS DipECVS FHEA MRCVS

Tagline:

Atypical manifestation of Craniomandibular Osteopathy

Conflict of interest

No authors of this article have a financial or personal relationship with other individuals or
organisations which could inappropriately influence or bias the content of this paper.

Acknowledgements

We would like to acknowledge all the staff and students within the Department of Clinical Sciences
and Services at the Royal Veterinary College who were involved in the care of these animals.

Correspondence to

Professor Daniel Brockman BVSc CertVR CertSAO DipACVS DipECVS

Professor of Small Animal Surgery and Head of CSS

31 The Royal Veterinary College
32 Queen Mother Hospital for Animals
33 Hawkshead Lane, North Mymms
34 Hatfield, Hertfordshire AL9 7TA
35 United Kingdom
36 Phone: +44 707 666 366
37 E-mail: dbrockman@rvc.ac.uk

38

39 **Abbreviations**

- 40 • CMO- Craniomandibular Osteopathy
- 41 • WHWT- West Highland White Terrier
- 42 • CT- Computed tomography
- 43 • TECA- Total ear canal ablation
- 44 • LBO- Lateral bulla osteotomy
- 45 • TMJ- Temporomandibular joint

46

47

48

49

50

51

52

53

54

55

56

57

58

59

60

Surgical management of chronic otitis secondary to Craniomandibular Osteopathy in three West Highland White Terriers

Word count: 3110

Three West Highland White Terriers were presented for further investigation of left-sided para-aural abscessation. Computed Tomography revealed chronic otitis media with extensive osseous proliferation surrounding the horizontal and vertical ear canals contiguous with the expanded temporal bone, consistent with a unilateral variant of Craniomandibular Osteopathy (CMO). A left total ear canal ablation with lateral bulla osteotomy was performed in all dogs. An ultrasonic bone curette (Sonopet; Stryker) proved useful when removing the osseous proliferation in two dogs. Histopathological examination of the ear canals was consistent with CMO and the treatment led to resolution of the presenting clinical signs in all dogs. To the authors' knowledge, this is the first report of CMO engulfing the external ear canal presumably leading to chronic otitis media and para-aural abscess formation in the dog. This is also the first reported use of an ultrasonic bone curette in canine otic surgery.

Keywords

Craniomandibular Osteopathy, Otitis, Surgery, TECA, ultrasonic curette

Introduction

Craniomandibular Osteopathy (CMO) is a non-neoplastic and typically bilateral, osteoproliferative disease that commonly affects the mandible, occipital bones and tympanic bullae (Pool and Leighton 1969, Riser and others 1967, Schulz 1978). Concurrent involvement of other skull and long bone metaphyses is occasionally reported (Dennis and others 1993, Franch and others 1998, Pettitt and others 2012, Ratterree and others 2011, Riser and others 1967, Thompson and others 2011, Watson and others 1995). West Highland White Terriers (WHWT), Scottish Terriers and Cairn Terriers are at an increased risk of developing CMO (LaFond and others 2002, Munjar and others 1998), although numerous other breeds have been reported sporadically (Burk and Broadhurst 1976, Franch and others 1998, Hathcock 1982, Huchkowsky 2002, Matiasovic and others 2015, Munjar and others 1998, Ratterree and others 2011, Schulz 1978, Taylor and others 1995, Thompson and others 2011, Watkins and Bradley 1966, Watson and others 1975). Affected dogs are typically presented at 3-9 months of age because of a painful jaw swelling, episodic pyrexia, lethargy, and inappetance (Dennis and others 1993, Riser and others 1967).

The pathogenesis of CMO is unknown although a recessive autosomal inheritance has been demonstrated in the WHWT (Padgett and others 1986). An inciting infectious or inflammatory element has also been postulated (Riser and others 1967, Trowald-Wigh and others 2000, Watson and others 1995). Diagnosis of CMO is based on characteristic diagnostic imaging and histopathological changes (Riser and others 1967, Schulz 1978). Treatment is generally supportive until skeletal maturity when the clinical signs become self-limiting.

This manuscript describes the clinical, computed tomographic (CT), surgical and histopathological findings in three dogs that were successfully treated for chronic otitis media and para-aural abscessation that was presumed to be a long term complication of unilateral CMO.

Case Histories

Three WHWTs (one female neutered and two male entire) were presented for evaluation of left sided para-aural abscessation and long standing otitis externa that had failed to respond to antimicrobial therapy and surgical drainage. Case details are summarised in **Table 1**. Median age at the time of surgery was 3 years 8 months (3y4m - 10y2m). Median patient weight was 8.2 (7.95 - 13.0) kg. Clinical signs varied between dogs and included discharging sinus formation (n=3), chronic difficulty opening mouth (n=1), recurrent otitis (n=1) and chronic facial swelling (n=1). Median time from para-aural abscess development to referral was 1 month (3wks- 4months). No dog had any reported dysphagia, laryngeal dysfunction or any previous clinical signs associated with their CMO.

Physical examination revealed a purulent discharging sinus caudoventral to the lateral canthus of the left eye (**Fig 1**) in two dogs and a non-discharging surgical wound (from a previous surgical drainage) in one dog. All dogs had marked palpable firm thickening of the left external ear canal and tympanic bullae extending rostrally to the lateral canthus of the eye and ventrally to the mandible. There was also marked reduction in the palpable mobility of the pinna of two dogs. In the dog with no discharging sinus a 1.5cm diameter soft tissue swelling was palpable overlying the hard swelling at the base of the left ear. The right ear and ear canals were considered normal in all three dogs. Mouth opening was subjectively reduced (to 75% of normal) in two dogs but considered normal in one. A pain response was not elicited either during attempts to open the mouth or during palpation of the abnormal swellings. Facial nerve function was assessed by neurological examination in all dogs with no visible muscular asymmetry, intact facial muscle movement, intact voluntary blink and palpebral reflexes in all three dogs. Only dog three had any other skin lesions that weren't associated with the ear, including hyperpigmentation of the ventrum and interdigital erythema.

Computed tomography revealed extensive, proliferative, compact, irregular new bone formation contiguous with the tympanic bulla in all dogs. The large densely ossified new bone extended laterally, along the soft tissues of the horizontal and vertical ear canals and the tympanic cavities were incompletely filled with new bone and non-contrast enhancing soft tissue, in each dog (**Fig 2**). Bony mandibular thickening that impinged on the temporomandibular joint was visible in both dogs with reduced mouth opening. The new bone formation in these two dogs also involved the bones of the

hyoid apparatus on the left side. Soft tissue attenuating tracts extending from the ventrolateral aspect of this new bone, joining the external ear canal with the skin, were visible in all dogs. Otoscopic examination of the affected ear canals revealed marked stenosis with a chronically inflamed, moderately hyperplastic lining integument and a cerumino-purulent discharge in all dogs.

A left total ear canal ablation (TECA) with lateral bulla osteotomy (LBO) was performed in all dogs as previously described (White and Pomeroy 1990), modified to manage the extensive osseous proliferation and according to individual surgeon preference regarding incision orientation. In brief, a lateral approach to the ear canal was made to expose the ossified external ear canal (**Fig 3A**). In two dogs an ultrasonic bone curette (Sonopet; Stryker) was used to excise the ossified ear canal at the level of the distal horizontal canal (**Fig 3B**). The ultrasonic bone curette was then used to debulk the osseous proliferation allowing identification of the external acoustic meatus permitting access to the tympanic bullae (**Fig 3 C**). In dog 2 an osteotome was used to penetrate the abnormal bone. Curettage of the tympanic cavity epithelial lining and thorough flushing was performed in all dogs. A penrose drain was placed in two dogs and closure was routine in all.

Surgical findings were consistent with chronic otitis media with para-aural abscess formation in all dogs. The resected tissues had the gross appearance of auricular cartilage encased in dense woven bone. The facial nerve was not identified during the procedure in any dog. On recovery from anaesthesia the left palpebral reflex was absent in 1 dog and markedly reduced in two (**Table 1**). Postoperative analgesia and antimicrobial therapy were administered as detailed in **Table 1**. Median time to discharge from the hospital postoperatively was 4 (3-4) days. Bacterial culture of the tympanic cavity was submitted in two dogs yielding no bacterial growth after 48 hours aerobic and anaerobic incubation in one and growth of Coagulase-negative *Staphylococcus* sensitive to all antimicrobials tested in the other.

Histopathological examination of the excised portion of ear canal and associated osseous proliferation was performed in all dogs, this revealed a thick layer of relatively immature but well-differentiated woven bone blending imperceptibly with the perichondrium of the auricular cartilage. In all dogs, the cartilage itself was unremarkable. The thick trabeculae of bone contained a high density of osteocytes within lacunae and prominent basophilic cement lines with either a smooth contour (resting lines) or a

scalloped edge (reversal lines). The histopathological appearance was consistent with Craniomandibular Osteopathy (**Fig 4**). In all dogs, the lining of the ear canal contained marked ceruminous and sebaceous gland hyperplasia with variable neutrophilic to mononuclear inflammation consistent with chronic otitis externa.

In addition to facial neuropathy, postoperative complications were seen in two dogs. Dog 1 was re-presented 7 days postoperatively with a purulent discharge from the surgical site. Repeat CT revealed changes consistent with abscess or seroma formation. All skin sutures were removed and the wound was opened to allow second intention healing. Wound bacterial culture yielded a moderate growth of *E.coli*. The dog was discharged after 5 days with antibiotics and non-steroidal ant-inflammatory drugs according to culture/ sensitivity results (**Table 1**). Examination of Dog 3 by the referring veterinarian 14 days postoperatively, revealed a serosanguinous discharge from the surgical wound and cefalexin was continued for a further 2 weeks based on intraoperative culture/ sensitivity results. Owners were contacted by telephone at a median of 20 (6 -24) weeks after surgery. The palpebral reflex and blink had returned in all dogs by the fourth postoperative week and there had been no recurrence of clinical signs in any dog. No dog's dogs had any reported difficulty opening their mouths or eating.

Discussion

This manuscript describes three dogs with unusual bone formation that engulfed the left ear canal and tympanic bulla. The dogs all had mild to moderate otitis externa, advanced otitis media and para aural abscess formation. The histological appearance of the ear canals, with organized immature bone outside histologically normal auricular cartilage, indicates that these dogs had “atypical” unilateral CMO that surrounded the external ear canal and middle ear causing or exacerbating otitis media and secondary para-aural abscessation. To the author’s knowledge, the dogs reported here are the first to be reported with this condition.

Mortality secondary to CMO is uncommon and the disease is often self-limiting by 11-13 months when bone growth slows. Extensive new bone formation around the TMJ can cause ankylosis preventing prehension of food leading to euthanasia (Dennis and others 1993, Riser and others 1967). Although the majority of clinical reports identify bilateral involvement of the affected bones in CMO, unilateral mandibular involvement has been previously described (Watson and others 1995). The aetiopathogenesis of CMO remains poorly understood and it is likely to be multifactorial (Riser and others 1967, Watson and others 1975). In a case series of 12 Irish setters with canine leukocyte adhesion deficiency 7 dogs developed radiographic signs consistent with CMO, supporting an underlying infectious cause for these changes (Trowald-Wigh and others 2000). The presence of inflammatory infiltrates also supports a possible infectious cause but this has not been proven (Riser and others 1967, Thompson 2007). Implicated agents include viral (canine distemper virus) and bacterial infection (E.coli) (Watson and others 1995). The occurrence of CMO in a diverse range of breeds other than WHWTs also suggests that either there is an enhanced inherited susceptibility to a causative agent or there are multiple causes of the disease (Thompson 2007, Watson and others 1975).

A clinical diagnosis of CMO is based on physical examination findings and pathognomonic diagnostic imaging. A definitive diagnosis however, requires histopathological examination of affected bone (Riser and others 1967, Schulz 1978). The radiographic features of CMO include bilateral enlargement of the affected bones with homogeneous, symmetrical broad based periosteal and

subperiosteal new bone formation (Riser and others 1967, Thompson and others 2011). The bony enlargements are dense osseous proliferation's which project laterally, medially and ventrally from the affected bones as seen on radiographs or CT (Hudson and others 1994, Riser and others 1967). The characteristic histopathological features of CMO include osteoclastic resorption of existing lamellar bone, such as the mandible, and replacement by primitive coarse woven bone that extends beyond the normal periosteal boundaries into the surrounding connective tissue. The formation of new trabecular bone with a 'mosaic' pattern of irregular cement lines indicates the sporadic and rapid deposit and resorption of normal bone (Riser and others 1967, Thompson and others 2011). In our dogs, the new bone formation occurred unilaterally around the auricular cartilage with the same 'mosaic' pattern observed with CMO and thus likely represents an extension of new bone formation from the tympanic bulla. In contrast to these findings, the histopathological changes associated with chronic inflammatory otitis are characterised by progressive proliferative changes in the dermis and epidermis lining the external ear canal (Angus and others 2002, Fraser 1961, van der Gaag 1986). Eventually permanent fibrosis and calcification of chronically affected tissue develops (FERNANDO 1967, Harvey and others 2001). Ossification of chronically affected tissue then develops which can extend into the cartilage (Harvey and others 2001, van der Gaag 1986). Osseous metaplasia of the soft tissue around the ear canal is also a common finding in chronic otitis with 60% of Cocker Spaniels in one study of microscopic changes found in otitis having osseous metaplasia (Angus and others 2002). Because the extensive unilateral osseous proliferation seen in our dogs was histologically immature but well-differentiated woven bone that was radiographically contiguous with the tympanic bulla we concluded that this is consistent with CMO affecting the ear canal rather than primary otitis externa and media leading to osseous metaplasia.

Repeat imaging of dogs with CMO is rarely performed in the long term if the clinical signs resolve. In one case report (Hudson and others 1994) repeat CT scans at two months and then one year after diagnosis of CMO, showed ongoing resolution of the proliferative new bone associated with the mandible in one WHWT, however the bone of the tympanic bullae remained sclerotic and markedly thickened. It is likely therefore, that chronic changes to the bullae were present in all the dogs reported here, before the development of clinical otitis externa, media and para-aural abscessation. Whether or not the CMO was actually the cause of the chronic otitis media, or simply exacerbated it,

remains unknown. It is, therefore our presumption that the extensive osseous proliferation associated with juvenile CMO may have led to narrowing of the external ear canal and poor ear canal and middle ear drainage, as it progressed to engulf the external ear canal and tympanic bulla. This process led to worsening otitis externa and media and progression to para-aural abscess formation. Importantly, the right ear was unremarkable on examination in all dogs with no bony changes associated with the tympanic bullae or ear canals. It is also possible that the chronic inflammation in the petrous temporal bone may have exacerbated the bone formation around the bulla but because we did not perform histopathological examination of this bone we do not know whether there was an additional inflammatory component or not. These dogs are likely to have been affected by unilateral mandibular CMO as a juvenile and this predisposed to excessive osseous proliferation in response to otitis later in life on the affected side.

Surgical intervention is rarely indicated in CMO although rostral hemimandibulectomy has been described as a salvage procedure (Watson and others 1995). Para-aural abscessation secondary to otitis externa/media is a major indication for TECA-LBO (White and Pomeroy 1990). The surgery was performed in all three dogs with the aim of resolving the severe secondary otitis media leading to para-aural abscess formation. Surgical planning was aided by the CT images including three dimensional reconstruction. The bone associated with the medial aspect of the horizontal ear canal was left in situ in all three dogs following access to the tympanic bullae due to the high risk of iatrogenic damage to neurovascular structures in this region and the questionable gain in removing this (**Figure 5**). An ultrasonic bone curette was used in two dogs with the aim of limiting damage to the facial nerve at the surgical site whilst achieving controlled removal of the ear canal lining and bone. Ultrasonic surgical instruments were initially developed in the field of human dentistry and later in human and veterinary fields for soft tissue dissection and neurosurgery (Axlund and others 2005, Forterre and others 2011, Tobias and others 1996). The longitudinal and torsional motion of more recently developed tips allows for fine bone dissection whilst preserving surrounding soft tissues. Ultrasonic bone curette use has been described for human skull surgery with the aim of preventing trauma to neurovascular structures including the facial nerve when compared to traditional high-speed drills (Garzino-Demo and others 2011, Hadeishi and others 2003, Samy and others 2007). Ultrasonic curette use has also been reported in human auditory canal surgery to reduce heat and vibration

caused by a burr which may damage the labyrinthine organ (Hadeishi and others 2003). This was especially important in these dogs with gross distortion of the normal anatomy. The ultrasonic curette allowed accurate, controlled and rapid excision of the dense bone while limiting secondary soft tissue damage and greatly improving visualisation with the ongoing irrigation and suction provided by the hand piece.

Post-operative complications were seen in all the dogs reported here. Facial nerve deficits are a known complication of TECA surgery and have been reported to occur in up to 49% of cases (Spivack and others 2013). All three dogs suffered transient postoperative facial nerve deficits, this neuropraxia is likely secondary to the surgery where the nerve was stretched or traumatised by the use of the ultrasonic curette, osteotome or hand held retractors. Because of the speed of recovery (within four weeks), surgical retraction is more likely to have been the cause of this neuropraxia. The development of an infected fluid-filled pocket at the surgical site of dog 1 and ongoing serous discharge in dog 3 suggests that either the substantial dead space created by surgical excision of the ear canal was not well controlled by passive drainage and sutures, or that the wounds were particularly effusive as a result of a high bacterial burden or ultrasonic curette use. The use of passive drains has been reported extensively following TECA surgery without complication (Spivack and others 2013, White and Pomeroy 1990), however the intraoperative placement of drains in routine TECA-LBO has not produced superior results to primary closure of the soft tissues (DEVITT and others 1997). Given the complications in our cases the use of an active suction drain may have been beneficial in these dogs and should be considered in future patients. The short term follow up in these dogs may also have led to underreporting of postoperative complications such as recurrent abscess formation which can occur weeks to months following surgery.

To our knowledge, the dogs described here, are the first to be reported with unilateral CMO associated with ipsilateral otitis media, externa and para aural abscess formation. Although the relationship between these conditions is unclear, we hypothesise that CMO was the cause of the otitis media and externa and ultimately the development of a para aural abscess in each dog. This possibility should be considered when evaluating para aural abscessation in “breeds at risk”. Although surgical treatment is more complicated by the bony proliferation, surgical management using a

262 modified TECA-LBO can completely resolve the clinical signs without permanent neurological
263 complications.

264

265

266

267

268

269

270

271

272

273

274

275

276

277

278

279

280

281

282

283

284

285

286

287

288

289

290

291

Figure legend

Table 1; Patient signalment, history, management details and postoperative complications.

Figure 1; Photograph of dog 3 prior to surgery demonstrating non-healing discharging sinus on the left side of the face and palpable osseous proliferation (arrows).

Figure 2; Transverse CT image at the level of the tympanic bullae (A) and three-dimensional reconstruction (B) of the skull showing diffuse thickening of the left mandibular body and a large, densely ossified (>1000Hounsfield units (HU) exostosis enveloping the zygomatic process of the temporal bone, tympanic bulla and external ear canal. The left tympanic cavity and ear canal were patent, but filled with lower attenuation (130-140HU) non contrast enhancing material consistent with exudate/debris rather than vascular (granulation) tissue. A tract was present from the ventrolateral aspect of the osseous proliferation in the region of the external ear canal extending superficially to the region of the cutaneous sinus.

Figure 3; Intra-operative photographs of dog 1; (A) a skin incision made over the lateral aspect of the external ear canal and the soft tissues were dissected to expose the ossified tissue surrounding the external ear canal. (B and C) An ultrasonic bone curette (Sonopet; Stryker) was to excise the ossified tissue at the level of the distal horizontal canal. The ultrasonic bone curette was then used to debulk the osseous proliferation allowing identification of the external acoustic meatus prior to performing a bulla osteotomy.

Figure 4; External ear canal, x20 H&E. There is extensive mature woven bone, with regular medullary spaces, encircling the external ear canal (arrows), which is consistent with a diagnosis of craniomandibular osteopathy (CMO). The auricular cartilage is unremarkable. The lining of the canal is chronically inflamed (moderate otitis externa) with numerous ectatic ceruminous glands and abundant lamellar keratin within the lumen.

Figure 5; Transverse CT image at the level of the 2nd maxillary premolar tooth (A) and three-dimensional reconstruction (B) of the skull of dog 1, one week following surgery. Showing a large section of bone visible on preoperative CT (FIG 1) has been removed (to provide access to the ear canal). At the previous location of the horizontal external ear canal there is a hypoattenuating region consistent with abscess or seroma formation. There is a patchy contrast enhancement within the soft tissues on the lateral aspect of the new bone formation compatible with postoperative inflammatory tissue.

References

- Angus, J. C., Lichtensteiger, C., Campbell, K. L., *et al.* (2002) Breed variations in histopathologic features of chronic severe otitis externa in dogs: 80 cases (1995-2001). *Journal of the American Veterinary Medical Association* **221**, 1000-1006
- Axlund, T. W., Behrend, E. N., Sorjonen, D. C., *et al.* (2005) Canine hypophysectomy using a ventral paramedian approach. *Veterinary Surgery* **34**, 179-189
- Burk, R. & Broadhurst, J. (1976) Craniomandibular osteopathy in a Great Dane. *Journal of the American Veterinary Medical Association* **169**, 635-636
- Dennis, R., Barnett, K. & Sansom, J. (1993) Unilateral exophthalmos and strabismus due to craniomandibular osteopathy. *Journal of Small Animal Practice* **34**, 457-461
- Devitt, C. M., Seim, H. B., Willer, R., *et al.* (1997) Passive Drainage Versus Primary Closure After Total Ear Canal Ablation-Lateral Bulla Osteotomy in Dogs: 59 Dogs (1985–1995). *Veterinary Surgery* **26**, 210-216
- Fernando, S. (1967) Certain histopathologic features of external auditory meatus of cat and dog with otitis externa. *American Journal of Veterinary Research* **28**, 278–282
- Forterre, F., Dickomeit, M., Senn, D., *et al.* (2011) Microfenestration using the CUSA Excel ultrasonic aspiration system in chondrodystrophic dogs with thoracolumbar disk extrusion: a descriptive cadaveric and clinical study. *Veterinary Surgery* **40**, 34-39
- Franch, J., Cesari, J. & Font, J. (1998) Craniomandibular osteopathy in two Pyrenean mountain dogs. *The Veterinary Record* **142**, 455-459
- Fraser, G. (1961) The histopathology of the external auditory meatus of the dog. *Journal of Comparative Pathology and Therapeutics* **71**, 253-260
- Garzino-Demo, P., Boffano, P., Tanteri, G., *et al.* (2011) The use of an ultrasonic bone curette in the surgery of jaw tumors involving the inferior alveolar nerve. *Journal of Oral and Maxillofacial Surgery* **69**, e100-e104
- Hadeishi, H., Suzuki, A., Yasui, N., *et al.* (2003) Anterior clinoidectomy and opening of the internal auditory canal using an ultrasonic bone curette. *Neurosurgery* **52**, 867-871
- Harvey, R., Harari, J., Delauche, A. (2001) Etiopathogenesis and classification of otitis externa. *Ear diseases of the dog and cat*. Ames: Iowa State University Press 2001: 81-122

360 Hathcock, J. (1982) Craniomandibular osteopathy in an English Bulldog. *Journal of the American*
361 *Veterinary Medical Association* **181**, 389-389

362 Huchkowsky, S. L. (2002) Craniomandibular osteopathy in a bullmastiff. *The Canadian veterinary*
363 *journal* **43**, 883-885

364 Hudson, J. A., Montgomery, R. D., Hathcock, J. T., *et al.* (1994) Computed tomography of
365 craniomandibular osteopathy in a dog. *Veterinary Radiology and Ultrasound* **35**, 94-99

366 LaFond, E., Breur, G. J. & Austin, C. C. (2002) Breed susceptibility for developmental orthopedic
367 diseases in dogs. *Journal of the American Animal Hospital Association* **38**, 467-477

368 Matiasovic, M., Caine, A., Scarpante, E., *et al.* (2015) Imaging diagnosis—magnetic resonance
369 imaging features of craniomandibular osteopathy in an airedale terrier. *Veterinary Radiology*
370 *and Ultrasound* **57**, 27-29

371 Munjar, T., Austin, C. C. & Breur, G. (1998) Comparison of risk factors for hypertrophic
372 osteodystrophy, craniomandibular osteopathy and canine distemper virus infection. *Veterinary*
373 *Comparative Orthopedics and Traumatology* **11**, 37-43

374 Padgett, G. A., Mostosky, U. V. & Prieur, D. J. (1986) Animal model: the mode of inheritance of
375 craniomandibular osteopathy in West Highland White Terrier dogs. *American Journal of*
376 *Medical Genetics* **25**, 9-13

377 Pettitt, R., Fox, R., Comerford, E., *et al.* (2012) Bilateral angular carpal deformity in a dog with
378 craniomandibular osteopathy. *Veterinary and Comparative Orthopaedics and Traumatology*
379 **25**, 149-154

380 Pool, R. & Leighton, R. (1969) Craniomandibular osteopathy in a dog. *Journal of the American*
381 *Veterinary Medical Association* **154**, 657-660

382 Ratterree, W. O., Glassman, M. M., Driskell, E. A., *et al.* (2011) Craniomandibular osteopathy with a
383 unique neurological manifestation in a young akita. *Journal of the American Animal Hospital*
384 *Association* **47**, 7-12

385 Riser, W. H., Parkes, L. J. & Shirer, J. F. (1967) Canine Craniomandibular Osteopathy1. *Veterinary*
386 *Radiology* **8**, 23-31

387 Samy, R. N., Krishnamoorthy, K. & Pensak, M. L. (2007) Use of a novel ultrasonic surgical system for
388 decompression of the facial nerve. *The Laryngoscope* **117**, 872-875

- Schulz, S. (1978) A case of craniomandibular osteopathy in a Boxer. *Journal of Small Animal Practice* **19**, 749-757
- Spivack, R. E., Elkins, A. D., Moore, G. E., *et al.* (2013) Postoperative complications following TECA-LBO in the dog and cat. *Journal of the American Animal Hospital Association* **49**, 160-168
- Taylor, S. M., Remedios, A. & Myers, S. (1995) Craniomandibular osteopathy in a Shetland sheepdog. *The Canadian Veterinary Journal* **36**, 437-439
- Thompson, D., Rogers, W., Owen, M., *et al.* (2011) Idiopathic canine juvenile cranial hyperostosis in a Pit Bull Terrier. *New Zealand Veterinary Journal* **59**, 201-205
- Thompson, K. (2007) Bones and joints. In: *Jubb, Kennedy, and Palmer's pathology of domestic animals*. 5th edn. Eds Saunders Elsevier. pp 106-108
- Tobias, K., Barbee, D. & Pluhar, G. (1996) Intraoperative use of subtraction angiography and an ultrasonic aspirator to improve identification and isolation of an intrahepatic portosystemic shunt in a dog. *Journal of the American Veterinary Medical Association* **208**, 888-890
- Trowald-Wigh, G., Ekman, S., Hansson, K., *et al.* (2000) Clinical, radiological and pathological features of 12 Irish setters with canine leucocyte adhesion deficiency. *Journal of Small Animal Practice* **41**, 211-217
- Van der Gaag, I. (1986) The pathology of the external ear canal in dogs and cats. *Veterinary Quarterly* **8**, 307-317
- Watkins, J. & Bradley, R. (1966) Craniomandibular osteopathy in a Labrador puppy. *Veterinary Record* **79**, 262-264
- Watson, A., Adams, W. & Thomas, C. (1995) Craniomandibular osteopathy in dogs. *The Compendium on continuing education for the practicing veterinarian (USA)* **17**, 911-922
- Watson, A. D. J., Huxtable, C. R. R. & Farrow, B. R. H. (1975) Craniomandibular osteopathy in Doberman Pinschers. *Journal of Small Animal Practice* **16**, 11-19
- White, R. & Pomeroy, C. (1990) Total ear canal ablation and lateral bulla osteotomy in the dog. *Journal of Small Animal Practice* **31**, 547-553

Table 1; Patient signalment, history, management details and postoperative complications

Dog	Age, Sex, Breed	History summary	Surgical summary	Surgery time	Post-operative medication	Postoperative Complications
1	3y8m FN, WHWT	-Adopted at 1 year of age -Two year history of difficulty opening mouth -No difficulty eating -Four month history of left para-aural abscess formation	-TECA-LBO, -Ultrasonic bone curette used -Penrose drain placed	2h25m	-Methadone: 0.1-0.2 mg/kg IV every 4hours for 24 hours then buprenorphine 0.01-0.02mg/kg IV QID until discharge -Meloxicam: 0.1mg/kg PO SID for 5 days -Amoxicillin- clavulanic acid: 15 mg/kg PO BID for 5 days -Artificial tears	-Absent palpebral reflex -Re-presented 7 days postoperatively due to purulent discharge from the surgical site.
2	10y2m ME, WHWT	-One month history of left sided facial swelling consistent with para-aural abscess -Chronic renal disease (IRIS stage 1)	TECA-LBO	2h 10m	-Methadone: 0.1-0.2 mg/kg IV every 4hours for 24 hours then buprenorphine 0.01-0.02mg/kg IV QID until discharge -Tramadol hydrochloride: 4mg/kg PO TID for 5 days -Cefalexin: 20mg/kg PO BID for 7 days -Artificial tears	-Palpebral reflex reduced
3	3y4m ME, WHWT	-Adopted at 1year of age -Two year history of left sided facial swelling & recurrent left sided otitis externa. -Three week history left para-aural abscess formation	-TECA-LBO -Ultrasonic bone curette used -Penrose drain placed	2h5m	-Methadone: 0.1-0.2 mg/kg IV every 4hours for 24 hours then buprenorphine 0.01-0.02mg/kg IV QID until discharge -Meloxicam: 0.1mg/kg PO SID for 7 days -Cefalexin: 20mg/kg PO BID for 14 days -Artificial tears	-Palpebral reflex reduced -Examination 14 days postoperatively by the referring veterinarian revealed continued serosanguinous discharge from the surgical incision

WHWT- West Highland White Terrier, FN- female neutered, ME- male entire, TECA- Total ear canal ablation, LBO- Lateral Bulla osteotomy.

Figure legends

Table 1; Patient signalment, history, management details and postoperative complications.

Figure 1; Photograph of dog 3 prior to surgery demonstrating non-healing discharging sinus on the left side of the face and palpable osseous proliferation (arrows).

Figure 2; Transverse CT image at the level of the tympanic bullae (A) and three-dimensional reconstruction (B) of the skull showing diffuse thickening of the left mandibular body and a large, densely ossified (>1000Hounsfield units (HU) exostosis enveloping the zygomatic process of the temporal bone, tympanic bulla and external ear canal. The left tympanic cavity and ear canal were patent, but filled with lower attenuation (130-140HU) non contrast enhancing material consistent with exudate/debris rather than vascular (granulation) tissue. A tract was present from the ventrolateral aspect of the osseous proliferation in the region of the external ear canal extending superficially to the region of the cutaneous sinus.

Figure 3; Intra-operative photographs of dog 1; (A) a skin incision made over the lateral aspect of the external ear canal and the soft tissues were dissected to expose the ossified tissue surrounding the external ear canal. (B and C) An ultrasonic bone curette (Sonopet; Stryker) was to excise the ossified tissue at the level of the distal horizontal canal. The ultrasonic bone curette was then used to debulk the osseous proliferation allowing identification of the external acoustic meatus prior to performing a bulla osteotomy.

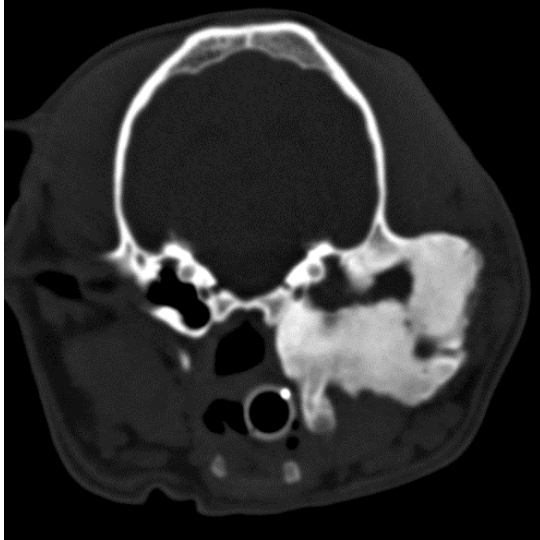
Figure 4; External ear canal, x20 H&E. There is extensive mature woven bone, with regular medullary spaces, encircling the external ear canal (arrows), which is consistent with a diagnosis of craniomandibular osteopathy (CMO). The auricular cartilage is unremarkable. The lining of the canal is chronically inflamed (moderate otitis externa) with numerous ectatic ceruminous glands and abundant lamellar keratin within the lumen.

Figure 5; Transverse CT image at the level of the 2nd maxillary premolar tooth (A) and three-dimensional reconstruction (B) of the skull of dog 1, one week following surgery. Showing a large section of bone visible on preoperative CT (FIG 1) has been removed (to provide access to the ear canal). At the previous location of the horizontal external ear canal there is a hypoattenuating region consistent with abscess or seroma formation. There is a patchy contrast enhancement within the soft tissues on the lateral aspect of the new bone formation compatible with postoperative inflammatory tissue.

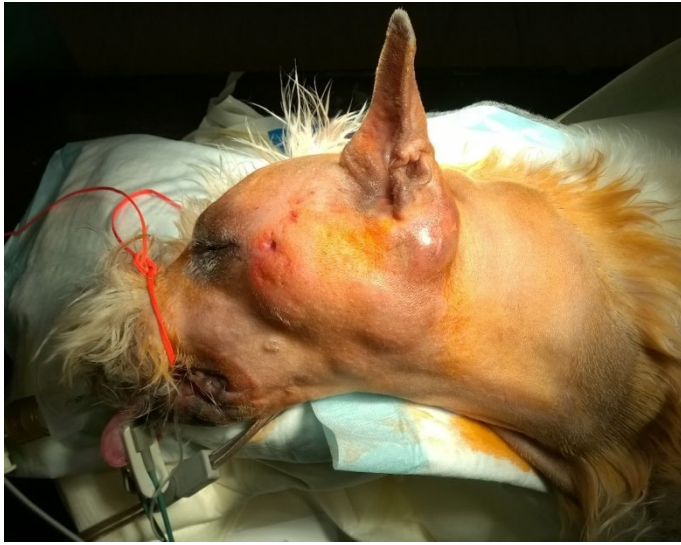

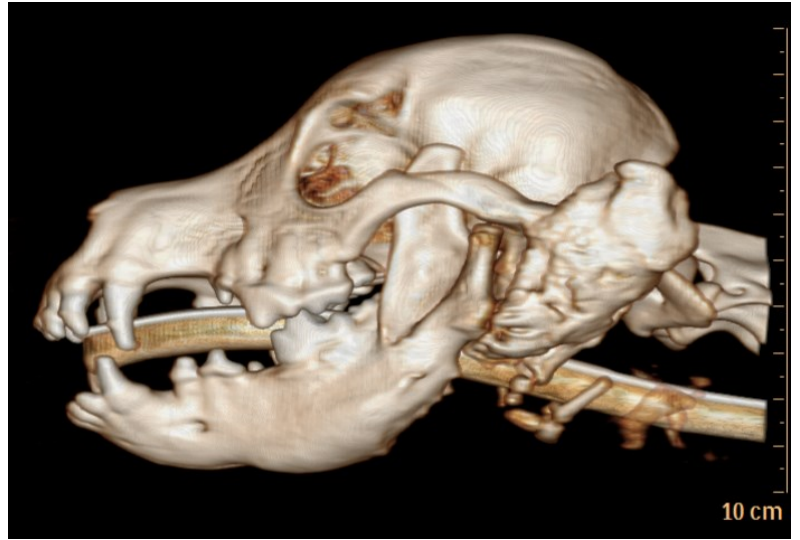FIG 1; Photograph of dog 3 prior to surgery demonstrating non-healing discharging sinus on the left side of the face and palpable osseous proliferation (arrows)

FIG 2; Transverse CT image at the level of the tympanic bullae (A) and three-dimensional reconstruction (B) of the skull showing diffuse thickening of the left mandibular body and a large, densely ossified (>1000Hounsfield units (HU) exostosis enveloping the zygomatic process of the temporal bone, tympanic bulla and external ear canal. The left tympanic cavity and ear canal were patent, but filled with lower attenuation (130-140HU) non contrast enhancing material consistent with exudate/debris rather than vascular (granulation) tissue. A tract was present from the ventrolateral aspect of the osseous proliferation in the region of the external ear canal extending superficially to the region of the cutaneous sinus.

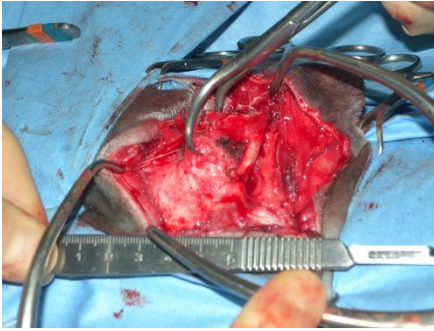


(A)

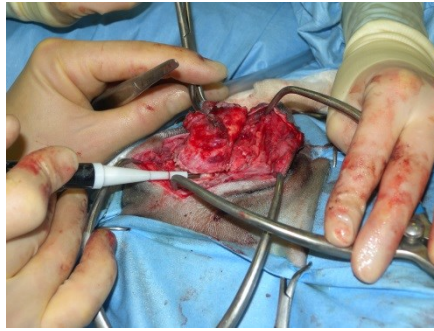


(B)

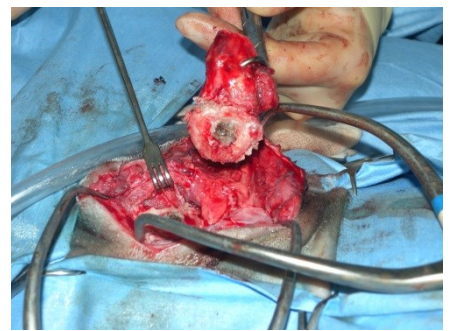
FIG 3; Intra-operative photographs of dog 1; (A) a skin incision made over the lateral aspect of the external ear canal and the soft tissues were dissected to expose the ossified tissue surrounding the external ear canal. (B and C) An ultrasonic bone curette (Sonopet; Stryker) was used to excise the ossified tissue at the level of the distal horizontal canal. The ultrasonic bone curette was then used to debulk the osseous proliferation allowing identification of the external acoustic meatus prior to performing a bulla osteotomy.



(A)



(B)



(C)

FIG 4; External ear canal, x20 H&E. There is extensive mature woven bone, with regular medullary spaces, encircling the external ear canal (arrows), which is consistent with a diagnosis of craniomandibular osteopathy (CMO). The auricular cartilage is unremarkable. The lining of the canal is chronically inflamed (moderate otitis externa) with numerous ectatic ceruminous glands and abundant lamellar keratin within the lumen.

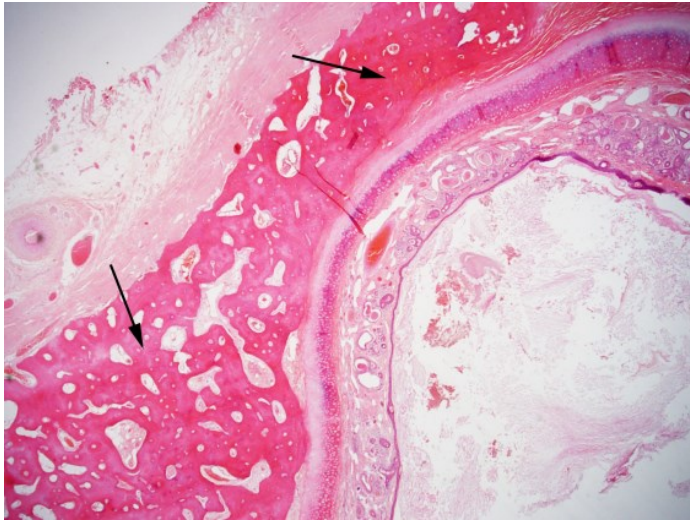
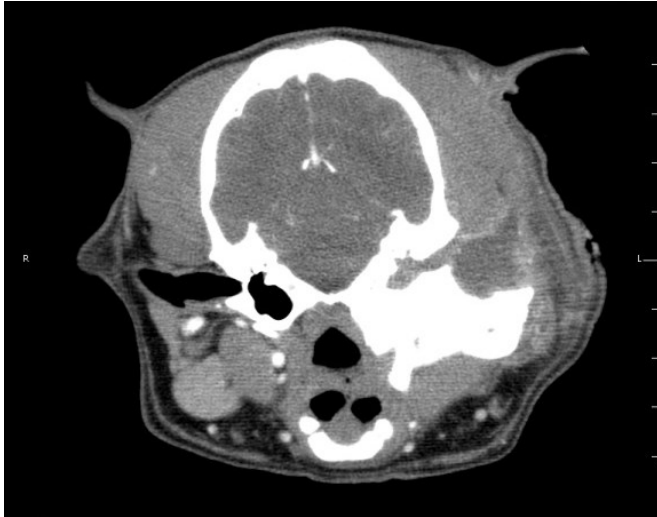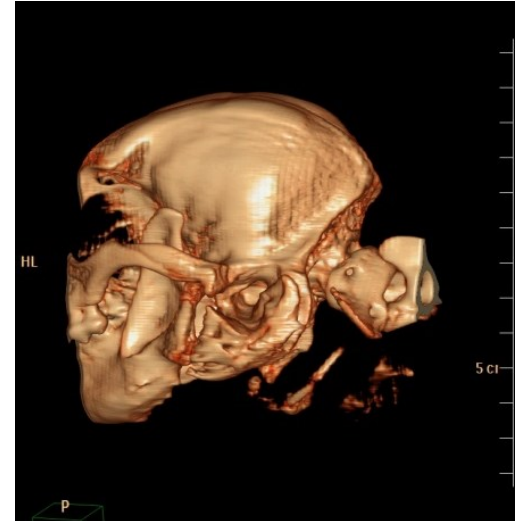


FIG 5; Transverse CT image at the level of the 2nd maxillary premolar tooth (A) and three-dimensional reconstruction (B) of the skull of dog 1, one week following surgery. Showing a large section of bone visible on preoperative CT (FIG 1) has been removed (to provide access to the ear canal). At the previous location of the horizontal external ear canal there is a hypoattenuating region consistent with abscess or seroma formation. There is a patchy contrast enhancement within the soft tissues on the lateral aspect of the new bone formation compatible with postoperative inflammatory tissue.



(A)



(B)