

This is the author's accepted manuscript of an article published in *Journal of Feline Medicine and Surgery*.

The final publication is available at SAGE Journals via
<https://doi.org/10.1177/1098612X17699466>.

The full details of the published version of the article are as follows:

TITLE: Postoperative complications associated with external skeletal fixators in cats

AUTHORS: Lee Beever, Kirsty Giles, Richard Meeson

JOURNAL TITLE: Journal of Feline Medicine and Surgery.

PUBLICATION DATE: June 8, 2017 (online)

PUBLISHER: SAGE Publications

DOI: 10.1177/1098612X17699466

Postoperative Complications Associated with External Skeletal Fixators in Cats

Lee Beever; Kirsty Giles; Richard L Meeson.

1Queen Mother Hospital for Animals, Department of Clinical Sciences and Services, Royal Veterinary College, Hawkshead Lane, North Mymms, Hertfordshire, UK

Authors

Lee Beever BVetMed (Hons), MRCVS

Kirsty Giles BVetMed, MRCVS

Richard Meeson MA VetMB, MVetMed, DipECVS, PGCertVetEd, FHEA, MRCVS

Keywords

External fixator, postoperative complication, cat, feline.

Tagline

External skeletal fixator complications in cats

Correspondence to:

Richard Meeson MA VetMB, MVetMed, DipECVS, PGCertVetEd FHEA, MRCVS

Lecturer in Orthopaedic Surgery

The Royal Veterinary College

Queen Mother Hospital for Animals

Hawkshead Lane, North Mymms

Hatfield, Hertfordshire AL9 7TA

United Kingdom

Phone: +44 707 666 366

E-mail: rmeeson@rvc.ac.uk

Abbreviations

- **DPTI**- deep pin tract infection
- **ESF**- external skeletal fixator
- **IM**- intramedullary
- **FAC**- fixator associated complication
- **PTI**- pin tract infection
- **SPTI**- superficial pin tract infection

Abstract:

Objectives:

The objective was to quantify external skeletal fixator (ESF) associated complications in cats and to identify potential risk factors.

Methods:

A retrospective review of medical records and radiographs following ESF placement was performed.

Results:

Case records of 140 cats were reviewed; fixator associated complications (FAC), occurred in 19% of cats. The region of ESF placement was significantly associated with complication development. Complications developed most frequently in the femur (50%), tarsus (35%) and radius/ulna (33%). Superficial pin tract infection (SPTI) and implant failure accounted for 45% and 41% of all FACs, respectively. SPTI occurred more frequently in the femur, humerus and tibia, with implant failure more frequent in the tarsus. No association between breed, age, sex, weight, fracture type (open vs closed), ESF classification, number of pins per bone segment, degree of fracture load sharing and the incidence or type of FAC was identified. No association between region of placement, breed, age, sex, weight, fracture type (open vs closed), ESF classification, number of pins per bone segment, fracture load sharing and the time to complication development was identified.

Conclusions and relevance:

Complication development is not uncommon in cats following ESF placement. The higher complication rate in the femur, tarsus and radius/ulna should be considered when reviewing options for fracture management; however cats appear to have a lower rate of pin tract infections than that reported in dogs.

Introduction

External skeletal fixators (ESF) are used for numerous orthopaedic conditions including fracture stabilisation, joint immobilisation, angular limb deformity and shear injury management. ESFs may be either a sole fixation device, or used as adjunctive stabilisation and are available in a variety of configurations including linear, circular, hinged, free form and hybrid forms.¹⁻⁴ Whilst ESFs remain a versatile and useful tool in orthopaedics, reservations regarding their use are based on high reported fixator associated complication (FAC) rates, particularly implant failure and pin tract infection (PTI).⁵⁻⁸

PTIs occur most commonly when there has been significant penetration and disruption to the adjacent soft tissues. This allows bacterial contamination of the skin to pin interface, leading to superficial pin tract infection (SPTI), which can progress to deep pin tract infection (DPTI), with associated bone lysis and osteomyelitis.⁹⁻¹¹ Implant failures include pin loosening, breakage or bending; clamp loosening and connecting bar breakage leading to construct failure. Development of FACs in dogs has previously been reported up to 100% in some reports,^{8, 12} although more recent studies in cats have shown lower complication rates, ranging from 26% to 65%.^{4, 5, 13, 14}

Whilst individual studies have evaluated specific ESF types, at specific anatomic locations, in defined groups of animals, it remains difficult to compare overall ESF complication rates. To the authors' knowledge, there has been no comprehensive overview of complications arising from all ESFs placed for feline orthopaedic conditions. The aim of this study was to review postoperative complications attributable to the ESF in cats and to identify factors associated with complication development in a large number of clinical cases.

Materials and methods

Medical records of cats with an ESF placed between January 2007 and March 2014 were reviewed. To be included in the study, clinical records needed to be present to the point of frame removal and/or fracture union. The following information was gathered for each patient where possible: signalment, ESF configuration, anatomic region, fracture type (open or closed), the number of pins placed per bone segment (appendicular skeleton only), and FACs. ESF configuration was determined from clinical records and radiographs and categorised into four groups: linear, free-form, hybrid and circular. Long bone fracture load sharing was assessed and separated into load-sharing, partial load-sharing and non-load-sharing as previously described.¹⁵ Specific ESF features were also assessed, see Table 1. Each ESF was assigned to one of ten anatomical regions (Figure 1).

FACs were divided into four categories: **1)** SPTI, including cases with associated pin loosening, **2)** DPTI, including any cases with associated pin loosening, **3)** fractures and **4)** implant failure; defined as any complication associated with the frame without concurrent infection, including loosening, breaking/bending of pins, breakage of connecting bars or clamp failure, and implant migration.

SPTI was diagnosed by presence of one or more of: **(a)** purulent discharge (with or without positive bacterial culture); **(b)** a positive culture result, or; **(c)** at least one sign of infection (pain or tenderness, localised swelling, redness or heat), or a positive response to antimicrobial therapy.¹⁶ DPTIs were diagnosed when the previously mentioned criteria were met and evidence of osteomyelitis or bone sequestrum was seen radiographically.

Statistical analysis

Statistical analyses were performed using IBM SPSS Statistics for Windows, Version 23.0; SPSS Inc. Data were assessed for normality using the Shapiro-Wilk Test. Categorical variables were analysed using Chi-squared or Fisher's exact test as appropriate. For analysis of regional association with complication development and type, regions with less than six cases were excluded from analysis. Analysis of associations between age, weight and development of complications; fracture type (open

vs closed) and time of FAC were assessed using the Mann-Whitney U test. The Kruskal-Wallis test was used to identify associations between patient age, weight and type of complications, and associations between sex, ESF configuration, pin number, load sharing, fracture type (open vs closed) and region of placement with the time to FAC development. Relationships between age, weight and time of complication were assessed by Spearman's rank correlation. A $P<0.05$ was considered significant.

Results

A total of 140 cats managed with an ESF met the inclusion criteria. Age on presentation ranged from three months to 12 years (median two years). Body weight ranged from 1.2kg to 8.6kg (median 4.2kg). Fifty cats were female (41 neutered), and 90 were male (80 neutered). Seventeen breeds of cat were represented, the most common being Domestic Short Hair (n=101), followed by Domestic Long Hair (n = 10), then Siamese (n=7). Of the 140 cats, 74% (n=104) had closed fractures and 26% (n=36) had open fractures. Overall the most common region of placement was the tibia (24%, n=34) as shown in Figure 1.

It was possible to identify specific ESF configuration in 109 of 140 cats. The majority of ESFs were linear in 88% (n=96) of cats, of which 67% (n=54) were type I, 31% (n=32) type II and 2% (n=2) were type III. The remaining fixators were free form in 9% (n=10), and hybrid in 3% (n=3) of cats. The majority of constructs used clamps (86%, n=94) with the remaining 14% (n=15) using epoxy putty. The number of bi-cortical transfixing pins placed was identified in 94 cats, the total number of pins placed ranged from 2 to 9 (mean 6). In the proximal segment this ranged from 1 to 4 (mean 3) and 1 to 6 (mean 3) in the distal segment. Additional ESF configuration results are summarised in Table 2.

FACs occurred in 19% (n= 27), of cats. Two cats had two separate FACs over time, which were treated as separate complications, giving 29 distinct FACs. The time to diagnosis of complications ranged from 10 to 154 days postoperatively (median 43 days). Figure 2 shows the overall frequency and type of FACs that developed; the most common being SPTI accounting for 45% of all complications seen, followed by implant failure (41%).

Complications occurred in eight of the ten anatomical regions, summarised in Table 3. Region of placement was significantly associated with FAC development ($P=0.001$). The highest complication rate was seen in the femur (50%) followed by the tarsus (35%), and radius/ulna (33%). The lowest complication rates were in the tibia (3%), pes (5%) and stifle (0%). Region was not significantly associated with complication type however ($P=0.505$). Regional distribution of complication types is shown in Figure 3, with SPTI the most frequent FAC in the femur and humerus (Appendix 1). Implant failure was the most common complication seen in the tarsus (Figure 3).

151
152
153
154
155
156
157
158
159
160
161
162
163
164
165
166
167
168
169
170
171
172
173
174
175
176
177
178
179
180

Of the 13 cats that developed a SPTI, four were managed successfully with antimicrobial treatment alone, three required pin-tract care alone until planned ESF removal, and four required pin removal (Appendix 2). Two cats with SPTI required limb amputation; one due to non-union caused by pin loosening attributed to SPTI, and the other due to unrelated wound complications. Of the 12 cats with implant failure, 50% suffered from broken pins, of which 5 were in the distal bone segment and all of these cats had a transarticular tarsal ESFs. The sixth had a fixator placed on the pes. Loose pins accounted for 33% (n=4), of implant failures, one cat traumatically displaced a pin from the femur and one cat bent a pin in the manus. One traumatic clamp and no epoxy putty failures were reported (Appendix 2).

Load-sharing of long bone fractures was assessed from the radiographs of 57 cats. Load-sharing occurred in 12 (21%), partial load-sharing in 10 (18%) and non-load-sharing in 35 (61%) cats. No significant association between the degree of load sharing and FAC development ($P=0.161$) was identified. No significant associated between breed, age, sex, weight, fracture type (open vs closed), fixators pins per bone segment and the incidence or type of FAC was identified. Similarly there was no association between ESF type and the incidence ($P=0.634$) or type ($P=0.696$) of FAC. Time to FAC diagnosis was not significantly associated with any variable tested including age, sex, weight, region of placement, fracture type (open vs closed), ESF classification, pin number, load sharing and complication type.

The only frame feature significantly associated with FAC develop was the use of an intramedullary (IM) pin (Table 2). IM pins were placed in 36 cats, and 44% of cats that had an IM pin placed developed a FAC. No specific complication type was significantly associated with IM pin usage. When assessed by region 53% (n=19) of IM pins were placed in the femur and 25% (n=9), in the humerus.

Discussion

This is the largest review of ESF usage in cats to date. The most common type of ESF used was the linear ESF, of which the type I and II arrangements predominated. Unsurprisingly, male cats were over-represented, and the median age was young, at two years. Tibial fractures were the most common fracture location for ESF placement. The predominance of the tibia probably relates to the ease of placement with the medial tibial providing safe corridors for pin placement. Despite being the location with the highest level of fixator usage, it had one of the lowest complication rates.

The overall FAC rate for cats having an ESF placed was 19%. Region of ESF placement was significantly associated with the development but not the type of FAC developed. The most common locations for FACS were the femur (50%), followed by the tarsus (35%) and radius/ulna (33%). Complication type however, could not be significantly attributed to a location. This may relate to the group sizes when complications were subdivided by type, preventing a significant result from being statistically shown (type II error). To reduce statistical errors, groups with fewer than six cats were excluded from statistical analysis. The majority of complications were SPTI and implant failure, both with a 9% overall complication rate respectively; accounting for 45% and 41% of all FACs, respectively. SPTI is a well-documented complication following ESF placement and was seen in 9% of cats having an ESF placed. This is lower than previously reported SPTI rates in dogs which range from 28% to 57%.^{17, 18} It therefore appears that cats are less likely to develop PTIs than dogs, and this is something the authors have noted anecdotally. As a complication type, SPTIs accounted for 45% of all FACs, similar to a previous study investigating feline tibial fixation with 41%.⁶ While results of our study showed no significant regional association with FAC type, the low levels of tibial SPTIs and high levels of femoral SPTIs, are suggestive of a true or surrogate influence of anatomic region (Appendix 1). Studies of the canine femur and humerus have shown an absence of clear, safe corridors for transfixation of these bones due to the complex regional anatomy, and only limited safe corridors in the radius.^{19, 20} Interference with tendons and musculature in these regions may lead to discomfort, joint stiffness and decrease use of the limb, all of which may predispose patients to increased FACs due to tissue morbidity and patient interference. PTIs and pin loosening are associated with increased tissue penetration and disruption and hence bone segments with prominent adjacent muscle groups,

such as the femur are at risk.^{8, 11} The reduced rate of PTIs in cats compared with dogs may be due to the fact that cats appear to have a relatively smaller soft-tissue envelope, typically with significantly smaller proximal limb muscle mass and a more marginal subcutaneous fat layer. This could result in a reduced tissue volume associated with a pin tract and potentially less soft tissue morbidity and a lower risk of pin loosening or PTIs.¹¹ It is known from animal studies that the technique of pin placement can affect the development of PTIs. Minimising the distortion of soft-tissues is important,^{2, 21} and penetrative stab incisions through the soft-tissues of 2-3mm are recommended.² Sufficient incision size can reduce the rubbing between the pin and the soft-tissues that contributes to localised tissue reaction. Unfortunately, no such data was present on the sizes and methods used for establishing the soft-tissue releasing incision, however it is commonplace at this institution to make stab incisions of up to 6mm in size and to use a small haemostat to open a tunnel through overlying musculature. In people, PTIs remain a significant issue and numerous postoperative strategies of pin site care have been proposed.²² However, a recent meta-analysis on pin site care showed insufficient evidence to identify a strategy of pin site care that minimises infection rates.²² Adequately powered randomised trials are required to examine the effects of different pin care regimens prior to making further recommendations.²² Other risk factors for small animal surgical site infection included gender, increased bodyweight and duration of anaesthesia.^{23, 24} In this study however, when assessing PTIs, no association with age, body weight, or gender was found, although anaesthesia duration data was not available. A further consideration beyond the scope of this study is the varied skin microflora seen in cats and dogs, which may also influence infection development.²⁵ Despite the frequency of PTIs, which is notably lower in cats than in the dog, PTIs are usually manageable, as ESF implants can be readily removed and minor short term morbidity associated with SPTIs often resolves following antimicrobial administration and adequate pin care or implant removal.^{7, 9, 26} Of the 13 cats with PTIs, only 5/13 required specific pin removal, with the remainder managed without surgical intervention until frame removal.

The femur was the region with highest level of fixator associated complications, at 50%. Other studies have reported lower rates of up to 23%.¹³ In another study of 35 cats, femoral fracture stabilisation with an ESF resulted in excellent healing in all cats with low morbidity. They concluded that there remains a place for their use in the femur when correctly applied and plate fixation may not be an

optimal choice for all fractures given that application can be expensive.²⁷ This conclusion is supported by a population of dogs and cats undergoing femoral fracture stabilisation with modified acrylic ESFs in which 100% of the dogs and none of the cats developed an FAC.²⁸

Implant failure had an overall incidence of 9%, representing 41% (n=12) of all complications. It was the most common FAC in the tarsus (63% of tarsal FACs). Overloaded implants, either due to patient factors or inappropriate implant choice, are vulnerable to fatigue and failure.^{5, 9, 29} In this series, the pin was the weakest part of the ESF construct, with pin breakage in six cats, two of which broke multiple pins. Interestingly, five of these six cats had a tarsal ESF and therefore the inclusion of transarticular tarsal ESFs in this study has given this complication a greater prominence. Other studies have also shown the tarsus as a common region for the development of FACs.^{2, 12, 18} Tarsal ESFs are mechanically vulnerable being subject to significant transarticular bending forces as they cross the flexed tarsocrural joint. Relatively small pins may also have to be placed in the metatarsal bones, further increasing the vulnerability to mechanical failure. Interestingly there was a low rate of tarsal PTI, (13% of tarsal FACs), possibly relating to the limited soft-tissue envelop.

Load sharing between the bone and the fixator will undoubtedly alter the loading on the pins. Previous guidelines have advised that surgeons should aim to maximise load sharing between fixator and bone column.²¹ A canine tibia study corroborated that pins holding unstable fractures had increased pin loosening.³⁰ In our study, the degree of load sharing was not associated with the development of complications, however specific fracture configuration is likely to have influenced the surgeon's choice of stabilisation and ESF configuration to account for this. The majority of cats in this study had non-load sharing constructs and that is likely to have been a consideration at the outset when planning the fixation method. Activity will also have a role on implant loading and complication development, however it was not possible to determine activity levels of each individual cat following discharge and this could have had an influence on complication development. All animals were discharged with similar instructions on restricted cage rest and exercise for the first 6-8 weeks, however exercise programmes thereafter may vary. Notably, ESFs placed at the pes, manus and combined mandible/maxilla frequently suffered from implant failure. Mandibular fractures can be stabilised using free form ESFs in cats which have the added advantages of providing low weight versatile

stabilisation.^{28, 31, 32} Owen *et al* (2004) reported that in mandibular fractures stabilised with pins and either epoxy putty or acrylic, pin loosening was commonly observed at the time of ESF removal.³² Due to the low overall numbers of fixators placed at these regions, the groups sizes are too small to infer substantial conclusions. Notably, the IMEX SK clamp system was used over the study period, and only one connecting bar coupling failure was identified, supporting both of their ongoing and versatile use in cats. However, it is acknowledged that mechanical degradation with clamp re-use is reported,³³ and we cannot comment on the exact number of re-uses of the clamps from this retrospective.

This study showed that pin loosening without infection was a rare complication occurring in only four cats. There are several important factors to consider when placing fixators pins to reduce pin loosening. The first factor is pin size, as the surgeon must balance the need to use a pin that is large enough to provide sufficient stiffness, but small enough to avoid leaving a critical size defect following pin removal.^{21, 34} The conventional pin size recommendation is between 20 - 30% of bone diameter which should be accurately measured on preoperative radiographs.^{21,11, 34} Even small pins of only 20% of bone diameter can cause a 38% reduction in bone strength.³⁵ Unfortunately, the surgeon must balance a safer, narrower pin diameter, against decreased construct stiffness and thus the potential for greater fracture instability, higher gap strain and impaired fracture healing.^{21, 34} A further important factor is the number of pins placed. The most common number of pins in our study was six, with three pins placed in each fracture segment. Few fractures had the minimum of two pins placed per bone segment, and most were within guidelines of placing three to four pins per segment.^{21, 34, 36} Increasing the number of pins increases the stiffness of the construct and hence reduces the loading placed on individual pin-bone interfaces. Pin number per segment was not shown to be significantly associated with the development of complications, however only two cats had one pin per segment and one of these developed a SPTI. With such small numbers, no firm conclusions can be made. We also acknowledge that method of pin insertion can also affect development of PTI, as it impacts on the pin-bone interface, critical for overall stability of the fixator. Inappropriate technique can lead to excessive heat generation resulting in thermal osteonecrosis and premature pin loosening.^{21, 37} Animal studies have shown that bone undergoes significant resorption when heated to 50°C for 60 seconds or longer,³⁸ and pin insertion with a high speed drilling results in significantly higher bone

temperatures. It is therefore recommended that pins are placed at a slow speed (150rpm or less), as high speed placement reduces long term pin extraction forces when compared with low speed placement.^{2, 21, 36, 37} A further technique factor is the forward drilling force, which can affect maximal cortical bone temperatures when drilling.³⁹ Again, this type of information was not available in a retrospective study. Pre-drilling a pilot hole prior to pin placement is also standard practice at this institution and has been shown to increase pull out strength by 13.5% when compared to direct pin placement.⁴⁰ Pre-drilling also reduces bone micro fracture damage to the entry and exit sites of both the near and far cortices.⁴⁰ The ideal sized pilot hole should approximate but not exceed the inner diameter of a positive profile pin. In veterinary medicine it is commonly recommended to use a drill bit 10% smaller than the pin diameter in combination with a drill sleeve to prevent soft tissue trauma.² The financial constraints in veterinary practice may influence the maintenance of good quality sharp drills, which may cause increased thermal damage when blunt.⁴¹ An investigation into three commonly used drill bit reprocessing methods for 2.5mm drill bits compared reprocessed with new drill bits found cortical drill time was significantly greater in the reprocessed group compared to the new group.⁴¹ It is therefore important that the surgeons should ensure the equipment is maintained.^{21,}⁴² Irrigation has also been shown to be an important factor in keeping bone temperatures below critical, particularly with larger drill bits.⁴² Another approach to maximise the pin-bone interface is to use threaded pins as they have increased pin-bone contact area and hence increased resistance to pull-out when compared with smooth pins.^{21, 36}

Iatrogenic bone fracture was uncommon in this study, occurring in only 1% of cats. This serious complication usually has contributing factors such as multiple injuries, the presence of empty drill holes and inappropriate postoperative exercise restriction.³⁴

A key feature of the ESF is its flexibility in design, and there are numerous frame configurations, implant types, sizes and materials available which can affect construct strength and stability.⁴³ The use of an IM pin was shown to be associated with complication development, however the vast majority of IM pins used were in the femur and the humerus, which had a higher risk of FAC development. IM pins are commonly used at these sites to help fracture alignment and to improve resistance to bending.^{27, 44} Their location of use will also be influenced by the regional anatomy, as

some bones lend themselves to adjunctive IM pin fixation, such as the femur, humerus and tibia, however fracture configuration such as comminution will also be a consideration. It is important to note therefore that their risk association may be a surrogate marker for their usage in higher risk zones, or higher risk fracture configurations.

No other ESF feature including frame type, use of epoxy putty or clamps was associated with FAC development. Complications have previously been shown to be more common when more complex ESF frames are used.^{5, 6} However in this study, no significant difference was seen between type I, II and III linear ESFs. Type I ESFs only utilise half pins in their frame configuration, compared to types II and III which contain full pins. As discussed, PTIs are more likely to develop when there has been significant soft tissue penetration and the use of half pins may minimise disruption.^{11, 45} An effect of full vs half pin was not shown here, whereas the effect of region was. Notably the two most effected regions do not readily lend themselves to full pin usage, and this may have affected the impact of frame configuration type. The role of full vs half pins ideally needs to be compared in single anatomical regions, with sufficient case numbers, in a prospective manner. A caveat when comparing frame configuration data from this study to other situations is the manufacturer of the ESF components; as differing systems have variable bar radius, and clamp stability, leading to differences in frame stiffness, and bending resistance. Furthermore, the retrospective nature of this study means that surgeons were intentionally selecting a particular frame configuration for a particular fracture, and therefore the association of frame configuration with complications has to be viewed carefully.

This study was retrospective in nature, and multiple surgeons contributed cases over the study period, creating variation in case management and case selection. Detailed evaluation of the initial injury was outside the scope of this study and is likely to greatly influence choice of stabilisation and potentially FAC development. Likewise, intra-operative technical aspects of pin placement were not available for evaluation. The type and size of pins placed was also not consistently available for analysis and due to the referral nature of the caseload, under reporting of minor complications could have occurred.

Conclusions

This is the largest study to date, reviewing ESF placement and fixator complications in cats. The overall total complication rate in cats is moderate at 19%; however lower than in dogs. The cat therefore may be a better choice for ESF placement than dogs. Region of placement was significantly associated with complication development, with the femur being the most common site of FACs, and the complications seen there were dominated by PTIs. The next most common site of FACs was the tarsus where implant failures predominated. This difference is attributed to the differing conditions seen in these regions with a bigger soft-tissue mass and lack of safe corridors on the lateral femur, whereas transarticular frames in the tarsus are subject to high biomechanical bending forces and a smaller soft-tissue envelope. Special care should be taken with transarticular frames to ensure sufficient numbers and sizes of pins are used, and that type II frames may be preferable, but no firm conclusions from such a small group can be made. Frame configuration, pins per segment, open vs closed and degree of load-sharing did not appear to affect FACs, however it appears 'the rules' of external skeletal fixation were generally or assumed to have been abided by here. Being a retrospective study, confounding influences and factors such as pin placement technique were not available and may need consideration. However, it is entirely conceivable however that even when all the 'rules' are followed correctly, there will be a finite level of complications, mostly pin tract infections which relate to the nature of a transcutaneous implant. A prospective evaluation of pin designs used for similar fracture configurations from the same anatomical location is needed, and feasibly other strategies such as silver or hydroxyapatite coated pins may be required to reduce these complications further. On balance, ESFs can be successfully used to manage a range of complex injuries in a wide variety of anatomical locations and their use in cats appears to be better tolerated than in dogs. Further consideration should be given when considering placement in certain locations such as the femur and tarsus.

Acknowledgements

Conflict of interest

The authors' have no potential conflicts of interest with respect to the research, authorship or publication of this article.

Funding

The authors' received no financial support for the research, authorship or publication of the article.

Legend

- **Table 1.** Additional ESF features
- **Table 2.** Additional ESF configuration association with fixator associated complications
- **Table 3.** Fixator associated complication development at each anatomical region
- **Figure 1.** Overall anatomic distribution of fixator placement
- **Figure 2.** Distribution of fixator associated complications
- **Figure 3.** Regional distribution of fixator associated complication types as a percentage of the overall fixator associated complications
- **Appendix 1.** Type of fixator associated complications by anatomical region
- **Appendix 2.** Fixator associated complication case details

References

1. Jaeger GH, Wosar MA, Marcellin-Little DJ, et al. **Use of hinged transarticular external fixation for adjunctive joint stabilization in dogs and cats: 14 cases (1999-2003).** *J Am Vet Med Assoc* 2005; 227: 586-591.
2. Piermattei DL, Flo GL and Decamp CE. Piermattei DL, Flo GL and Decamp CE (eds). **Brinker, Piermattei and Flo's handbook of small animal orthopaedics and fracture repair.** 4th ed. St Louis, MO: Saunders Elsevier, 2006.
3. De La Puerta B, Emmerson T, Moores A , et al. **Epoxy putty external skeletal fixation for fractures of the four main metacarpal and metatarsal bones in cats and dogs.** *Vet Comp Orthop Traumatol* 2008; 21: 451-458.
4. Kulendra E, Grierson J, Okushima S, et al. **Evaluation of the transarticular external skeletal fixator for the treatment of tarsocrural instability in 32 cats** *Vet Comp Orthop Traumatol* 2011; 24: 320-325.
5. Gemmill T, Cave T, Clements D, et al. **Treatment of canine and feline diaphyseal radial and tibial fractures with low-stiffness external skeletal fixation.** *J Small Anim Pract* 2004; 45: 85-91.
6. Perry K and Bruce M. **Impact of fixation method on postoperative complication rates following surgical stabilization of diaphyseal tibial fractures in cats.** *Vet Comp Orthop Traumatol* 2015; 28: 109-115.
7. Fitzpatrick N, Riordan JO, Smith TJ, et al. **Combined intramedullary and external skeletal fixation of metatarsal and metacarpal fractures in 12 dogs and 19 cats.** *Vet Surg* 2011; 40: 1015-1022.
8. Anderson GM, Lewis DD, Radasch RM, et al. **Circular external skeletal fixation stabilization of antebrachial and crural fractures in 25 dogs.** *J Am Anim Hosp Assoc* 2003; 39: 479-498.
9. Krischak GD, Janousek A, Wolf S, et al. **Effects of one-plane and two-plane external fixation on sheep osteotomy healing and complications.** *Clin Biomech* 2002; 17: 470-476.
10. Dudley M, Johnson AL, Olmstead M, et al. **Open reduction and bone plate stabilization, compared with closed reduction and external fixation, for treatment of**

451 **comminuted tibial fractures: 47 cases (1980-1995) in dogs.** *J Am Vet Med Assoc*
452 1997; 211: 1008-1012.

453 11. Harari J. **Complications of external skeletal fixation.** *Vet Clin North Am Small Anim*
454 *Pract* 1992; 22: 99-107.

455 12. Halling K, Lewis D, Jones R, et al. **Use of circular external skeletal fixator constructs**
456 **to stabilize tarsometatarsal arthrodeses in three dogs.** *Vet Comp Orthop Traumatol*
457 2004; 17: 204-209.

458 13. Könning T, Maarschalkerweerd R, Endenburg N, et al. **A comparison between fixation**
459 **methods of femoral diaphyseal fractures in cats—a retrospective study.** *J Small*
460 *Anim Pract* 2013; 54: 248-252.

461 14. Witte P, Bush M and Scott H. **Management of feline distal tibial fractures using a**
462 **hybrid external skeletal fixator.** *J Small Anim Pract* 2014; 55: 571-578.

463 15. Palmer RH. **Biological osteosynthesis.** *Vet Clin North Am Small Anim Pract* 1999;
464 29:1171-1185.

465 16. Weese J. **A review of post-operative infections in veterinary orthopaedic surgery.**
466 *Vet Comp Orthop Traumatol* 2008; 21: 99-910.

467 17. Rovesti GL, Bosio A and Marcellin-Little DJ. **Management of 49 antebrachial and crural**
468 **fractures in dogs using circular external fixators.** *J Small Anim Pract* 2007; 48: 194-
469 200.

470 18. Beever LJ, Kulendra ER and Meeson RL. **Short and long-term outcome following**
471 **surgical stabilization of tarsocrural instability in dogs.** *Vet Comp Orthop Traumatol*
472 2016; 29: 142-148.

473 19. Marti J and Miller A. **Delimitation of safe corridors for the insertion of external fixator**
474 **pins in the dog 2: Forelimb.** *J Small Anim Pract* 1994; 35: 78-85.

475 20. Marti J and Miller A. **Delimitation of safe corridors for the insertion of external fixator**
476 **pins in the dog 1: Hindlimb.** *J Small Anim Pract* 1994; 35: 16-23.

477 21. Palmer RH, Hulse DA, Hyman WA, et al. **Principles of bone healing and**
478 **biomechanics of external skeletal fixation.** *Vet Clin North Am Small Anim Pract* 1992;
479 22: 45–68.

22. Lethaby A, Temple J, Santy-Tomlinson J. **Pin site care for preventing infections associated with external bone fixators and pins.** *Cochrane Database Syst Rev* 12, DOI:10.1002/14651858.CD004551.pub3 (2013, accessed 15 January 2017).
23. Eugster S, Schawalder P, Gaschen F, et al. **A prospective study of postoperative surgical site infections in dogs and cats.** *Vet Surg.* 2004; 33: 542-550.
24. Nicholson M, Beal M, Shofer F, et al. **Epidemiologic evaluation of postoperative wound infection in clean-contaminated wounds: a retrospective study of 239 dogs and cats.** *Vet Surg* 2002; 31: 577-581.
25. Krogh HV and Kristensen S. **A study of skin diseases in dogs and cats. II. Microflora of the normal skin of dogs and cats.** *Nord Vet Med* 1976; 28: 459-463.
26. Kirkby KA, Lewis DD, Lafuente MP, et al. **Management of humeral and femoral fractures in dogs and cats with linear-circular hybrid external skeletal fixators.** *J Am Anim Hosp Assoc* 2008; 44: 180-197.
27. Langley-Hobbs SJ, Carmichael S and McCartney W. **Use of external skeletal fixators in the repair of femoral fractures in cats.** *J Small Anim Pract* 1996; 37: 95-101.
28. McCartney W. **Use of the modified acrylic external fixator in 54 dogs and 28 cats.** *The Vet rec* 1998; 143: 330-334.
29. Nielsen C and Pluhar G. **Outcome following surgical repair of achilles tendon rupture and comparison between postoperative tibiotarsal immobilization methods in dogs-28 cases (1997–2004).** *Vet Comp Orthop Traumatol* 2006; 19: 246-249.
30. Pettine KA, Chao EY and Kelly PJ. **Analysis of the external fixator pin-bone interface.** *Clin Orthop Relat Res* 1993; 293: 18-27.
31. Tyagi SK, Aithal HP, Kinjavdekar P, et al. **Comparative Evaluation of In Vitro Mechanical Properties of Different Designs of Epoxy-Pin External Skeletal Fixation Systems.** *Vet Surg* 2014; 43: 355-360.
32. Owen M, Hobbs SL, Moores A, et al. **Mandibular fracture repair in dogs and cats using epoxy resin and acrylic external skeletal fixation.** *Vet Comp Orthop Traumatol* 2004; 17: 189-197.
33. Gilley RS, Beason DP, Snyder DM, et al. **External fixator clamp reuse degrades clamp mechanical performance.** *Vet Surg* 2009; 38: 530-536.

34. Knudsen C, Arthurs G, Hayes G, et al. **Long bone fracture as a complication following external skeletal fixation: 11 cases.** *J Small Anim Pract* 2012; 53: 687-692.
35. McBroom R, Cheal E and Hayes W. **Strength reductions from metastatic cortical defects in long bones.** *J Orthop Res* 1988; 6: 369-378.
36. Egger EL. **Complications of external fixation: a problem-oriented approach.** *Vet Clin North Am Small Anim Pract* 1991; 21: 705-733.
37. Egger EL, Hestand MB, Blass CE, et al. **Effect of Fixation Pin Insertion on the Bone-Pin Interface.** *Vet Surg* 1986; 15: 246-252.
38. Eriksson R, Albrektsson T and Magnusson B. **Assessment of bone viability after heat trauma: a histological, histochemical and vital microscopic study in the rabbit.** *Scand J Plast Reconstr Surg* 1984; 18: 261-268.
39. Bachus KN, Rondina MT and Hutchinson DT. **The effects of drilling force on cortical temperatures and their duration: an in vitro study.** *Med Eng Phys* 2000; 22: 685-691.
40. Clary EM and Roe SC. **In Vitro Biomechanical and Histological Assessment of Pilot Hole Diameter for Positive-Profile External Skeletal Fixation Pins in Canine Tibiae.** *Vet Surg* 1996; 25: 453-462.
41. Darvish K, Shafieian M and Rehman S. **The effect of tip geometry on the mechanical performance of unused and reprocessed orthopaedic drill bits.** *Proceedings of the Institution of Mechanical Engineers, Part H: Journal of Engineering in Medicine* 2009; 223: 625-635.
42. Augustin G, Davila S, Mihoci K, et al. **Thermal osteonecrosis and bone drilling parameters revisited.** *Arch Orthop Trauma Surg* 2008; 128: 71-77.
43. Lewis D, Cross A, Carmichael S, et al. **Recent advances in external skeletal fixation.** *J Small Anim Pract* 2001; 42: 103-112.
44. Aron DN and Dewey CW. **Application and postoperative management of external skeletal fixators.** *Vet Clin North Am Small Anim Pract* 1992; 22: 69-97.
45. Roch S, Störk C, Gemmill T, et al. **Treatment of fractures of the tibial and/or fibular malleoli in 30 cats.** *Vet rec* 2009; 165: 165-70.

Table 1 Additional ESF features

<ul style="list-style-type: none">• Linear ESF Type:I, II or III (including modified types)• Tied-in intra-medullary pin – Yes or no• Transarticular – Yes or no• A-frame – Yes or no• Clamp frame or epoxy-putty (EP)

Table 2 Additional ESF configuration association with fixator associated complications

Frame Feature	Percentage of cases	Incidence of FAC	Type of FAC
Tied-in IM Pin	33% (n=36)	* $P=0.003$	$P=0.352$
Trans-articular ESF	30% (n=33)	$P=0.061$	$P=0.0723$
A-frame ESF	10% (n=11)	$P=0.583$	$P=0.961$
Epoxy putty	14% (n=15)	$P=0.164$	$P=0.636$

FAC-Fixator Associated Complication, ESF-external skeletal fixator, * $P<0.05$

Table 3 Fixator associated complication development at each anatomical region

Region	Complication developed	
	NO	YES
Radius & Ulna	67% (n=6)	33% (n=3)
Tibia	97% (n=33)	3% (n=1)
Femur	50% (n=10)	50% (n=10)
Tarsus	65% (n=13)	35% (n=7)
Humerus	79% (n=11)	21% (n=3)
Mandible & Maxilla	90% (n=9)	10% (n=1)
Manus	75% (n=3)	25% (n=1)
Pes	95% (n=21)	5% (n=1)
Spine	100% (n=1)	0% (n=0)
Stifle	100% (n=6)	0% (n=0)

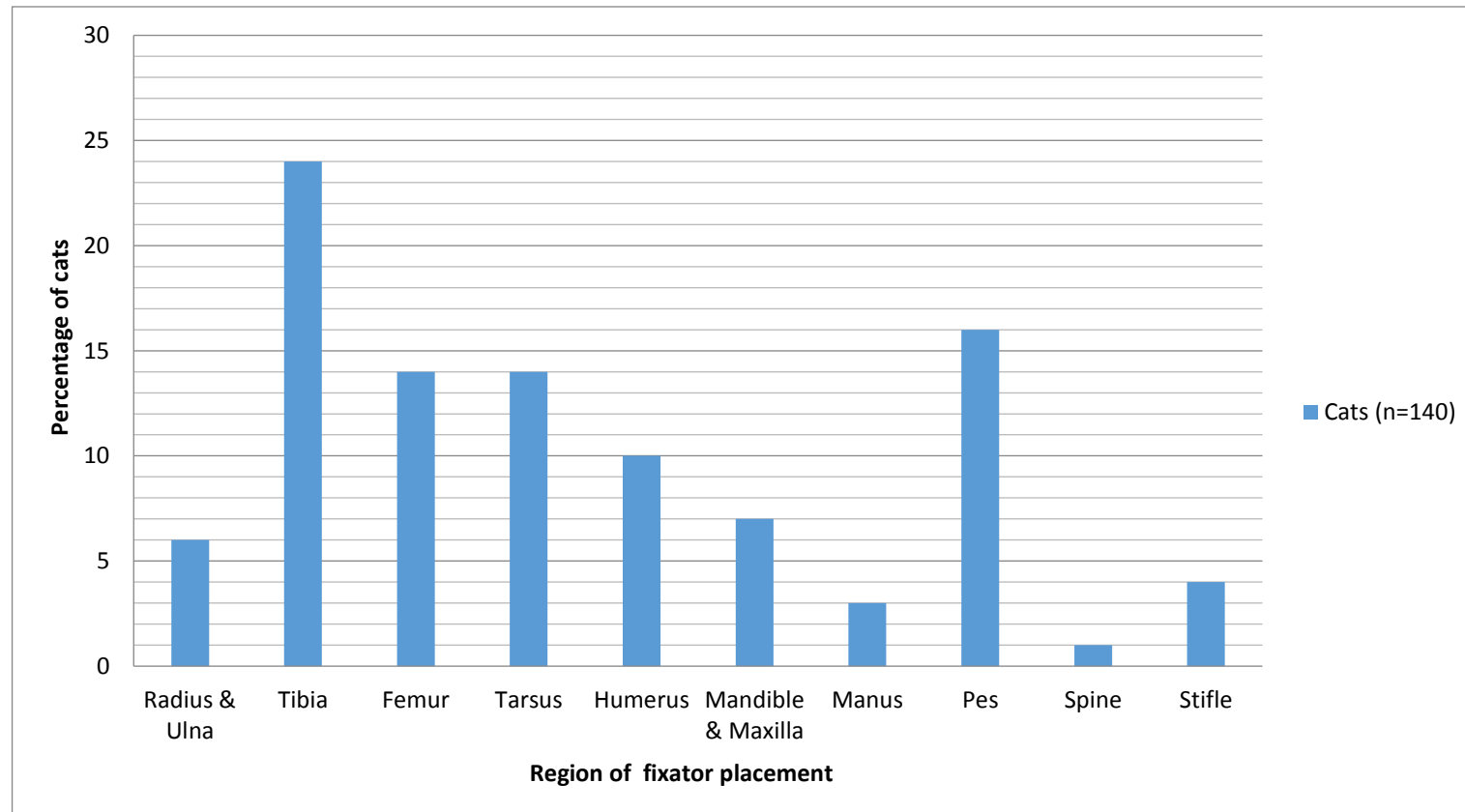


Figure 1 Overall anatomic distribution of fixator placement

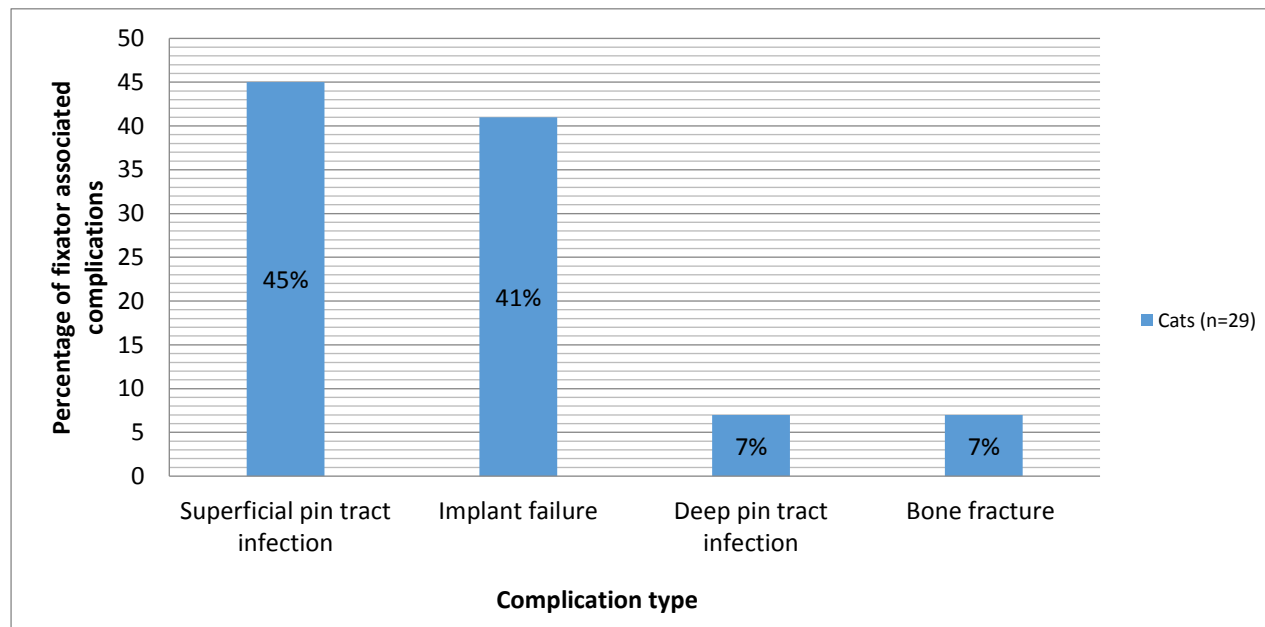


Figure 2 Distribution of fixator associated complications

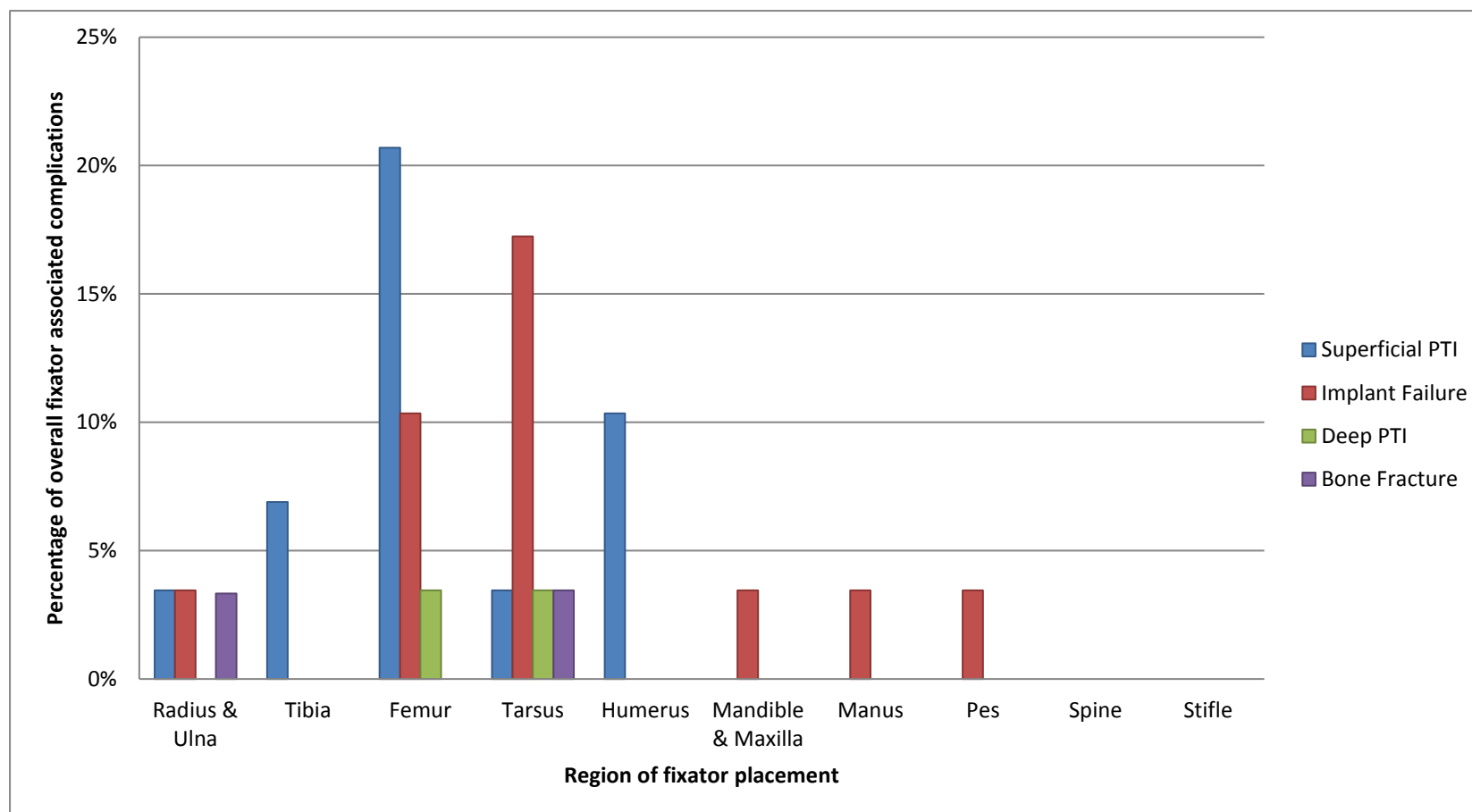


Figure 3 Regional distribution of fixator associated complication types as a percentage of the overall fixator associated complications

PTI- Pin tract infection

Appendix 1 Type of fixator associated complications by anatomical region

	Complication type			
Region	Superficial PTI	Implant Failure	Deep PTI	Bone Fracture
Radius & Ulna	33% (n=1)	33% (n=1)	0% (n=0)	33% (n=1)
Tibia & Fibula	100% (n=2)	0% (n=0)	0% (n=0)	0% (n=0)
Femur	60% (n=6)	30% (n=3)	10% (n=1)	0% (n=0)
Tarsus	13% (n=1)	63% (n=5)	13% (n=1)	13% (n=1)
Humerus	100% (n=3)	0% (n=0)	0% (n=0)	0% (n=0)
Mandible & Maxilla	0% (n=0)	100% (n=1)	0% (n=0)	0% (n=0)
Manus	0% (n=0)	100% (n=1)	0% (n=0)	0% (n=0)
Pes	0% (n=0)	100% (n=1)	0% (n=0)	0% (n=0)
Spine	NC	NC	NC	NC
Stifle	NC	NC	NC	NC

NC- No complications occurred at this region, PTI- Pin tract infection

Appendix 2 Fixator associated complication case details

Complication number	Region	ESF type (number of pins in proximal & distal segment, respectively)	Complication	Complication details	Case management
1	Tibia	Type 2 (4,4)	SPTI	PTI of proximal pin	Fixator removed at planned recheck as fracture healed
2	Humerus	Type 3 & IM pin	SPTI	PTI of distal pin	Fixator removed at planned recheck as fracture healed
3	Femur	Type 1a & IM pin	SPTI	PTI of all distal pins	Limb amputation due to pin loosening & non-union due to persistent PTI
4	Tarsus	Type 1a (3,3)	SPTI	PTI of distal pin	Resolved with antimicrobial administration
5	Femur	Type 1a & IM pin	SPTI	PTI of distal pin	Managed with antimicrobial administration until planned frame removal
6	Femur	Type 1a & IM pin (3,3)	SPTI	PTI of multiple pins	Limb amputation due to surgical wound complications
7	Femur	Type 1a & IM pin (2,2)	SPTI	PTI of proximal pin	Pin removal & antimicrobial treatment
8	Femur	Type 1a & IM pin (3,3)	SPTI	PTI- exact pins not noted	Resolved with antimicrobial administration
9	Humerus	n/a	SPTI	PTI of distal pin	Pin removal
10	Radius & Ulna	Modified Type 2 (3,2)	SPTI	PTI of proximal pin	Pin removal & antimicrobial treatment
11	Humerus	Modified Type 1a & IM pin (3,3)	SPTI	PTI of multiple pins- exact pins not noted	Fixator removed at planned recheck fracture healed
12	Tibia	Modified Type II (4,3)	SPTI	PTI of proximal pin	Pin removed following failed antimicrobial administration
13	Femur	Type 1a & IM pin	SPTI	PTI of distal pin	Resolved with antimicrobial administration
14	Femur	Type 1a & IM pin	Implant failure	Traumatic proximal pin removal & IM pin clamp failure with IM pin migration	Fixator removed as fracture healed
15	Tarsus	n/a	Implant failure	Broken distal pin	Pin replaced
16	Tarsus	n/a	Implant failure	Broken distal pin	Fixator removed as tarsus stable
17	Tarsus	n/a	Implant failure	Broken distal 3 pins	Pins replaced & 2 additional pins added
18	Femur	Type 1a & IM pin (2,2)	Implant failure	Loose proximal 2 pins	Loose pins removed
19	Manus	Modified Type 2 (2,3)	Implant failure	Bent 2nd to most proximal pin	Continued instability- arthrodesis
20	Femur	Type 1a & IM pin (3,3)	Implant failure	Loose proximal pin	Pin removed
21	Tarsus	n/a	Implant failure	Broken distal pin	ESF removal & external coaptation
22	Tarsus	Type 1a (3,3)	Implant failure	Broken distal 3 pins	ESF removal & external coaptation
23	Radius & Ulna	Type 1a & IM pin (3,3)	Implant failure	Loose proximal & distal pins	ESF removed as fracture stable
24	Mandible & maxilla	Free-form	Implant failure	Loose- all pins	ESF removed- conservatively managed unstable fracture
25	Pes	Type 1b (4,4)	Implant failure	Broken 2nd to most proximal pin	Pin removed, tip left in bone as unable to remove
26	Tarsus	n/a	DPTI	Osteomyelitis around calcaneal pin	Frame removed & antimicrobial administration
27	Femur	Type 1a & IM pin (3,3)	DPTI	Osteomyelitis around distal pin	Pin removed & antimicrobial administration
28	Tarsus	n/a	Bone fracture	Calcaneal fracture at removed pin site	Limb amputation
29	Radius & Ulna	Type 1a (3, 3)	Bone fracture	Fracture through proximal pin tract	Pin removed & revision of ESF to Type 1b

n/a- data not available, IM- intramedullary, SPTI- Superficial pin tract infection, Deep- Deep pin tract infection, PTI- Pin tract infection