

This is the peer-reviewed, manuscript version of the following article:

Mehl, N. S., Srisuwatanasagul, S., Swangchan-Uthai, T., Sirivaidyapong, S. and Khalid, M. 'GnRH-agonist implants suppress reproductive function and affects ovarian LHR and FSHR expression in prepubertal female cats', *Theriogenology*.

The final version is available online: <http://dx.doi.org/10.1016/j.theriogenology.2016.09.003>.

© 2016. This manuscript version is made available under the CC-BY-NC-ND 4.0 license <http://creativecommons.org/licenses/by-nc-nd/4.0/>.

The full details of the published version of the article are as follows:

TITLE: GnRH-agonist implants suppress reproductive function and affects ovarian LHR and FSHR expression in prepubertal female cats

AUTHORS: N.S. Mehl, M. Khalid, S. Srisuwatanasagul, T. Swangchan-uthai, S. Sirivaidyapong

JOURNAL TITLE: Theriogenology

PUBLISHER: Elsevier

PUBLICATION DATE: 9 September 2016 (online)

DOI: 10.1016/j.theriogenology.2016.09.003

**GnRH-agonist implants suppress reproductive function and affects ovarian LHR and FSHR
expression in prepubertal female cats**

N.S. Mehl^a, M. Khalid^{b*}, S. Srisuwatanasagul^c, T. Swangchan-uthai^a, S. Sirivaidyapong^a

^a *Department of Obstetrics, Gynaecology and Reproduction, Faculty of Veterinary Science, Chulalongkorn University, Bangkok, Thailand.*

^b *Department of Production and Population Health, The Royal Veterinary College, Hertfordshire, The United Kingdom.*

^c *Department of Anatomy, Faculty of Veterinary Science, Chulalongkorn University, Bangkok, Thailand.*

*Corresponding author: M. Khalid (mkhalid@rvc.ac.uk)

Abstract

Effect of a GnRH-agonist (deslorelin) was studied on reproductive function and ovarian luteinizing hormone receptor (LHR) and follicle stimulating hormone receptor (FSHR) expression in prepubertal female cats that were either implanted with 4.7-mg deslorelin (implanted: n = 6) or not (controls: n = 18) or ovariectomized at prepubertal age (prepubertal OVH: n = 6). Body weights, fecal estradiol, and sexual behavior of implanted and control cats were monitored for 48 weeks followed by collection of ovaries and uteri. Ovaries and uteri were collected from control cats at follicular, luteal, and inactive stage (n = 6/group) and from prepubertal OVH cats at prepubertal age. Ovaries and uteri were analyzed for anatomical/histological characteristics. Ovaries were also analyzed for LHR and FSHR expression. Statistical analysis showed higher ($P \leq 0.05$) body weight in control than implanted cats only during 22nd to 26th weeks of the study. Estrus was observed in control cats only. Deslorelin reduced ($P \leq 0.05$) ovarian weight and number of antral follicles but did not affect endometrial thickness and gland diameter. However, myometrial thickness of implanted cats was significantly lower than control cats at follicular and luteal stage. Ovarian LHR mRNA expression was lower ($P \leq 0.05$) in implanted cats than control cats at follicular stage. FSHR mRNA and LHR protein expression did not differ among the three groups. FSHR protein expression was lower ($P \leq 0.05$) in prepubertal OVH cats and was not affected by deslorelin. In conclusion, deslorelin suppresses reproductive function in prepubertal female cats for at least 48 weeks possibly through a change in the ovarian mRNA expression of LHR.

Key Words: GnRH-agonist, Pre-pubertal cat, LHR, FSHR, Reproductive behaviour

Introduction

Overpopulation of cats has become a serious problem in big cities across the world. Surgical contraception is one of the first choices as a tool for population control. However, it is an expensive and invasive method, which requires anesthesia and proper postsurgical care [1]. Previous studies have suggested that nonsurgical contraception could be an alternative method of population control especially in those animals which are at surgical and/or anesthesiological risks. In this regard, GnRH agonists have been used to suppress the pituitary gland and/or the release of gonadotropins. Nonsurgical contraception in the female cat is thought to be potentially a challenge, considering the unique pattern of estrous cycle in this species [2]. However, GnRH-agonists can be used for the purpose of contraception in mammals at a wide range of age and at different stages of estrous cycles [1], [3], [4], [5], [6] and [7]. Although the use of GnRH-agonist for the control of cat population may still be too expensive, cat breeders might consider it as an option to control estrus in breeding queens.

Previous studies in female cats have shown the ability of GnRH-agonists to suppress their reproductive tract and/or function, but an upregulation/flare-up effect was reported during the early stages of the treatment that resulted into exhibition of estrus symptoms which is undesirable [1] and [3]. However, such an upregulation effect was not observed with the implantation of GnRH-agonist in the prepubertal female dogs [4]. Although the absence of upregulation effect in these dogs has been attributed to their prepubertal status, there are no reports regarding the use of GnRH-agonist treatment in prepubertal female cats. Recent studies on postnatal female cats using 1.6-mg GnRH-agonist (deslorelin) found that puberty in the treated cats was delayed for 16 months and the number of primordial, primary, secondary, and antral follicles in the treated cats were significantly lower than the controls [7] and [8]. However, there is not enough information regarding how long GnRH-agonist treatment could delay puberty in prepubertal female cats. Moreover, the underlying mechanism by which GnRH-agonist suppresses the reproductive system is not known. The objectives of this study were to investigate (1) the effect of GnRH-agonist implantation on the reproductive function, and the structures and characteristics of uteri and ovaries in prepubertal female cats, (2) a possible link of these effects with the ovarian luteinizing hormone receptor (LHR) and follicle stimulating hormone receptor (FSHR) expression, and (3) to see how closely GnRH-agonist implantation maintains the prepubertal status of these parameters.

2. Materials and methods

2.1 Experiment design and animals

Three groups of 3-month-old prepubertal female cats were used in this study. Cats in group 1 (implanted; n = 6) were implanted with 4.7-mg deslorelin GnRH-agonist (Suprelorin 4.7 mg, Virbac Animal Health, France) in the interscapular area, cats in groups 2 (control; n = 18) and 3 (prepubertal ovariectomized [OVH]; n = 6) were left without implants. To collect the ovaries and uteri, cats in group 3 (prepubertal OVH) were ovariectomized while they were still 3 month old, i.e., at their prepubertal status, whereas the implanted and control cats were housed in separate cages in an open air room with natural daylight in the Department of Obstetrics, Gynecology and Reproduction, Faculty of Veterinary Science, Chulalongkorn University, Thailand. During the study period of 48 weeks, they were fed with a commercial diet twice daily with water always available *ad libitum*. The study was performed under the license of Chulalongkorn University Laboratory Animal Center number 13310056.

Implanted animals were monitored for any potential adverse effects like tissue reaction and/or infection at the site of implantation for a period of 1 week. Any rashes, edema, erythema of the implantation area, and other possible lesions were recorded. Body temperature was measured daily for 1 week after the implantation to monitor any infection.

Body weight of all the implanted and control cats was also recorded fortnightly throughout the experimental period. Estrus behavior (rubbing and rolling, lordosis, tail deflection, treading of the hind limbs, vocalization, and the acceptance of mating with intact males) of all the cats was monitored as described previously [2] and [3] throughout the experimental period of 48 weeks. Estrus detection was confirmed by vaginal cytological pattern consisting of a clear background with more than 80% of superficial cells [9] and/or serum estradiol concentrations more than 20 pg/mL [2] and [6] or 42.2 to 157.8 pmol/L [10]. Estrous behavior was taken as an indication of ovarian follicular activity. Four cats from each of the groups 1 and 2 were housed singly, and their feces were collected at two-day intervals for a period of 4 weeks (28th–32nd week of the study period). Fecal samples were analyzed for estradiol concentrations, which were used to confirm the ovarian activity/cyclicality. At the end of study period, all implanted and control cats were ovariectomized to collect their ovaries and uteri. Control cats were ovariectomized when they

were at their follicular (n = 6), luteal (n = 6), and inactive (n = 6) stage of the estrous cycle. Blood samples were collected only once for serum estradiol and progesterone just before ovariohysterectomy at the end of the study period. Stage of the estrous cycle was determined in these cats mainly by their estrous behavior, vaginal cytology, and the structures on the ovary but was confirmed by serum estradiol and progesterone concentrations. Cats with serum estradiol concentrations of more than 20 pg/mL were considered to be at their follicular stage of the cycle, and cats with serum progesterone concentrations of 1.5 to 20 ng/mL were considered to be at their luteal stage of the estrous cycle. Cats with serum estradiol and progesterone concentrations of less than 20 pg/mL and less than 1.5 ng/mL, respectively, were considered to be either in interestrus or anestrus, which for the purpose of this article was defined as inactive stage of the estrous cycle [2]. Structures present on the ovaries (follicles and corpora lutea) obtained after ovariohysterectomy were also used to confirm the stage of the estrous cycle.

2.2 Morphology of female reproductive organs

After ovariohysterectomy, ovarian weight, structures present on the ovary, and their morphological appearance were recorded. The ovaries and uteri were divided into two parts; one part was fixed in 4% (wt/vol) paraformaldehyde for 48 to 72 hours and then stored in 70% ethanol until processing, whereas the other part was snap frozen with liquid nitrogen and stored at -80°C until RNA extraction. Fixed uterine and ovarian tissues were embedded in paraffin wax and cut into 5- μm sections by a rotor microtome, applied to gelatin-coated slides, and left to dry in an incubator at 37°C , then stained with hematoxylin and eosin staining.

Histological investigation of the uterus was performed under light microscope, five sections per uterine horn and five fields per section at $\times 40$ magnification were captured for the measurement of the thickness of endometrium and myometrium, and five fields per section at $\times 200$ magnification for the measurement of the uterine gland diameter. Different types of follicles (primordial, primary, secondary, and antral) and corpora lutea were counted from five sections per ovary and five fields per section under light microscope at $\times 100$ magnification. The number of different types of follicles was recorded per mm^2 of the ovarian cortex area.

2.3 Hormonal measurement in fecal and serum samples

Blood samples collected just before ovariohysterectomy at the end of the study period were sent to Bangkok RIA group clinical laboratory to measure serum estradiol and progesterone by radio immunoassay (RIA) and CMIA (Chemiluminescent Microparticle Immunoassay), using “ARCHITECT Progesterone” and “ARCHITECT Estradiol” kits (Abbot Ireland, Longford, Ireland), respectively as described earlier [10] and [11].

After collection, fecal samples were stored in a freezer at -20°C . Fecal estradiol concentrations were measured by the Khao Kheow open zoo laboratory in Bangkok, Thailand, using enzyme immune assay as described previously [12]. Fecal estradiol was used to analyze the ovarian function of both implanted and control cats.

2.4 Luteinizing hormone receptor and FSHR expression

Ovarian sections were deparaffinized with Xylene (J.T. Baker, PA, USA) and rehydrated through ascending concentrations of alcohol (50%, 70%, 90%, 99.7%, and 100%). The immune-histochemical staining was performed as described previously [13]. Briefly, to de-mask epitopes, tissue sections/slides were placed in boiling 0.01-M sodium citrate solution, then, cooled down to room temperature for 35 minutes. Slides were then rinsed three times in phosphate buffered saline (PBS). Endogenous peroxidase activity was inactivated by immersing slides in 1% (v/v) hydrogen peroxide in methanol for 10 minutes, then rinsed again three times in PBS. Sections were subsequently blocked for 60 minutes in a humidified chamber using a blocking solution, comprising 1% normal horse serum (Vector Laboratories, CA, USA) diluted in PBS and 20% (v/v) avidin solution (Avidin/Biotin blocking kit; Vector Laboratories, CA, USA). After washing three times in PBS, the slides/sections were incubated overnight at 4°C in a humidified chamber with LHR (H-50) polyclonal antibody (Santa Cruz biotechnology, Inc., USA) at a dilution of 1:50 or FSHR (N-20) polyclonal antibody (Santa Cruz biotechnology, Inc., USA) at a dilution of 1:50. The primary antibodies were diluted in PBS to which 20% (v/v) biotin solution (Avidin/Biotin blocking kit; Vector Laboratories, CA, USA) was added. The negative control sections were treated in the same manner with PBS and biotin mixture in the absence of primary antibodies. After incubation, sections were washed with PBS three times (3×10 minutes). Then, secondary antibody (Biotinylated anti-mouse anti-rabbit IgG, Vector Laboratories, Inc., USA for LHR localization and Biotinylated anti-goat IgG, Vector Laboratories, Inc., USA for FSHR localization) were

applied to the sections and incubated for 30 minutes. Sections were washed again three times in PBS and incubated at room temperature with 20% (v/v) avidin-biotin complex solution (VECTASTAIN Vector Laboratories, Inc., USA) for 30 minutes. Tissue sections were then incubated with DAB peroxidase substrate (Vector Laboratories, Inc., USA) until color development. All slides were counterstained with Mayer's hematoxylin. Brown staining was observed on tissue sections with positive staining for both LHR and FSHR and no staining was observed for negative controls for either receptor.

At least 2 sections for both positive antibody staining and negative controls were examined from each animal.

2.5 Quantification of the immunohistochemistry staining

The pattern and intensity of protein staining for LHR and FSHR were determined semi-quantitatively using a histochemical score method. Ten fields per section of each tissue sample were assessed blindly by one investigator using a light microscope at $\times 200$ magnification. The intensity of staining was classified by one assessor on a scale of 1 to 3, where 1 = weak staining, 2 = moderate staining, and 3 = strong staining [13] and [14]. Percentage of cells stained at each level of staining (weak, moderate, or strong) in a certain area of the section was assessed using the Image-pro plus 7.0 program (Media Cybernetics, Inc., MD, USA). An expression index was calculated for each tissue sample based on the percentage of positively stained cells and the intensity of staining using the following formula:

$$\text{EI} = \% \text{total stained cells} \times [(1 \times \% \text{weak}) + (2 \times \% \text{medium}) + (3 \times \% \text{strong})] / 100$$

A mean expression index was calculated to represent the protein expression of LHR or FSHR in each ovarian tissue section from an individual animal [14], [15] and [16].

Quantitative real-time polymerase chain reaction (qPCR) for the LHR and FSHR mRNA in the ovarian tissue.

2.6 Extraction and reverse transcription of mRNA

Total RNA was extracted from the whole frozen ovaries after grinding with a homogenizer (at 10,000–20,000 RPM for 10–20 seconds), using the RNeasy mini kit (QIAGEN, Alameda, CA, USA) following the manufacturer's instructions. Concentration and purity of the extracted RNA were assessed by

spectrophotometer (ND-2000, NanoDrop, Wilmington, DE, USA). The RNA samples were stored at $-80\text{ }^{\circ}\text{C}$ before qPCR analysis.

2.7 *Quantitative real-time PCR*

Conventional PCR was performed for the preparation of standards and analyzing the optimal melting and annealing temperature for each gene (LHR, FSHR, and glyceraldehyde-phosphate-dehydrogenase (GAPDH) as reference gene). The thermal cycler (G-Storm Thermal Cycler, Somerset, United Kingdom) was set at the condition of 15 minutes at $95\text{ }^{\circ}\text{C}$ to activate Taq DNA polymerase, 30 cycles of 30 seconds at $94\text{ }^{\circ}\text{C}$ for denaturing, 90 seconds at $57\text{ }^{\circ}\text{C}$ for annealing, 30 seconds at $72\text{ }^{\circ}\text{C}$ for extension, and 10 minutes at $72\text{ }^{\circ}\text{C}$ for the final extension. Previously published [17] and [18] forward and reverse primers for feline LHR and FSHR and GAPDH were used as shown in Table 1. Each reaction was contained with the Qiagen Multiplex PCR Kit (QIAGEN, Alameda, CA, USA). Amplified products were run on 1.2% agarose gel (Sigma-Aldrich, St. Louis, MO, USA) and visualized under UV gel document and analysis (Syngene Cambridge, United Kingdom) to confirm the presence of single products without dimers. Purification of the amplified products was performed with the QIAquick PCR purification kit (QIAGEN, Alameda, CA, USA). Purified products were quantified by spectrophotometer (ND-2000, NanoDrop, Wilmington, DE, USA) and used to prepare standards for qPCR.

2.7 *Statistical analysis*

Real-time qPCR amplification was performed using the CFX96 Thermal cycler (Bio-Rad Laboratories, Inc., Hercules, CA, USA) with the Bio-Rad CFX manager 3.1 software (Bio-Rad Laboratories, Inc.). Each reaction (20 μL) was contained with 10 μL of 2 \times qPCR BIO SyGreen Mix Lo-ROX (PCR Biosystems Ltd., London, United Kingdom), 0.8 μL of each forward and reverse primer, 5 μL of a DNA template (5 ng/ μL), and RNase free water was added up to make up to the volume of 20 μL . RNase free water was added instead of cDNA template in the Non-template control. Thermocycler was set for 38 cycles of denaturing at $95\text{ }^{\circ}\text{C}$ for 5 seconds following with the optimum annealing temperature of $61.4\text{ }^{\circ}\text{C}$, $61.4\text{ }^{\circ}\text{C}$, and $61.4\text{ }^{\circ}\text{C}$ for 30 seconds and melting temperature of $82\text{ }^{\circ}\text{C}$, $80\text{ }^{\circ}\text{C}$, and $76\text{ }^{\circ}\text{C}$ for 10 seconds for GAPDH, FSHR, and LHR, respectively with a gradient from $50\text{ }^{\circ}\text{C}$ to $95\text{ }^{\circ}\text{C}$ to investigate the gene expression and recorded as femtogram per

microgram (fg/ μ g) of total RNA. Standards of each gene were used to determine the absolute value of mRNA in each reaction.

2.8 Statistical analysis

The statistical analysis was performed using SAS (SAS Institute INC., 2002). Body weight was compared between implanted and control cats using independent t test. Simple presence of estrogen peaks in a cat was taken an indication of the ovarian follicular activity.

The ovarian weight, endometrial gland diameter, thickness of endometrium and myometrium, number of primordial, primary, secondary, and antral follicles, and mRNA and protein expression of LHR and FSHR were tested for normality using univariate procedure and were compared among the three groups. i.e., implanted, control cats at follicular, luteal and anestrus stages of estrous cycle and prepubertal OVH cats using general linear model procedure. Least-squared means were obtained for each group and compared by using least significant difference test. The number of CL was compared among groups using Wilcoxon rank sum test. The differences in the mean values were considered significant at $P \leq 0.05$.

3. Results

Following GnRH implantation, no adverse effects or infection were observed in any of the implanted cats. Control cats had significantly higher ($P \leq 0.05$) body weight compared with the implanted cats but only during the 22nd to 26th weeks of the study period. However, for rest of the treatment period, no difference was observed in the body weight of cats between these two groups (Fig. 1).

No estrus was observed in the implanted cats throughout the experimental period, whereas estrus was observed in all the control cats during the experimental period. Among control cats, two cats started to show signs of estrus from the 10th week after the start of the treatment, whereas rest of the other control cats showed signs of estrus from the 12th week after the start of the study in June 2012.

Figure 2 shows the fecal estradiol concentrations from the 28th to 32nd week of the treatment period in implanted and control cats. Although control cats showed estradiol peaks, no estradiol peak was observed in implanted cats.

The ovarian weight of the implanted cats was significantly lower ($P \leq 0.05$) than that of the prepubertal OVH and the control cats at all stages of their estrus cycle. Significantly lower ($P \leq 0.05$) ovarian weight was recorded in the prepubertal OVH cats compared with the control cats at their luteal and estrus stage of the estrous cycle. However, no difference was observed in the ovarian weight between prepubertal OVH cats and control cats at the inactive stage of their estrous cycle (Table 2). The number of primordial follicles did not differ among the different groups. Number of primary follicles was significantly higher ($P \leq 0.05$) in implanted cats compared with control cats at all the stages of the estrous cycle. However, it did not differ from that in prepubertal OVH cats (Table 2). The number of secondary follicles did not differ among the three groups of cats. The number of antral follicles was, however, significantly lower ($P \leq 0.05$) in implanted cats compared with other groups except the luteal stage control cats (Table 2). The number of CL in the control cats at luteal stage was significantly higher ($P \leq 0.05$) than that in the implanted, prepubertal OVH, and the control cats at the follicular and inactive stages of the estrous cycle (Table 2).

Protein expression of LHR was observed in the cytoplasm of theca cells, interstitium of the ovarian tissue and granulosa cells of large antral follicles only, whereas the FSHR protein expression was found in the granulosa cells of antral follicles only. No difference was observed in the protein expression of the LHR among different experimental groups of cats studied (Fig. 4A). Prepubertal OVH cats had significantly lower ($P \leq 0.05$) protein expression of FSHR compared to the implanted and the control cats at the luteal stage of the estrous cycle. However, there was no difference in the protein expression of FSHR among the implanted and control cats at the follicular and inactive stages of the estrous cycle (Fig. 4A).

Ovarian LHR mRNA expression was significantly lower ($P \leq 0.05$) in the implanted cats than the control cats at the follicular stage of the estrous cycle. However, there was no difference in the mRNA expression of LHR among the implanted, prepubertal OVH, and the control cats at their luteal or inactive stages of the estrous cycle (Fig. 4B). Moreover, no difference was observed in the mRNA expression of FSHR between the implanted, prepubertal OVH, and the control cats (Fig. 4B).

4. Discussion

This study was designed to investigate the effects of the treatment of prepubertal female (3-months-old) cats with 4.7-mg GnRH-agonist (deslorelin) on their reproductive function and the ovarian expression of

LHR and FSHR. Moreover, to see how closely GnRH-agonist implantation maintains the prepubertal status of the parameters studied, tissues were also obtained and analyzed from the prepubertal animals.

The prepubertal female cats at the age of 3 months tolerated the deslorelin implantation very well without the need of any local or general anesthesia; no adverse effects were observed in the implanted animals. This supports the previous studies in which tolerance of deslorelin implantation has been reported in prepubertal cats [7] and [19]. General health of the implanted and the control animals was also monitored by recording the weekly body weights of the cats throughout the study period. The body weight of implanted and control cats did not differ during most of the study period of 48 weeks except during the 20th to the 26th week when body weight of the implanted cats was found to be significantly lower than that of the controls. As this difference in the body weight was observed only 22 weeks after the treatment and only for a brief period of time, it seems highly unlikely that it might have been due to deslorelin implantation, rather it might have resulted from the individual variation among the cats used in the study.

Fecal estradiol in felid species is considered to be an indication of ovarian activity [20]. The presence of fecal estradiol peaks in the control cats and the absence of such peaks in the implanted cats simply prove that deslorelin inhibits the ovarian activity in prepubertal cats. Moreover, unlike the previous studies [20], we did not notice any upregulation or flare-up effect because of the deslorelin implantation. In addition to fecal estradiol, ovarian activity was also monitored in these animals at the end of the study period by recording ovarian weight and number of ovarian structures including follicles and CLs. No differences were observed in the number of primordial follicles between the experimental groups, which may indicate that all the experimental groups had the same potential of follicle development. In the implanted group, however, follicle growth seemed to be arrested at the primary follicle stage with little growth to the secondary stage and almost negligible growth to the antral stage of follicle development. This was also evidenced by the significantly lower ovarian weight recorded in this group. In the control cats, follicle growth basically reflected the stage of the estrous cycle. Understandably although, the highest number of antral follicles was observed in the prepubertal OVH cats that may be due to an absence of ovulation in this group. As expected, the number of CLs was the highest in the luteal group; however, CLs were also found in follicular phase queens but in only few instances. However, no evidence of ovulation or CL was found in the prepubertal OVH or implanted animals. The CLs in the control cats which were never exposed to male cats/copulation may indicate that

spontaneous ovulation may have occurred in our experimental animals as reported previously [21] and [22]. Gonadotropins (LH and FSH) play an important role to control the overall activity of female reproductive tract including follicle growth [23]. Gonadotropins act by the binding to their receptors on the ovarian cells, so a change in either the gonadotropins' concentrations or the number of their receptors may modulate the effects of the gonadotropins on follicular development, ovulation and/or luteinization. Luteinizing hormone receptor in the interstitium is also found to be responsible in modulating the production of steroid hormones, which are necessary for the functions of the reproductive tract [24].

The mRNA expression of LHR in the implanted cats was significantly lower than that in the control animals at their follicular phase while there were no differences in the LHR mRNA expression between the implanted cats and the control animals during the luteal and inactive stages. This may suggest that receptors for LH are activated in the control cats during their follicular stage of the estrous cycle in concomitantly with an increase in the LH release itself [22]. It is worth noting that mRNA expression of LHR was not different during the other stages (luteal and inactive) of the estrous cycle when LH release remains basal with mild fluctuations [22]. Although LH release was not monitored in this study, it is well documented that GnRH administration does cause suppression of LH in almost all the species including dogs [25] and [26]. It is, therefore, a possibility that the decreased levels of estradiol observed in the implanted cats may be the result of suppressed gonadotropins in these animals [3]. In this study, LH suppression by deslorelin implantation seems to be quite effective and consistent, and might have resulted in the lower expression of LHR mRNA observed in the implanted cats. However, the observed lack of difference in the LHR mRNA expression between the prepubertal OVH and control cats suggests that LHR synthesis does occur during the prepubertal period but it remains suppressed in the implanted cats. In spite of the differences observed in deslorelin-treated cats regarding the LHR mRNA, no difference was observed in the protein expression of the LHR between the implanted and the control cats, even at the follicular stage of their estrous cycle. This suggests that LH plays a role in the translation of LHR mRNA into LHR protein. The action of LH, however, normally occurs after its release induced by copulation. However, the control cats in this study were not exposed to copulation yet some of these cats ovulated and were in luteal phase as evidenced by progesterone concentrations. As none of these queens could have possibly been bred, there is a possibility that they might have experienced a spontaneous LH release and ovulation. Spontaneous ovulation in cats [22] and [27] especially in laboratory-

maintained animals has been reported to depend on individual conditions and housing of cats [21]. However, in our case, it is difficult to identify the housing conditions that could have caused spontaneous ovulation as our study was not designed for this purpose, unlike other studies [27] and [28]. Interestingly, we did not record any spontaneous ovulation in the implanted cats. Considering the possible roles of both the LHR and the LH itself in the observed suppression of estradiol production in the implanted cats, one may conclude that LH itself might have played a major role rather than any contribution by a change in the LHR expression.

FSHR is normally detected in the granulosa cells of antral follicles and is considered to play a role in follicular development. The fact that the number of antral follicles was significantly higher in the prepubertal OVH than the implanted cats in spite of significantly lower expression of FSHR protein in the prepubertal OVH females, simply points out the fact that the ligand itself plays the critical role required for the follicle development rather than changes in its receptor expression. However, a lack of difference in the FSH mRNA between these two groups suggests that translation was compromised in the prepubertal animals.

The endometrial glands are responsible for uterine secretions that nourish the embryos during early pregnancy [29], and they are also active during certain stages of the estrous cycle. The significantly lower endometrial gland diameter in the prepubertal OVH cats suggests their lower activity in these animals compared with the control cats during their follicular and luteal phase of the estrous cycle. Although the endometrial gland diameter of implanted cats was not lower than that of the control cats, the epithelium of the endometrial glands of the implanted cats consisted of a single layer of cuboidal cells while that of control cats during their luteal and follicular stages of the estrous cycle had a single layer columnar epithelial cells with greater height and abundant secretion in the glands. This simply suggests a negative effect of deslorelin on the structure/morphology and function/activity of the endometrial glands. No differences were observed in endometrial thickness between implanted and control cats during any stage of the estrous cycle, but myometrial thickness of the implanted cats was significantly lower than that of control cats during their luteal and follicular phases of the estrous cycle. Moreover, myometrial thickness of prepubertal OVH cats was also significantly lower than that of the control cats during their follicular and luteal phases of the estrous cycle. The lower thickness of myometrium in implanted cats may be a result of suppressed estrogen concentrations in these animals as hyperplasia of the myometrial fiber filaments is known to be induced by estrogens [30].

Nevertheless, results of this study suggest that the endometrial glands and the myometrium of the implanted cats does not seem to be fully functional compared to the control cats with active ovaries. These data therefore support the notion that both the myometrium and the endometrial glands are not quite functional due to the suppression of ovarian function induced by the GnRH-agonist implantation.

In conclusion, the results of this study have demonstrated that in prepubertal queens, a subcutaneous implant of 4.7-mg deslorelin suppresses ovarian weight, follicle development, estrogen production, and myometrial thickness for a period of at least 48 weeks without any adverse effects. Associated to the suppression of estrogen production and other ovarian functions, sexual behavior in deslorelin-implanted cats was also suppressed. And this suppression of reproductive function due to deslorelin implantation seems to have partly been achieved through changes in the ovarian mRNA expression of LHR. These studies could be extended to investigate both the actual duration of suppression of reproductive function beyond the 48 weeks and other possible mechanism(s) by which GnRH-agonist treatment could act apart from the ovarian LHR and FSHR expression.

5. Acknowledgement

This study was supported by the Royal Golden Jubilee Ph.D. program (PHD/0161/2553), the 90th Anniversary of Chulalongkorn University (Ratchadaphiseksomphot Endowment Fund) and the Research Unit of Obstetric and Reproduction in animals of Chulalongkorn University, Bangkok, Thailand. The authors acknowledge Dr. Zhangrui Cheng from the Royal Veterinary College, University of London, for laboratory assistance and Dr. Em-on Olanratmanee from the Faculty of Veterinary Medicine, Rajamangala University of Technology Tawan-Ok, Thailand for help in the statistical analysis of the data.

References

- [1] Goericke-Pesch S, Georgiev P, Atanasov A, Albouy M, Navarro C, Wehrend A. Treatment of queens in estrus and after estrus with a GnRH-agonist implant containing 4.7 mg deslorelin; hormonal response, duration of efficacy, and reversibility. *Theriogenology* 2013;79:640–6.
- [2] Johnston SD, Root Kustritz MV, Olson PNS. The feline estrous cycle. *Canine and feline theriogenology*. First edition. Philadelphia, PA 19106: Saunders Elsevier; 2001. p. 396–405.
- [3] Toydemir TS, Kilicarslan MR, Olgac V. Effects of the GnRH analogue deslorelin implants on reproduction in female domestic cats. *Theriogenology* 2012;77:662–74.
- [4] Trigg TE, Doyle AG, Walsh JD, Swangchan-Uthai T. A review of advances in the use of the GnRH agonist deslorelin in control of reproduction. *Theriogenology* 2006;66:1507–12.

- [5] Pelican KM, Wildt DE, Howard JG. GnRH agonist Lupron (leuprolide acetate) pre-treatments prevent ovulation in response to gonadotropin stimulation in the clouded leopard (*Neofelis nebulosa*). *Theriogenology* 2006;66:1768–77.
- [6] Munson L, Bauman JE, Asa CS, Jochle W, Trigg TE. Efficacy of the GnRH analogue deslorelin for suppression of oestrous cycles in cats. *J Reprod Fertil Suppl* 2001;57:269–73.
- [7] Carranza A, Faya M, Merlo ML, Batista P, Gobello C. Effect of GnRH analogs in postnatal domestic cats. *Theriogenology* 2014; 82:138–43.
- [8] Carranza A, Faya M, Merlo ML, Batista P, Gobello C. Histologic effect of a postnatal slow-release GnRH agonist on feline gonads. *Theriogenology* 2015;83:1368–72.
- [9] Faya M, Carranza A, Miotti R, Ponchon T, Furlan P, Gobello C. Fecal estradiol-17beta and testosterone in prepubertal domestic cats. *Theriogenology* 2013;80:584–6.
- [10] Axner E, Gustavsson T, Strom Holst B. Estradiol measurement after GnRH-stimulation as a method to diagnose the presence of ovaries in the female domestic cat. *Theriogenology* 2008;70:186–91.
- [11] Goodrowe KL, Howard JG, Wildt DE. Comparison of embryo recovery, embryo quality, oestradiol-17 beta and progesterone profiles in domestic cats (*Felis catus*) at natural or induced oestrus. *J Reprod Fertil* 1988;82:553–61.
- [12] Kinoshita K, Ohazama M, Ishida R, Kusunoki H. Daily fecal sex steroid hormonal changes and mating success in captive female cheetahs (*Acinonyx jubatus*) in Japan. *Anim Reprod Sci* 2011;125: 204–10.
- [13] Ponglowhapan S, Church DB, Scaramuzzi RJ, Khalid M. Luteinizing hormone and follicle-stimulating hormone receptors and their transcribed genes (mRNA) are present in the lower urinary tract of intact male and female dogs. *Theriogenology* 2007;67:353–66.
- [14] Chowdhury MWH, Scaramuzzi RJ, Wheeler-Jones CPD, Khalid M. The expression of angiogenic growth factors and their receptors in ovarian follicle throughout the estrous cycle in the ewe. *Theriogenology* 2010;73:856–72.
- [15] Ishibashi H, Suzuki T, Suzuki S, Moriya T, Kaneko C, Takizawa T, et al. Sex steroid hormone receptors in human thymoma. *J Clin Endocrinol Metab* 2003;88:2309–17.
- [16] Ponglowhapan S, Church DB, Khalid M. Differences in the expression of luteinizing hormone and follicle-stimulating hormone receptors in the lower urinary tract between intact and gonadectomised male and female dogs. *Domest Anim Endocrinol* 2008;34:339–51.
- [17] Tharasanit T, Thongkittidilok C, Sananmuang T, Techakumphu M. Recombinant human follicle stimulating hormone and growth factors improve the meiotic and developmental competence of cat oocyte. *Thai J Vet Med* 2014;44:107–15.
- [18] Sano J, Nagafuchi S, Yamazaki J, Oguma K, Kano R, Hasegawa A. Effect of antineoplastic drugs on the expression of Bcl-2 and Bcl-xL genes in the feline T-cell leukemia cell line. *Res Vet Sci* 2005;79: 197–201.
- [19] Risso A, Corrada Y, Barbeito C, Diaz JD, Gobello C. Long-term-release GnRH agonists postpone puberty in domestic cats. *Reprod Domest Anim* 2012;47:936–8.
- [20] Brown JL, Wasser SK, Wildt DE, Graham LH. Comparative aspects of steroid hormone metabolism and ovarian activity in felids, measured noninvasively in feces. *Biol Reprod* 1994;51:776–86.
- [21] Brown JL. Comparative endocrinology of domestic and nondomestic felids. *Theriogenology* 2006;66:25–36.
- [22] Bristol-Gould S, Woodruff TK. Folliculogenesis in the domestic cat (*Felis catus*). *Theriogenology* 2006;66:5–13.
- [23] Orosz SE, Morris PJ, Doody MC, Niemeyer GP, Cortelyou Lee J, Eaton NL, et al. Stimulation of folliculogenesis in domestic cats with human FSH and LH. *Theriogenology* 1992;37:993–1004.
- [24] Saint-Dizier M, Malandain E, Thoumire S, Remy B, ChastantMaillard S. Expression of follicle stimulating hormone and luteinizing hormone receptors during follicular growth in the domestic cat ovary. *Mol Reprod Dev* 2007;74:989–96.
- [25] Wright PJ, Verstegen JP, Onclin K, Jochle W, Armour AF, Martin GB, et al. Suppression of the oestrous responses of bitches to the GnRH analogue deslorelin by progestin. *J Reprod Fertil Suppl* 2001;57:263–8.
- [26] Ponglowhapan S. Clinical applications of GnRH agonist deslorelin in dogs and cats. *Thai J Vet Med Suppl* 2011;41:59–63.
- [27] Pelican KM, Brown JL, Wildt DE, Ottinger MA, Howard JG. Short term suppression of follicular recruitment and spontaneous ovulation in the cat using levonorgestrel versus a GnRH antagonist. *Gen Comp Endocrinol* 2005;144:110–21.

- [28] Gudermuth DF, Newton L, Daels P, Concannon P. Incidence of spontaneous ovulation in young, group-housed cats based on serum and faecal concentrations of progesterone. *J Reprod Fertil Suppl* 1997;51:177–84.
- [29] Chatdarong K, Rungsipipat A, Axner E, Linde Forsberg C. Hystero-graphic appearance and uterine histology at different stages of the reproductive cycle and after progestagen treatment in the domestic cat. *Theriogenology* 2005;64:12–29.
- [30] Kelly RE, Verhage HG. Hormonal effects on the contractile apparatus of the myometrium. *Am J Anat* 1981;161:375–82.

Table 1: Description of forward and reverse primers for GAPDH as housekeeping gene and feline LHR and FSHR as target genes.

Gene	Primer sequence (5'-3')	Length (bp)	Annealing temperature (°C)	Reference
GAPDH	F: GGAGAAAGCTGCCAAATATG	20	61.4	Tharasanit et al. 2014 [17], Sano et al. 2005 [18]
	R: AGGAAATGAGCTTGACAAAGTGG	23		
LHR	F: CTAATGCCTTTGACAACCTAATA	23	61.4	Tharasanit et al. 2014 [17]
	R: CCCATTGAATGCATGACTTTGTA	23		
FSHR	F: CATGCTGCTAGGCTGGATCTT	21	61.4	Tharasanit et al. 2014 [17]
	R: CTTGGCGATCTTGGTGCTACT	21		

Abbreviations: F, forward; FSHR, follicle stimulating hormone receptor; GAPDH, glyceraldehyde-phosphate-dehydrogenase; LHR, luteinizing hormone receptor; R, reverse.

Table 2: Mean \pm standard error of the mean (SEM) ovarian weight (g), numbers of structures (follicles and corpora lutea) per mm² of ovarian tissue, uterine gland diameter (μ m), endometrial and myometrial thickness (μ m) in deslorelin-implanted (n = 6), control (follicular, luteal, and inactive) (n = 6/phase), and prepubertal OVH (n = 6) female cats.

Groups	Ovarian weight (g)	Numbers (SEM)/mm ² of ovarian tissue					Endometrial gland diameter (μ m)	Endometrial thickness (μ m)	Myometrial thickness (μ m)
		Primordial follicle	Primary follicles	Secondary follicles	Antral follicles	Corpora lutea			
Deslorelin implanted	0.03 \pm 0.00a	310.33 \pm 45.49a	32.33 \pm 4.88a	4.00 \pm 1.15ab	1.33 \pm 0.67a	0.00 \pm 0.00a	30.45 \pm 2.37ab	374.54 \pm 14.6a	361.90 \pm 20.19ad
Controls (follicular)	0.12 \pm 0.01b	234.33 \pm 45.12a	16.33 \pm 5.04b	8.67 \pm 2.04a	8.33 \pm 1.09bc	0.67 \pm 0.67a	40.44 \pm 5.22a	515.85 \pm 115.2a	733.57 \pm 153.29b
Controls (luteal)	0.13 \pm 0.02b	204.67 \pm 30.14a	10.33 \pm 2.39b	4.00 \pm 1.03b	4.67 \pm 0.42ab	7.33 \pm 0.99b	40.75 \pm 6.17a	506.43 \pm 114.3a	705.36 \pm 142.90bc
Controls (inactive)	0.08 \pm 0.01c	249.00 \pm 57.50a	11.33 \pm 2.91b	6.33 \pm 1.67ab	6.67 \pm 1.98bc	0.00 \pm 0.00a	32.60 \pm 4.11ab	439.37 \pm 40.3a	504.16 \pm 67.94acd
Prepubertal OVH	0.08 \pm 0.01c	344.67 \pm 64.63a	25.33 \pm 5.28ab	9 \pm 3.61ab	9.00 \pm 1.69c	0.00 \pm 0.00a	25.13 \pm 7.56b	398.32 \pm 50.7a	392.27 \pm 56.80d

Values with different superscripts within a column differ significantly (P < 0.05).

Abbreviation: OVH, ovariectomized.

Figure legends

Figure 1: The mean (\pm SEM) body weight (kg) in cats ($n=6$ /group) with or without deslorelin implantation. Cats were implanted with deslorelin at the age of 3 months for a period of 48 weeks. Black arrow indicates the weeks (22nd to 26th) during which the control group had significantly higher ($P \leq 0.05$) body weight than the deslorelin-implanted group.

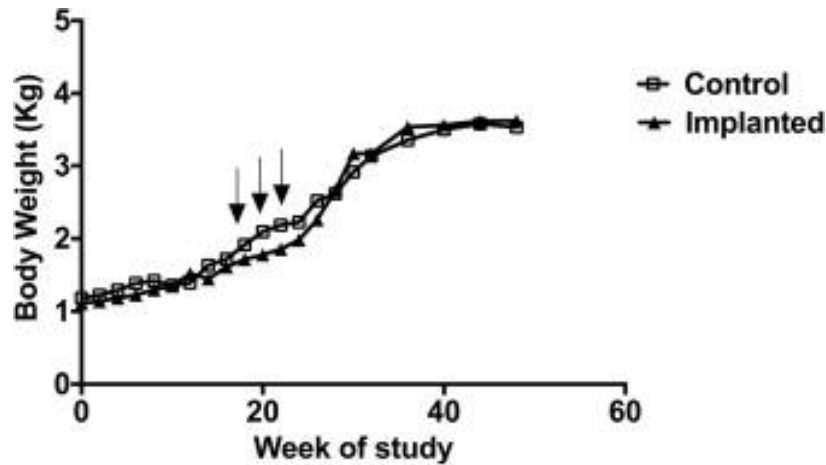


Figure 2: The mean (\pm SEM) testicular volume (cm^3) in cats ($n=6$ /group) with or without deslorelin implantation. Cats were implanted with deslorelin at the age of 3 months for a period of 48 weeks. Black arrows indicate estradiol peaks in control cats.

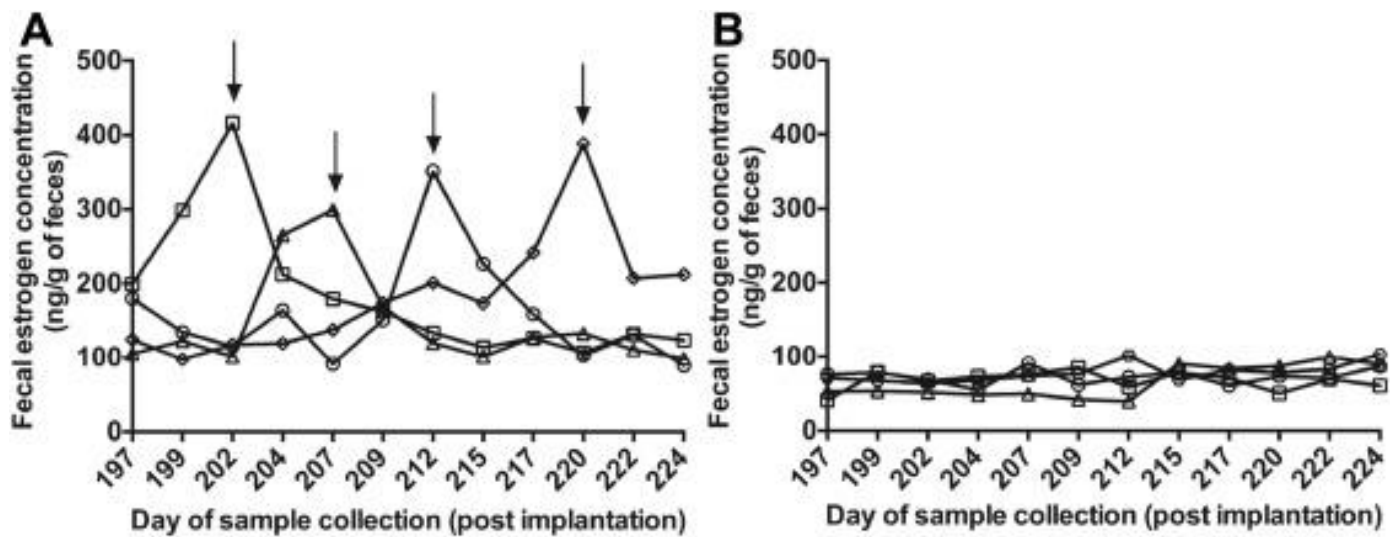


Figure 3. Histological sections of uterus showing epithelia of endometrial glands (G) in implanted cats having a single layer of cuboidal cells (upper panel), and control luteal and follicular (lower panel) cats having a single layer columnar epithelial cells of greater height and abundant secretion in the glands. Black arrows identifies the epithelial cell of the endometrial glands.

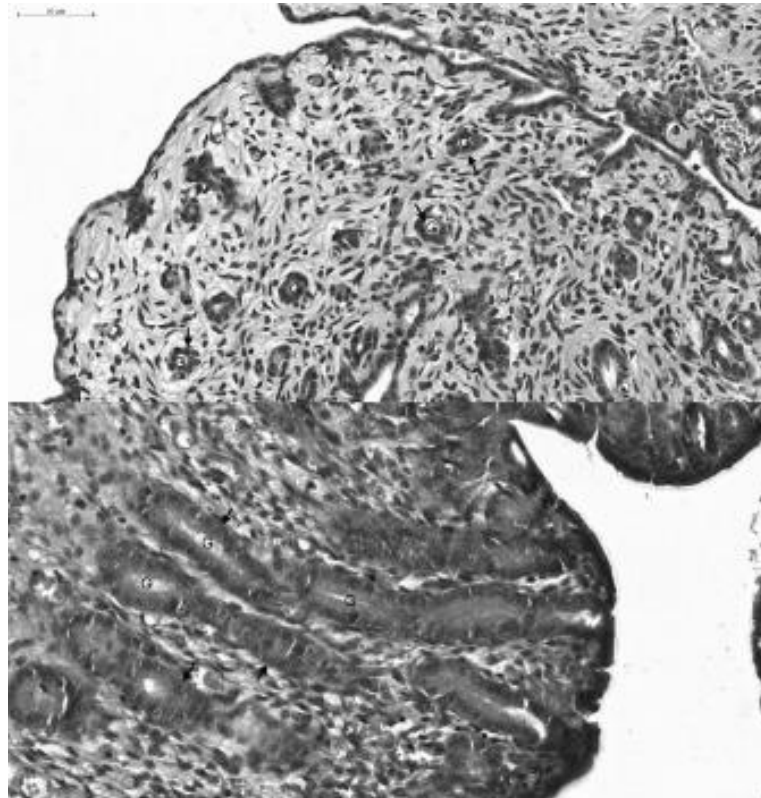


Figure 4. The mean (\pm standard error of the mean) level of protein (left) and mRNA (fg/ μ g of RNA) (right) expression for the ovarian LHR and FSHR in cats that were either prepubertal OVH (n = 6) or implanted with deslorelin (n = 6) at the age of 3 months for 48 weeks or nonimplanted controls at the inactive, follicular and luteal phase (n = 6/phase) of their estrous cycle. Different letters on bars for a certain receptor indicate significant ($P \leq 0.05$) differences. FSHR, follicle stimulating hormone receptor; LHR, luteinizing hormone receptor; OVH, ovariectomized.

