

This article is posted on this site with the permission of the American Veterinary Medical Association, which holds the copyright for the article. For permission to distribute the article, in print or electronically, please contact the AVMA ([dfagen@avma.org](mailto:dfagen@avma.org)).

The version of record is available via on the AVMA site via <http://dx.doi.org/10.2460/ajvr.77.11.1245>.

The full details of the published version of the article are as follows:

TITLE: Feasibility, repeatability, and safety of ultrasound-guided stimulation of the first cervical nerve at the alar foramen in horses

AUTHORS: Céline Mespoulhès-Rivière DVM, PhD; Olivier Brandenberger DVM; Fabrice Rossignol DVM; Céline Robert DVM, PhD; **Justin D. Perkins** DVM, MS; Jean-Paul Marie MD, PhD; Norm Ducharme DVM, MSc

JOURNAL TITLE: American Journal of Veterinary Research

VOLUME/EDITION: 77/11

PUBLISHER: American Veterinary Medical Association

PUBLICATION DATE: November 2016

DOI: 10.2460/ajvr.77.11.1245

# Feasibility, repeatability, and safety of ultrasound-guided stimulation of the first cervical nerve at the alar foramen in horses

Céline Mespoulhès-Rivière DVM, PhD

Olivier Brandenberger DVM

Fabrice Rossignol DVM

Céline Robert DVM, PhD

Justin D. Perkins DVM, MS

Jean-Paul Marie MD, PhD

Norm Ducharme DVM, MSc

From the Equine Clinic (Mespoulhès-Rivière, Brandenberger) and the Department of Anatomy (Robert), Université Paris Est, Ecole Nationale Vétérinaire d'Alfort, 94700 Maisons-Alfort, France; the Veterinary Clinic of Grosbois, Domaine de Grosbois, 94470 Boissy-Saint-Léger, France (Brandenberger, Rossignol); the Department of Veterinary Clinical Sciences, Royal Veterinary College, Hatfield, Hertfordshire AL9 7TA, England (Perkins); the Department of Otorhinolaryngology, Head & Neck Surgery, Rouen University Hospital, 76031 Rouen and EA 3830 GRHV (Research Group on Ventilatory Handicap), Institute for Research and Innovation in Biomedicine, Normandy University, France (Marie); and the Department of Clinical Sciences, College of Veterinary Medicine, Cornell University, Ithaca, NY 14853 (Ducharme).

Address correspondence to Dr. Mespoulhès-Rivière ([celine.mespoulhes@vet-alfort.fr](mailto:celine.mespoulhes@vet-alfort.fr)).

## OBJECTIVE

To develop and assess the feasibility, repeatability, and safety of an ultrasound-guided technique to stimulate the first cervical nerve (FCN) at the level of the alar foramen of the atlas of horses.

## ANIMALS

4 equine cadavers and 6 clinically normal Standardbreds.

## PROCEDURES

In each cadaver, the FCN pathway was determined by dissection, and any anastomosis between the first and second cervical nerves was identified. Subsequently, each of 6 live horses underwent a bilateral ultrasound-guided stimulation of the FCN at the alar foramen 3 times at 3-week intervals. After each procedure, horses were examined daily for 5 days.

## RESULTS

In each cadaver, the FCN passed through the alar foramen; a communicating branch between the FCN and the accessory nerve and anastomoses between the ventral branches of the FCN and second cervical nerve were identified. The anastomoses were located in the upper third of the FCN pathway between the wing of the atlas and the nerve's entry in the omohyoideus muscle. Successful ultrasound-guided electrical stimulation was confirmed by twitching of the ipsilateral omohyoideus muscle in all 6 live horses; this finding was observed bilaterally during each of the 3 experimental sessions. No complications developed at the site of stimulation.

## CONCLUSIONS AND CLINICAL RELEVANCE

Results indicated that ultrasound-guided stimulation of the FCN at the alar foramen appears to be a safe and straightforward procedure in horses. The procedure may have potential for use in horses with naturally occurring recurrent laryngeal neuropathy to assess reinnervation after FCN transplantation or nerve-muscle pedicle implantation in the cricoarytenoideus dorsalis muscle. (*Am J Vet Res* 2016;77:1245–1251)

In horses, each wing of the atlas is perforated by 2 foramina: the caudal one is the transverse foramen and the rostral one is the alar foramen (**Figure 1**).<sup>1–3</sup> On the dorsal surface of each wing, the alar foramen is connected with the intervertebral foramen by a short groove. Emerging from the transverse foramen of the axis, the vertebral artery enters the transverse foramen of the atlas; after coursing through the atlantal fossa and reception of an anastomotic branch from the occipital artery (ramus anastomoticus cum a. occipitali), the vertebral artery runs dorsally through the alar foramen and enters the vertebral canal through the intervertebral foramen.<sup>1,3</sup> The first cervical nerve originates from the spinal cord and emerges from the vertebral canal through the intervertebral foramen. Its dorsal branch (n. suboccipitalis) passes dorso-laterally and supplies branches to the rectus capitis dorsalis, obliquus capitis cranialis, obliquus capitis caudalis, semispinalis capitis, and splenius cervicis muscles; a cutaneous branch innervates the area lo-

cated medially to the base of the ear.<sup>1,3,4</sup> The ventral branch of the first cervical nerve, which was of interest in the study reported here, passes in the short groove between the intervertebral and the alar foramina.<sup>4</sup> The nerve then descends through the alar foramen in the atlantal fossa where it is connected by 1 or more nerve branches to the cranial cervical ganglion of the sympathetic trunk and also to the hypoglossal nerve. The connection between the hypoglossal nerve and ventral branches of the first and the second cervical nerves is described as the cervical loop. The ventral branch of the first cervical nerve crosses over the longus capitis and rectus capitis ventralis muscles and lies lateral to the common carotid artery deep to the parotid gland, then divides into 2 branches.<sup>1</sup> The cranial branch enters the omohyoideus muscle. The caudal branch passes ventrally and caudally under that muscle, unites with a branch of the ventral division of the second cervical nerve, and continues its course on the ventrolateral surface of the trachea to

enter the sternohyoideus and sternothyroideus muscles.<sup>1</sup> The omohyoideus, sternohyoideus, and sternothyroideus muscles are accessory muscles of respiration and are activated during forced inspiration.<sup>5-7</sup>

Given the anatomic location of the ventral branch of the first cervical nerve close to the larynx and its activation during forced inspiration, it is an ideal candidate for reinnervation procedures to treat progressive atrophy of the left cricoarytenoideus dorsalis muscle in horses with left recurrent laryngeal neuropathy.<sup>8,9</sup> Reinnervation of the paralyzed cricoarytenoideus dorsalis muscle was proposed by Smith in 1894 and Tagg in 1935.<sup>10</sup> The first implantations of the second cervical nerve transplants and nerve-muscle pedicles in horses were reported by Ducharme et al<sup>5,11</sup> in 1989. The nerve-muscle pedicle graft technique involving the first cervical nerve has been established by Fulton et al.<sup>6,12</sup> More than 350 clinical cases have since been treated with a success rate similar to that associated with prosthetic laryngoplasty.<sup>12-15</sup>

The interval after surgery at which reinnervation occurs in horses has not been precisely determined partly because of the difficulty in identifying endoscopic signs of reinnervation. Currently, time to reinnervation after nerve transplant or nerve pedicle graft in horses is largely based on personal experience<sup>a</sup> and has been thought to occur 4 to 5 months after surgery, with 12 weeks being the shortest interval to return of function.<sup>14</sup> Compared with humans and dogs, wherein the first signs of reinnervation are evident at 2 to 6 weeks after surgery,<sup>15,16</sup> the estimated reinnervation time in horses is surprisingly long.

In horses, the first cervical nerve is a purely motor nerve activated during forced inspiration, which makes a proof of successful reinnervation difficult.<sup>4,5,11</sup> After surgery, 2 reflex tests can be performed in resting horses to determine whether the cricoarytenoideus dorsalis muscle has been reinnervated.<sup>13,17</sup> One test involves stretching the head of the horse as high as possible, which should result in a flicker of the left arytenoid cartilage if reinnervation has been successful. The other test involves pulling back rapidly on the commissure of the lip junction with a hooked finger or the bit, which often results in a sudden abduction of the left arytenoid cartilage if reinnervation has been successful. In our experience, these test results are difficult to interpret because of movements of the endoscope in relation to the larynx during those manipulations, and findings are highly dependent on the character of the horse.

Nerve stimulation with or without ultrasound guidance is used in human and veterinary surgery to locate nerves for perineural anesthesia.<sup>18-22</sup> After a reinnervation procedure, stimulation of the first cervical nerve with a nerve stimulator should induce abduction of the left arytenoid cartilage if the reinnervation of the ipsilateral cricoarytenoideus dorsalis muscle has occurred. Therefore, postoperative reinnervation could be verified earlier, and the degree of abduction could be quantified via stimulation above

the fusion frequency. This could reduce the time to resumption of training and the overall duration of convalescence.

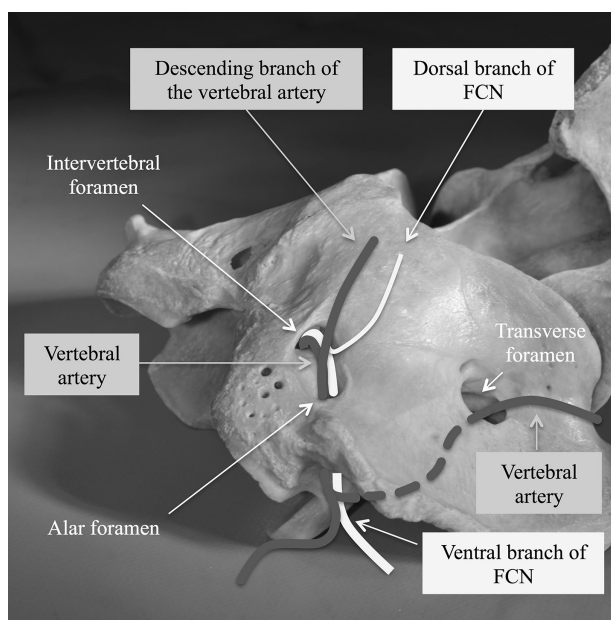
Because the first cervical nerve is reported to exit the alar foramen of the atlas, the location of which is close to the skin, we hypothesized that this anatomic location would allow easy, repeatable, and safe access to the first cervical nerve for stimulation under ultrasound guidance. The purpose of the study reported here was to develop and assess the feasibility, repeatability, and safety of an ultrasound-guided technique to stimulate the ventral branch of the first cervical nerve at the level of the alar foramen of the atlas of clinically normal horses. The intent was to determine whether that procedure would lead to a stimulation of the omohyoideus muscle and evaluate any nerve or vascular damage associated with needle insertion and nerve stimulation.

## Materials and Methods

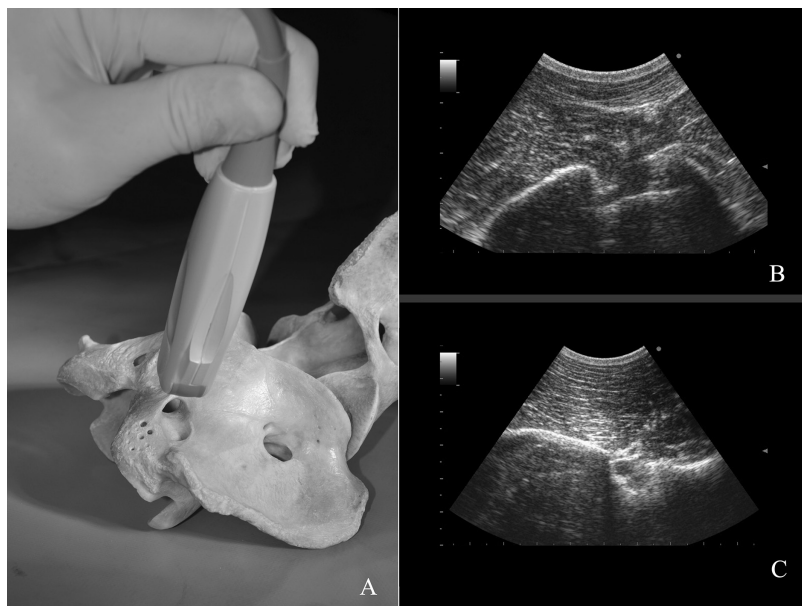
### Anatomic dissection of equine cadavers

Four horses were euthanized by means of IV injection of a barbiturate solution for reasons unrelated to the study. Immediately after euthanasia, each head-neck segment was removed at the level of the C4-C6 vertebrae and cooled for 12 to 24 hours. An experienced anatomist (CR) supervised the dissections on the left side of each head-neck segment. First, the skin of the neck up to the mandible was removed. Then, the alar foramen was approached dorsally. The wing of the atlas was palpated dorsal to the common tendon of the splenius cervicis and longissimus atlantis muscles and dorsal to the tendon of the longissimus capitis muscle. The splenius cervicis muscle was bluntly dissected along the ventral border of the atlas and retracted. The underlying semispinalis capitis muscle was bluntly dissected on its ventral border and reflected dorsally to reveal the junction between the cranial and the caudal parts of the oblique muscle of the head. The insertion of the obliquus capitis caudalis muscle on the wing of the atlas was cut, and the muscle was removed, revealing the alar foramen on the atlas.

Nerve and vascular structures passing through the alar foramen were dissected. The vertebral artery was identified just cranial to the nerve in the groove. The descending branch emerging dorsally from the artery just after its passage through the alar foramen, which supplies the overlying muscles, was also visualized (**Figure 1**). The vein originating from the muscles of the dorsal aspect of the wing of the atlas and passing through the alar foramen was dissected as well. Then, the ventral branch of the first cervical nerve was dissected in the atlantal fossa to identify the first and second cervical nerve anastomosis. The parotid gland was carefully retracted with blunt dissection. The first cervical nerve was identified at its entry into the omohyoideus muscle and dissected along its entire length up to the atlas. Any branches anastomosing with other nerves were preserved; the corresponding nerve was identified and noted.



**Figure 1**—Annotated photographic image of the atlas of an equine cadaver. The first cervical nerve (FCN) passes through the intervertebral and alar foramina. The passage of the corresponding part of the vertebral artery is indicated, as it is an anatomic landmark for ultrasonographic examinations. The descending branch of the vertebral artery emerges between the intervertebral and alar foramina. The left transverse foramen is also shown more caudally.



**Figure 2**—Photograph (A) and ultrasonographic images (B and C) of the atlas of an equine cadaver and a live horse, respectively. A—The position of the ultrasound probe over the alar foramen from which the ultrasonographic images were obtained is illustrated. B—Characteristic ultrasonographic image of the intervertebral (medial) and alar (lateral) foramina in a live horse. C—Characteristic ultrasonographic image of the transverse foramen in a live horse. In panels B and C, the scale markings denote 0.5-cm intervals, and medial is to the left.

## Stimulation of the first cervical nerve in clinically normal horses

After approval of the local ethics committee (An-

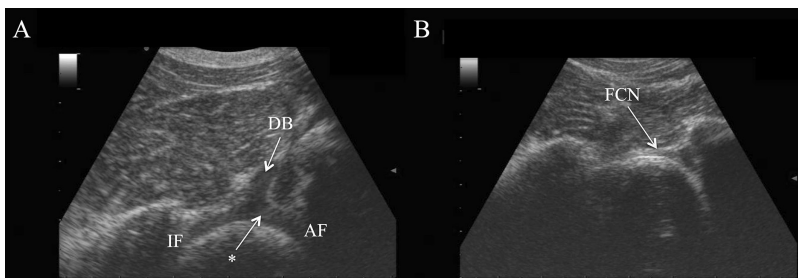
ses/ENVA/UPEC, N°14-058, November 18, 2014) was obtained, 6 university-owned research horses were tested bilaterally in 3 experiments. Breed, age, and sex of the horses were recorded. Gross palpation of the omohyoideus muscle and the regions of the wings of the atlas did not reveal any abnormality in any horse. Each horse was positioned in stocks and administered detomidine hydrochloride (0.01 mg/kg, IV) and butorphanol tartrate (0.01 mg/kg, IV). The headpiece of the halter was advanced and placed cranial to the ears, then fixed on the forehead of the horse with tape. An area (10 X 10cm) of skin over each wing of the atlas was clipped and prepared aseptically. Sterile surgical gloves were worn during the procedure. The head of the horse was rested on a height-adjustable head support to generate slight extension of the neck. The examination and stimulation were performed by the same investigators for all procedures. Ultrasonography was performed with a portable ultrasound machine<sup>b</sup> that was placed in front of the horse. An 8- to 5-MHz, 11-mm, broadband, curved array transducer<sup>c</sup> was used in a sterile sleeve.

One investigator (OB) handled the ultrasound transducer and approached the horse from the side of the stimulation. The second investigator (CM) stood on a 30-cm-high foot stool on the contralateral side of the site of the stimulation. An assistant manipulated the stimulation device<sup>d</sup> that was also placed on the

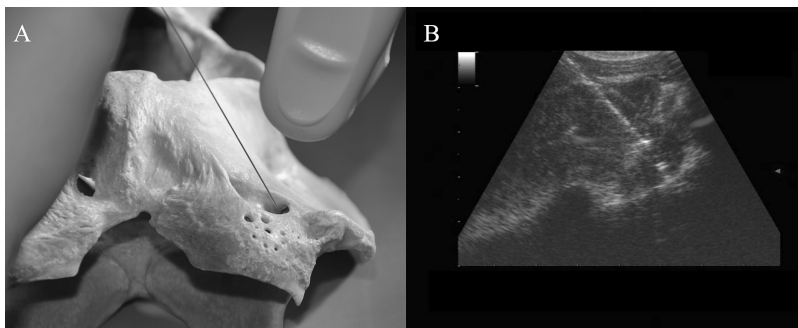
contralateral side of the site of stimulation. First, detection of the alar foramen and the lateral vertebral foramen was attempted in a plane perpendicular to the skin and at an angle of 60° to 80° to the sagittal plane in a cranio-lateral-to-caudomedial direction on the cranial aspect of the wing of the atlas. The probe was moved in this position rostrally and caudally as well as medially and laterally until the characteristic picture of the lateral vertebral and alar foramen was obtained (**Figure 2**). Care was taken not to confuse the alar foramen with the more caudally situated and larger transverse foramen, which has a different ultrasonographic appearance. To locate the first cervical nerve, the vertebral artery and its descending branch emerging dorsally just after its passage through the alar foramen were first visualized. These arteries were viewed longitudinally with the ultrasound probe. Once the characteristic image was obtained (**Figure 3**), the probe was moved slightly caudally to visualize the hyperechoic first cervical nerve as it crossed the groove and entered the alar foramen.

Next, a 26-gauge, 3-inch stimulating needle<sup>c</sup> was inserted 2 to 3 cm medial to the probe at approximately 30° to 45° to the horizontal plane and

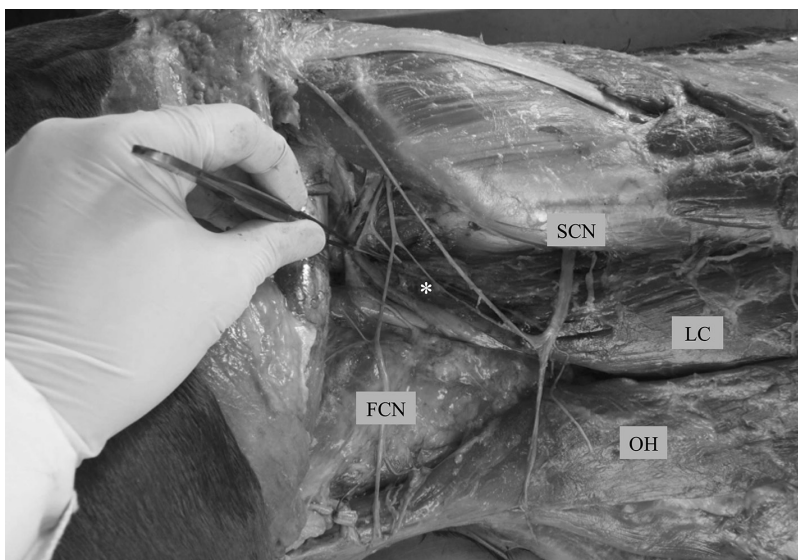




**Figure 3**—Ultrasonographic images of the alar and intervertebral foramina. In panel A, the vertebral artery (asterisk) and its descending branch (DB) emerge dorsally and are used as an anatomic landmark. In panel B, the probe has been moved slightly caudally to allow visualization of the ventral branch of the FCN as a hyperechoic horizontal structure entering the alar foramen. In panels A and B, the scale markings denote 1-cm intervals, and medial is to the left. AF = Alar foramen. IF = Intervertebral foramen. See Figure 1 for remainder of key.



**Figure 4**—Photograph (A) and ultrasonographic image (B) of the atlas of an equine cadaver and a live horse, respectively. A—The left alar foramen is shown, with a stimulating needle passed from medial to lateral. The tip of the needle is aiming at the ventral branch of the FCN, just as it enters the alar foramen. Medial is to the left. B—The ultrasonographic image confirms successful placement of the needle in a live horse. In panel B, the scale markings denote 1 cm. See Figure 1 for remainder of key.



**Figure 5**—Photograph of a dissected portion of the left side of the neck of an equine cadaver after removal of the parotid gland, the jugular vein, and the accessory nerve (cranial nerve XI). A communicating branch (asterisk) between the ventral branch of the FCN and the ventral branch of the second cervical nerve (SCN) is visible. LC = Longissimus capitis muscle. OH = Omohyoideus muscle. See Figure 1 for remainder of key.

in a medial-to-lateral direction (**Figure 4**). The needle was advanced under ultrasound guidance until its tip was positioned just next to the nerve and observed as an echogenic structure located at the lateral limit of the alar foramen. Osseous contact ensured correct needle placement. Attention was taken not to penetrate the vessels in this area. Once the needle was in place, stimulation was initiated by the technician at an initial amplitude of 0.02 mA, a frequency of 1 Hz, and a pulse duration of 0.3 milliseconds. The frequency and pulse duration had been determined during pilot examinations in 4 normal horses (unpublished data) and are comparable with values routinely used for peripheral nerve stimulations in humans and other animals.<sup>23-25</sup> The operator who was holding the ultrasound probe placed his free hand in the Viborg triangle to detect muscle twitching of the omohyoideus muscle. If no response of the omohyoideus muscle or the sternohyoideus and sternothyroideus muscles was palpable, the current intensity was increased slowly in 0.02-mA increments. Once the response of the muscles was palpable, the resulting current intensity was designated as the threshold current intensity. If the current intensity reached 1 mA without palpable and visible muscle contraction, the needle was repositioned. To complete the experiment, the procedure was repeated for the contralateral alar foramen. Time from the placement of the ultrasound probe to the successful stimulation of the omohyoideus muscle and sternohyoideus as well as the number of attempts on each side was recorded. The contact of the needle with a vessel during the placement was documented. The reaction of each horse to the stimulation procedures was noted.

For each horse, ultrasonographic examinations of both alar foramina were obtained 24 hours after the stimulation experiment to assess the site of stimulation and detect hematoma formation. The horse was evaluated clinically (assessments of rectal temperature, heart rate, and appetite) and the area of the stimulation on the neck was checked for any swelling, heat, and signs of pain by a veterinary nurse once daily for 5 days after the stimulation procedures. The stimulation proto-

col and follow-up were repeated twice for all horses at 3-week intervals.

## Results

### Anatomic dissection of equine cadavers

For the dissection part of the study, the head and neck of an 8-year-old Quarter Horse stallion, 2 French Warmblood geldings (6 years old and 16 years old), and a 19-year-old Connemara Pony mare were used. In all 4 cadavers, the first cervical nerve was identified traversing from the intervertebral foramen through the groove to the alar foramen.

Anastomoses between the ventral branches of the first and second cervical nerves, as described in the veterinary medical literature,<sup>1,3,4</sup> were found in all 4 cadavers. The anastomoses were situated in the upper third of the first cervical nerve pathway between the wing of the atlas and the nerve's entry in the omohyoideus muscle. A communicating branch between the first cervical nerve and the accessory nerve was evident in all 4 cadavers (**Figure 5**).

### Stimulation of the first cervical nerve in clinically normal horses

The 6 experimental horses were Standardbreds (3 mares and 3 geldings, aged 5 to 18 years). Ultrasound-guided stimulation of the first cervical nerve at the alar foramen was successful bilaterally in all 6 horses during all 3 stimulation experiments; data from both sides were combined for each experiment. To obtain a response to stimulation of the omohyoideus muscle, the mean number of attempts in the first experiment was 1.2 (range, 1 to 2). In the second and third experiments, the mean number of attempts to achieve omohyoideus muscle response was slightly higher (1.8 [range, 1 to 3] and 1.5 [range, 1 to 2], respectively). In the first experiment, the mean interval between placement of the ultrasound probe and successful omohyoideus muscle response to stimulation was 85 seconds (range, 12 to 220 seconds). In the second experiment, the interval was longer (173 seconds [range, 80 to 390 seconds]). In the third experiment, the interval was shortest (60 seconds [range, 20 to 122 seconds]). The overall current-intensity threshold for perceptible omohyoideus muscle response to stimulation was 0.22 mA (range, 0.04 to 0.66 mA) in the first experiment, 0.18 mA (range, 0.02 to 0.26 mA) in the second experiment, and 0.11 mA (range, 0.01 to 0.22 mA) in the third experiment.

All the horses tolerated the nerve stimulation well. In approximately 25% of attempts, the insertion through the skin of the needle led to a defensive reaction of the horse. In those situations, another dose of butorphanol tartrate (0.005 mg/kg, IV) was administered. A nose twitch was not used in any horse at any time. On some occasions ( $n = 10$ ), and especially in the first series of experiments, the stimulation needle was placed too far medially and too close to the intervertebral foramen, thereby allowing stimula-

tion of the dorsal branch of the first cervical nerve. In those situations, a twitch of the upper neck muscles was observed and the horses had signs of slight discomfort. The stimulation was then stopped, and the needle was replaced more laterally.

At 24 hours after any of the stimulation experiments, no hematoma formation at the alar foramen was detected ultrasonographically. None of the horses developed clinical infection at the site of stimulation. In 1 horse, a superficial skin vessel on the left side was punctured during the second experiment and again during the third experiment. On each occasion, this puncture resulted in development of a small (approx 5 X 5 X 3-cm) superficial hematoma, which did not prevent the successful ultrasonographic visualization of the first cervical nerve and its subsequent stimulation. At both times, the swelling disappeared without any treatment within 72 hours after the stimulation.

In 1 horse, a deformation of the alar foramen on the left side was identified. The first cervical nerve could still be located, but the image of the alar foramen was not typical; the surface of the wing of the atlas was irregular, and head-neck trauma at some time in the past was suspected.

## Discussion

In the 6 clinically normal horses used in the present study, ultrasound-guided electrical stimulation of the first cervical nerve at the alar foramen was repeatable and successful on both sides of the neck. Development of lesions in the tissues surrounding the stimulation sites or in the ventral branches of the first cervical nerves (eg, neuroma formation) was not detected with ultrasonography or clinical examination during a 6-week poststudy period. The stimulation of all 12 nerves was successfully accomplished during the first experiment and repeated twice thereafter at 3-week intervals. The findings of the present study were in accordance with those of a study<sup>26</sup> in humans wherein nerve puncture and even intraneural injection did not lead to measurable neurologic injury (as indicated by qualitative sensory and qualitative and quantitative motor testing). The routine use of perineural anesthesia during orthopedic examinations in horses supports this finding. During this type of diagnostic test, superficial nerves (eg, digital palmar nerves) can be traumatized by the needle. Perineural anesthesia is a widely accepted procedure, and there is, to our knowledge, no published report of neurologic injury following such diagnostic testing in horses. Results of the present study indicated that ultrasound-guided electrical stimulation of the first cervical nerve is a safe procedure and could be used to evaluate reinnervation after a first cervical nerve transplant or nerve-muscle pedicle implantation in the cricoarytenoideus dorsalis muscle.

Stimulation of the first cervical nerve was easy to perform but there was a distinct learning curve. The number of attempts was higher and the time spent to

stimulate the nerve was longer in the second experiment, compared with findings during the first experiment. During the first experiment, we discovered that the nerve could be stimulated at a very low current intensity. In the second experiment, we spent more time to ensure accurate placement of the needle to obtain a lower current-intensity threshold. The overall threshold was lower in the second experiment, and in a few procedures, as much as 0.02 mA resulted in a palpable response of the omohyoideus muscle. During those procedures, the needle was contacting the nerve, which was visible ultrasonographically. In humans, direct contact with the nerve (epineurium) can be associated with paresthesia or dysesthesia.<sup>26</sup> Some of the horses in the present study reacted with a twitch of the head at a few occasions when the needle touched or entered the nerve. Even if the needle is not placed directly on the nerve but in the perineural tissue, stimulation with higher amplitude (0.5 to 1 mA) can still activate the nerve. Therefore, our opinion is that actual penetration of the nerve is unnecessary.

In the cadavers used in the present study, an anastomosis between the first and second cervical nerves proximal to the standard site of transplantation and grafting was consistently identified. This anastomosis is described in the specialized veterinary anatomic literature.<sup>1,3,4</sup> We believe that because of the presence of this anastomosis, nerve stimulation of the first cervical nerve could be used to assess the reinnervation status in cases of second cervical nerve transplant or nerve-muscle pedicle graft (that includes the first or second cervical nerve) in the cricoarytenoideus dorsalis muscle. The stimulation of the first cervical nerve at the alar foramen should result in arytenoid cartilage twitching because first and second cervical nerves communicate through the anastomosis. Anecdotally, 3 horses were tested with this method of first cervical nerve stimulation at 4.5, 6, and 8 months, respectively, after nerve-muscle pedicle graft surgery, and twitching of the left arytenoid cartilage was detected.<sup>a</sup>

In the present study, histologic examination of the stimulated part of the first cervical nerve might have revealed more information regarding whether the nerve was harmed during stimulation. It would be reassuring to know that no damage occurred to the transplanted nerve when the stimulation procedure was used to confirm the reinnervation of the cricoarytenoideus dorsalis muscle. However, this would have required euthanasia of the experimental horses. We observed the 6 horses for 3 months to ensure that no visible atrophy of the omohyoideus muscle developed. Because contact of the needle with the nerve can be avoided with accurate ultrasound guidance and with higher stimulation amplitude, nerve trauma should be a low risk with this procedure. Perineural anesthesia would have confirmed a correct placement of the needle, as further stimulation would not

lead to omohyoideus muscle contraction. This test was not performed because of the close proximity of the alar foramen to the vertebral canal and because the procedure was conducted in standing horses. The placement of electromyographic needles in the omohyoideus muscle would have provided information to confirm that the correct muscle was stimulated. Owing to the superficial and ventrolateral position of the omohyoideus muscle relative to the larynx, muscle contraction was easily palpable and visible.

On the basis of the results of the present study, ultrasound-guided stimulation of the first cervical nerve at the alar foramen appears to be a reliable, repeatable, and straightforward technique and should allow assessment of the functioning of a first or second cervical nerve transplant or nerve-muscle pedicle graft in the cricoarytenoideus dorsalis muscle. This procedure could allow more precise determination of time of reinnervation and possibly reduce convalescence time after laryngeal reinnervation for treatment of laryngeal hemiplegia in horses.

## Acknowledgments

Supported in part by MED-EL, Innsbruck, Austria, and the Ecole Nationale Vétérinaire d'Alfort, Maisons-Alfort, France.

The authors declare that there were no conflicts of interest.

The authors thank Marie Martin for technical assistance and Tamara Bosshardt for assistance with iconography.

## Footnotes

- a. Fulton I, Ballarat Veterinary Practice, VIC, Australia: Personal communication, 2014.
- b. Sonosite Edge Inc, Bothell, Wash.
- c. C11x, Sonosite Inc, Bothell, Wash.
- d. Stimulplex HNS 12, B Braun Medical Inc, Sempbach, Switzerland.
- e. TECA Disposable Monopolar Needle, Care Fusion Germany, Heidelberg, Germany.

## References

1. Getty R. *Sisson and Grossman's anatomy of the domestic animals*. 5th ed. Philadelphia: WB Saunders, 1975;257-266.
2. Barone R. *Anatomie comparée des mammifères domestiques. Tome 1: ostéologie*. 5th ed. Paris: Vigot, 2010;333-343.
3. Schaller O. Illustrated veterinary anatomical nomenclature. In: Constantinescu GM, Schaller O, eds. *Illustrated veterinary anatomical nomenclature*. 2nd ed. Stuttgart, Germany: Enke Verlag, 2007;41-44.
4. Barone R, Simoens P. *Anatomie comparée des mammifères domestiques. Tome 7: neurologie II: système nerveux périphérique, glandes endocrines, esthésiologie. Nerf spinaux*. Paris: Vigot, 2010;149-320.
5. Ducharme NG, Horney FD, Partlow GD, et al. Attempts to restore abduction of the paralyzed equine arytenoid cartilage I. Nerve-muscle pedicle transplants. *Can J Vet Res* 1989;53:202-209.
6. Fulton IC, Derksen FJ, Stick JA, et al. Treatment of left laryngeal hemiplegia in Standardbreds, using a nerve muscle pedicle graft. *Am J Vet Res* 1991;52:1461-1467.
7. Crumley RL. Experiments in laryngeal reinnervation. *Laryngoscope* 1982;92:1-27.
8. Goulden BE, Anderson LJ. Equine laryngeal hemiplegia. Part I: physical characteristics of affected animals. *N Z Vet J* 1981;29:151-154.
9. Beard WL, Hayes HM. Risk factors for laryngeal hemiplegia in the horse. *Prev Vet Med* 1993;17:57-63.



10. Speirs VC. Laryngeal surgery—150 years on. *Equine Vet J* 1987;19:377-383.
11. Ducharme NG, Horney FD, Hulland TJ, et al. Attempts to restore abduction of the paralyzed equine arytenoid cartilage. II. Nerve implantation (pilot study). *Can J Vet Res* 1989;53:210-215.
12. Fulton IC, Derksen FJ, Stick JA, et al. Treatment of left laryngeal hemiplegia using a nerve muscle pedicle graft. In: Persson SGB, Lindholm A, Jeffcott LB, eds. *Equine exercise physiology*. Vol 3. Davis, Calif: ICEEP Publications, 1991;443-448.
13. Fulton IC, Stick JA, Derksen FJ. Laryngeal reinnervation in the horse. *Vet Clin North Am Equine Pract* 2003;19:189-208.
14. Fulton IC, Anderson BH, Stick JA, et al. Larynx. In: Auer J, Stick JA, eds. *Equine surgery*. 4th ed. Philadelphia: Saunders Elsevier, 2012;592-623.
15. Tucker HM, Harvey J, Ogura JH. Vocal cord remobilization in the canine larynx. *Arch Otolaryngol* 1970;92:530-533.
16. Tucker HM. Human laryngeal reinnervation. *Laryngoscope* 1976;86:769-779.
17. Fulton IC. Equine laryngeal reinnervation. In: McGorum BC, Robinson NE, Schumacher J, et al, eds. *Equine respiratory medicine and surgery*. Philadelphia: Saunders Elsevier, 2007;509-514.
18. Neal JM, Gerancher JC, Hebl JR. Upper extremity regional anesthesia: essentials of our current understanding, 2008. *Reg Anesth Pain Med* 2009;34:134-170.
19. Campoy L, Bezuidenhout AJ, Gleed RD, et al. Ultrasound-guided approach for axillary brachial plexus, femoral nerve, and sciatic nerve blocks in dogs. *Vet Anaesth Analg* 2010;37:144-153.
20. Shilo Y, Pascoe PJ, Cissell D, et al. Ultrasound-guided nerve blocks of the pelvic limb in dogs. *Vet Anaesth Analg* 2010;37:460-470.
21. Smith DC, Miah H. A nerve stimulator for peripheral nerve blockade. *Anaesthesia* 1985;40:569-571.
22. Urmey WF. Using the nerve stimulator for peripheral or plexus nerve blocks. *Minerva Anesthesiol* 2006;72:467-471.
23. Perlas A, Niazi A, McCartney C, et al. The sensitivity of motor response to nerve stimulation and paresthesia for nerve localization as evaluated by ultrasound. *Reg Anesth Pain Med* 2006;31:445-450.
24. Vanschandevijl K, Nollet H, Vonck K, et al. Functional electrical stimulation of the left recurrent laryngeal nerve using a vagus nerve stimulator in a normal horse. *Vet J* 2011;189:346-348.
25. Casati A, Danelli G, Baciarello M, et al. A prospective, randomized comparison between ultrasound and nerve stimulation guidance for multiple injection axillary brachial plexus block. *Anesthesiology* 2007;106:992-996.
26. Bigeleisen PE. Nerve puncture and apparent intraneural injection during ultrasound-guided axillary block does not invariably result in neurologic injury. *Anesthesiology* 2006;105:779-783.