



Thin and hypokinetic myocardial segments in cats with cardiomyopathy^{☆, ☆ ☆}

J. Novo Matos, DVM, PhD^{a,b,*}, J. Sargent, BVSc^c, J. Silva, DVM^{a,d}, J.R. Payne, BVetMed, PhD^e, J. Seo, MVetMed^f, I. Spalla, DVM, PhD^g, K. Borgeat, MVetMed^e, J. Loureiro, DVM^d, N. Pereira, DVM, MSc^h, I.C. Simcock, PhD^{i,j,k}, J.C. Hutchinson, PhD^{i,j,k}, O.J. Arthurs, PhD^{i,j,k}, V. Luis Fuentes, VetMB, PhD^b

^a Department of Veterinary Medicine, University of Cambridge, Madingley Road, CB3 0ES, Cambridge, UK

^b Clinical Science and Services, Royal Veterinary College, Hawkshead Lane, Hatfield, Hertfordshire, AL9 7TA, London, UK

^c Southern Counties Veterinary Specialists, Unit 6, Forest Corner Farm, Hangersley, BH24 3JW, Ringwood, Hampshire, UK

^d North Downs Specialist Referrals, The Friesian Buildings 3 & 4, Brewer Street, RH1 4QP, Bletchingley, Surrey, UK

^e Langford Vets Small Animal Referral Hospital, University of Bristol, Langford House, BS40 5DU, Langford, UK

^f Animal Referral Centre, 224 Albany Highway, Schnapper Rock, 0632, Auckland, New Zealand

^g Ospedale Veterinario San Francesco, Via Feltrina, 29, 31038, Castagnole, Milan, Italy

^h Freelance Cardiology, Salstrasse 92, 8400, Winterthur, Switzerland

ⁱ Department of Clinical Radiology, Great Ormond Street Hospital for Children, Great Ormond Street, WC1N 3JH, London, UK

^j UCL Great Ormond Street Institute of Child Health, Great Ormond Street Hospital for Children, Great Ormond Street, WC1N 3JH, London, UK

^k NIHR Great Ormond Street Hospital Biomedical Research Centre, Great Ormond Street Hospital Biomedical Research Centre, London, UK

Received 22 February 2022; received in revised form 30 January 2023; accepted 8 February 2023

[☆] The results of this study were partially presented as a poster at the 31st ECVIM Annual Congress 2021.

^{☆☆} A unique aspect of the Journal of Veterinary Cardiology is the emphasis of additional web-based images permitting the detailing of procedures and diagnostics. These images can be viewed (by those readers with subscription access) by going to <http://www.sciencedirect.com/science/journal/17602734>. The issue to be viewed is clicked and the available PDF and image downloading is available via the Summary Plus link. The supplementary material for a given article appears at the end of the page. Downloading the videos may take several minutes. Readers will require at least Quicktime 7 (available free at <http://www.apple.com/quicktime/download/>) to enjoy the content. Another means to view the material is to go to <http://www.doi.org> and enter the doi number unique to this paper which is indicated at the end of the manuscript.

* Corresponding author.

E-mail address: jms330@cam.ac.uk (J. Novo Matos).

KEYWORDS

Infarct;
Hypertrophic cardiomyopathy;
Fibrosis;
Cardiomyopathy of non-specific phenotype;
Micro-CT

Abstract *Introduction/objectives:* Thin and hypokinetic myocardial segments (THyMS) represent adverse ventricular (LV) remodeling in human hypertrophic cardiomyopathy. We describe the echocardiographic features and outcome in cats with THyMS, and in a subpopulation, the echocardiographic phenotype before LV wall thinning was detected (pre-THyMS).

Animals: Eighty client-owned cats.

Materials and methods: Retrospective multicenter study. Clinical records were searched for cats with THyMS, defined as LV segment(s) with end-diastolic wall thickness (LVWT) <3 mm and hypokinesis in the presence of \geq one LV segment(s) with LVWT >4 mm and normal wall motion. When available, echocardiograms pre-THyMS were assessed. Survival time was defined as time from first presentation with THyMS to death.

Results: Mean thickest LV wall segment (MaxLVWT) was 6.1 mm (95% CI 5.8–6.4 mm) and thinnest (MinLVWT) was 1.7 mm (95% CI 1.6–1.9 mm). The LV free wall was affected in 74%, apex in 13% and septum in 5%. Most cats (85%) presented with heart failure and/or arterial thromboembolism. Median circulating troponin I concentration was 1.4 ng/mL ([range 0.07–180 ng/mL]). Prior echocardiography results were available for 13/80 cats, a mean of 2.5 years pre-THyMS. In segments subsequently undergoing thinning, initial MaxLVWT measured 6.7 mm (95% CI 5.8–7.7 mm) vs. 1.9 mm (95% CI 1.5–2.4 mm) at last echocardiogram ($P < 0.0001$). Survival data were available for 56/80 cats, median survival time after diagnosing THyMS was 153 days (95% CI 83–223 days). Cardiac histopathology in one cat revealed that THyMS was associated with severe transmural scarring.

Conclusions: Cats with THyMS had advanced cardiomyopathy and a poor prognosis.

© 2023 The Author(s). Published by Elsevier B.V. This is an open access article under the CC BY license (<http://creativecommons.org/licenses/by/4.0/>).

Introduction

Cardiomyopathies are the most common acquired heart diseases in cats, and hypertrophic cardiomyopathy (HCM) is the most prevalent phenotype [1,2].

Hypertrophic cardiomyopathy is phenotypically heterogeneous in both humans and cats. It is characterized by a spectrum of morphological changes with left ventricular (LV) hypertrophy ranging from mild to severe, and focal to diffuse. It can affect any LV segment with varying severity of thickening [3–5].

Adverse cardiac remodeling with marked fibrosis and progressive LV wall thinning has been described in 15–20% of HCM cases in people [5–8] and is considered a serious complication of this disease [5,8,9]. Regional LV wall thinning is caused by transmural myocardial fibrosis in the absence of extramural coronary artery disease [5,9–11]. It appears to be caused by silent and chronic myocardial ischemia [10–12]. In people, it is not typically associated with the common symptoms of myocardial infarcts caused by atherosclerosis of extramural coronary arteries, such as marked diffuse chest pain, diaphoresis, or nausea [13]. It is, instead, associated with development or worsening of congestive heart failure (CHF) [5,9].

Localized LV wall thinning is also occasionally observed in cardiomyopathic cats and anecdotally the left ventricular free wall (LVFW) seems to be most commonly affected. Moreover, regional LV wall thinning and hypokinesis was associated with a worse outcome in cats with HCM [14]. A recent large study has shown that cats with HCM had a mean survival of 1.3 years after developing CHF and/or arterial thromboembolism (ATE) [15], but this most likely reflects the outcome of a general population in stage C with different HCM severities and risk factors. There is scarce outcome data in cats with end-stage/advanced forms of HCM.

The aims of this study were to describe the clinical and echocardiographic features of cats with thin and hypokinetic myocardial segments (THyMS) and their outcome. Additionally, we aimed to evaluate the initial echocardiographic phenotype (pre-THyMS echo) in any available previous echocardiographic studies in cats subsequently identified as having THyMS.

Materials and methods

The clinical records and echocardiographic databases of eight referral centers were searched between 2013 and 2021 for cats with THyMS,

Abbreviations

2D	two-dimensional
ATE	arterial thromboembolism
CHF	congestive heart failure
CI	confidence interval
HCM	hypertrophic cardiomyopathy
LA	left atrium
LA/Ao	left atrium to aorta ratio
LV	left ventricular
LVFS%	LV fractional shortening
LVFW	LV free wall
MaxLVWT	maximal end-diastolic LV wall thickness
MinLVWT	end-diastolic LV wall thickness of LV thin segment
RPLA	right parasternal long-axis view
RPSA	right parasternal short-axis view
SAM	systolic anterior motion of the mitral valve
THyMS	thin and hypokinetic myocardial segment

search terms included 'end-stage HCM', 'infarct', 'hypokinesis', 'akinesis', and 'aneurysm'. Thin and hypokinetic myocardial segments were defined as left ventricular (LV) segment(s) with end-diastolic wall thickness (LVWT) <3 mm and severe hypokinesis in the presence of at least one LV segment with LVWT >4 mm and normal wall motion. Thin LV segments were defined as <3 mm, as this is below the mean predicted LVWT for cats with body weight between 2.0 and 8.0 kg [16]. Severe hypokinesis was defined as a LV segment with no myocardial systolic thickening, and normal wall motion was defined as a systolic myocardial thickening >50% [17,18].

Echocardiographic data

All echocardiographic exams were reviewed and remeasured by an European College of Veterinary Internal Medicine and American College of Veterinary Internal Medicine (ECVIM) or ACVIM board-certified cardiologist and further reviewed by one observer (JNM) at the time of study entry to ensure the inclusion criteria were met. Interventricular septum thickness was measured by a leading edge-to-trailing edge technique and LVFW by a leading edge-to-leading edge technique from a two-dimensional (2D) right parasternal long-axis four- or five-chamber view (RPLA) and a short-axis view at the papillary muscle level (RPSA), as the

averages of the thickest and thinnest end-diastolic segments on three different cardiac cycles in each view (RPLA and RPSA) [19]. End-diastolic frames were defined as the first frame after mitral valve closure in RPLA and as the time point in the cardiac cycle of greatest LV internal diameter in RPSA [1]. The maximal averaged end-diastolic wall thickness from either the interventricular septum or LVFW on these two views was recorded and used for data analysis as MaxLVWT. The averaged LV wall thickness of THyMS was recorded and defined as MinLVWT. The location of THyMS was defined as septal, free wall or apical based on the affected LV segment in RPLA and RPSA views. The extension of THyMS in the septal and free wall segments was assessed in RPLA and defined as diffuse when >50% of the segment was affected or focal when <50% of the segment showed thinning. Systolic excursion of THyMS and myocardial segments with LVWT >4 mm was measured by guiding the M-mode cursor across the respective LV segment and measure its displacement between end-diastole and end-systole using electronic calipers (Fig. 1). In cats with echocardiographic exams available before THyMS was detected (pre-THyMS echo), we attempted to measure the exact LV segment that subsequently developed wall thinning (THyMS). Cardiac chambers were measured in 2D by a trailing-to-leading edge technique. Left ventricular internal diameter in diastole was measured in 2D from a RPLA and RPSA view at the level of the chordae tendineae, in an end-diastolic frame, in three different cardiac cycles in each view. The averaged LV internal diameter in diastole on each of these two views was recorded, and the highest value was used for data analysis. Left atrial linear dimensions were measured as left atrium (LA) to aorta ratio (LA/Ao) and left atrial diameter. The LA/Ao was measured as the ratio of the LA to aorta measured in 2D from a short-axis view at the heart base, in the frame after aortic valve closure [20]. The left atrial diameter was measured as the cranial–caudal left atrial dimension from a RPLA four-chamber view, in the frame before mitral valve opening [21]. Left atrial and LV fractional shortening (LVFS%) were measured by M-mode from a right parasternal short-axis RPSA at the heart base and RPSA at the papillary muscle level, respectively [20]. Mitral inflow was assessed by pulsed-wave Doppler at the tip of the mitral valve leaflets in a left apical four-chamber view. Mitral annular plane systolic excursion was measured by M-mode at the septal and lateral mitral annulus from a left apical four-chamber view, as previously described [22].

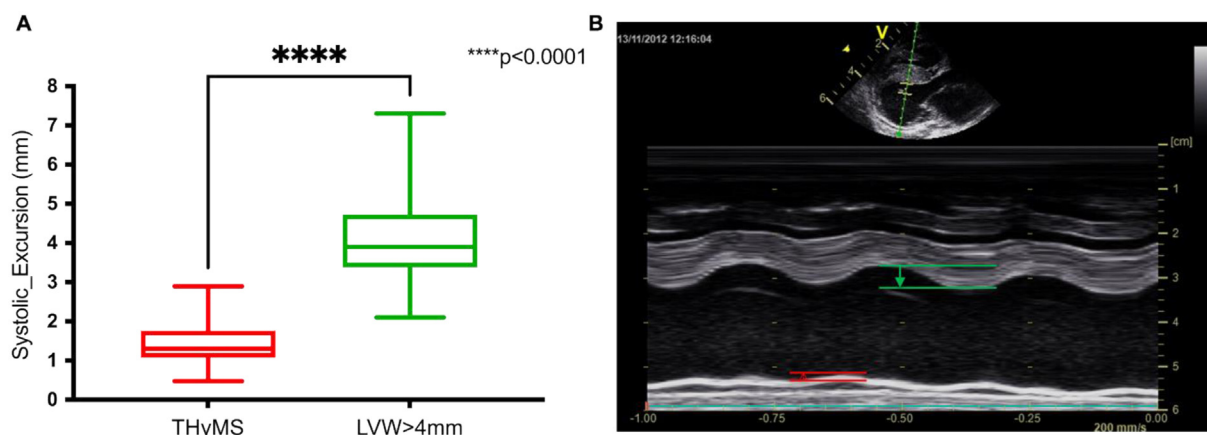


Figure 1 (A) Systolic excursion in thin and hypokinetic myocardial segments (THyMS) and left ventricular segments with a wall thickness >4 mm (LVW > 4 mm). Systolic excursion in THyMS was reduced in comparison with non-thin segments (1.3 mm [0.5–2.9 mm] vs. 3.9 mm [2.1–7.3 mm], $P<0.0001$). (B) Left ventricular M-mode across the left ventricular free wall in a cat with THyMS.

The presence of systolic anterior motion of the mitral valve (SAM) was assessed in a RPLA five-chamber view and defined as systolic anterior motion of the tip of the anterior mitral valve leaflet toward the septum, associated with turbulent flow in the LV outflow tract documented on color flow Doppler. The presence of spontaneous echocardiographic contrast and/or thrombus in the LA was also recorded.

An HCM phenotype was defined as diffuse or regional LVWT ≥ 6 mm, and the term ‘cardiomyopathy of non-specific phenotype’ was used when LVWT was <6 mm [19].

Clinical data

Additional data collected from the medical records included body weight, age, sex, breed, heart rate, presence of a murmur, gallop or arrhythmia, systolic blood pressure, presenting clinical signs, circulating cardiac troponin I concentrations, and presence of concurrent systemic diseases. No attempt was made to quantify arrhythmia frequency or malignancy, as only brief ECG descriptions were available. Cardiomyopathy stage [19] and treatment administered were recorded. Cats presented with CHF and/or ATE were classified as stage C, while cats without clinical signs were classified as stage B [19]. The latter was subdivided into stage B1 when the LA/Ao ≤ 1.6 , and stage B2 when LA/Ao >1.6 .

Survival (cardiac mortality) data

Medical records were reviewed for information on cause and date of death. Cardiac death was defined as sudden death or euthanasia for CHF or

ATE. Sudden death was defined as an unexpected death without any clinical signs in the preceding 24 h [23]. Survival time (cardiac mortality) was determined for cats with THyMS as the time from first presentation with THyMS to cardiac death or to last date known to be alive.

Microfocus computed tomography was performed in one cat, as previously described [24].

Statistical analysis

Descriptive statistics were generated for all study variables. Data were tested for normality graphically and by Shapiro–Wilk test. Normally distributed data are reported as mean (95% confidence interval, 95% CI) and non-normally distributed data as median [range]. Categorical data are presented as frequency and percentage. In cases where data were missing, the number of cats available for analysis is reported. Within-group comparisons (pre-THyMS vs. THyMS) were analyzed with a paired Student’s *t* test for continuous variables and McNemar’s test for categorical variables. Kaplan–Meier method was used to calculate median survival time and 95% confidence interval. Survival time (cardiac mortality) was defined as time from first presentation with THyMS to cardiac death in days. Cats with non-cardiac deaths (with survival included up to the point of death), cats still alive at the end of study, and cats with more than one visit but still alive at the last visit were right-censored. A Kaplan–Meier curve was also generated for the subpopulation of cats with an echocardiogram pre-THyMS depicting the time from baseline echocardiogram (pre-THyMS) to event (THyMS).

P values < 0.05 were considered statistically significant. Statistical analysis was performed using commercially available software^{l,m}

Results

Eighty cats with THyMS were identified in eight referral centers, 13 cats of which had echocardiograms available prior to development of a thin and hypokinetic myocardial segment (pre-THyMS). Mean age at the time of diagnosis of THyMS was 9.9 years (95% CI 9.3–10.6 years), and the majority were male (63/80 cats, 79%). Most cats were non-pedigree (61/80 cats, 76%), and Sphynx cats were the most common pedigree breed (7/80 cats, 9%). Arrhythmias (54/76 cats, 71%) and gallop sounds (33/73, 45%) were common. Most cats were in stage C: 59/80 (74%) had CHF, 3/80 (4%) had ATE, and 6/80 (8%) had CHF and ATE, while 12/80 (15%) cats were in stage B at the time of THyMS diagnosis. One cat was in stage B1, and 11/12 cats in stage B2 (mean LA/Ao 2.2 (95% CI 2.0–2.4)). [Table 1](#) summarizes the clinical characteristics of the study population.

Echocardiographic data

Mean THyMS wall thickness (MinLVWT) was 1.7 mm (95% CI 1.6–1.9 mm), while the mean thickest LV myocardial segment (MaxLVWT) at end-diastole was 6.1 mm (95% CI 5.8–6.4 mm). Eighteen cats had a MaxLVWT under 5 mm (mean 4.3 mm, 95% CI 4.0–4.6 mm). The LV free wall was the location most commonly affected by wall thinning (59/80 cats, 74%), followed by the LV apex. The septum was the less commonly affected segment (4/80 cats, 5%) ([Table 2](#), [Figs. 2 and 3](#), Videos 1–3). Myocardial wall thinning affected the whole LV segment (diffuse thinning from the mitral annulus to LV apex) in 47/59 (80%) cats with THyMS at the LV free wall and in 1/4 cat with septal THyMS. All THyMS had reduced systolic excursion in comparison with the non-thin LV segments ([Fig. 1](#), Videos 1–3). Systolic excursion was not determined in THyMS at the LV apex, as an adequate alignment between the apical segment and M-Mode cursor was not possible. Similarly, it was not possible to measure THyMS wall thickness (MinLVWT) in five cats with THyMS affecting the LV apex (apical aneurysm), as the apical wall was extremely thin. Left ventricular fractional shortening was reduced

Table 1 Clinical characteristics at presentation in cats with a thin and hypokinetic myocardial segment (THyMS) (n = 80 unless otherwise stated).

Body weight (kg) (n = 71)	4.8 (4.5–5.0)
SBP (mmHg) (n = 47)	122 (115–129)
Breed	
Nonpedigree cats	61/80 cats (76%)
Sphynx	7/80 cats (9%)
Maine Coon	3/80 cats (4%)
Other	9/80 cats (11%)
cTnl (ng/mL) (n = 40)	1.4 [0.07–180]
Arrhythmia (n = 76)	54/76 cats (71%)
VPCs (isolated)	41/54 cats (76%)
Nonsustained ventricular tachycardia	5/54 cats (9%)
Atrial fibrillation	5/54 cats (9%)
APCs	2/54 cats (4%)
SVT	1/54 cats (2%)
Gallop (n = 73)	33/73 cats (45%)
Murmur (n = 74)	18/74 cats (24%)
Clinical signs	
Asymptomatic	12/80 cats (15%)
CHF	59/80 cats (74%)
Pulmonary edema	23/59 cats (39%)
Pleural effusion	19/59 cats (32%)
Both	19/59 cats (32%)
ATE	3/80 cats (4%)
CHF + ATE	6/80 cats (8%)
Comorbidities	Hyperthyroidism (5 cats)
	Asthma (2 cats)
	Other (5 cats)

Continuous variables are reported as mean (95% confidence interval), and categorical variables are reported as frequency and percentage. Other breeds: 1 cat of each breed: Bengal, British shorthair, Burmese, Persian, Ocicat, Oriental, Russian Blue; Other comorbidities: chronic kidney disease (2 cats), cholangiohepatitis (1 cat), acute kidney injury (1 cat), alimentary lymphoma (1 cat).

APCs: atrial premature complexes; ATE: arterial thromboembolism; CHF: congestive heart failure; cTnl: cardiac troponin I; n = number of cats with available data; SBP: systolic blood pressure; SVT: supraventricular tachycardia; VPCs: ventricular premature complexes.

(median LVFS% 20.1% [range 5.2%–43%]) and SAM was uncommon (6/80 cats, 8%). Most cats had severe LA enlargement with reduced LA fractional shortening. A thrombus and/or spontaneous echocardiographic contrast in the LA was identified in 46/80 (58%) cats. Forty-two (42/80, 53%) cats had an HCM phenotype (mean MaxLVWT 7.1 mm (95% CI 6.9–7.30 mm)), and 38/80 cats had a cardiomyopathy of non-specific phenotype (mean MaxLVWT 5.0 mm (95% CI 4.7–5.2 mm) and mean LVFS% 22% (95% CI 19%–24%, range 11–41%). [Table 2](#) summarizes the echocardiographic findings of the whole study population

^l SPSS 25–26, 2018–2019.

^m GraphPad Prism 9.3.1, 2021.

Table 2 Echocardiographic variables in cats with a thin and hypokinetic myocardial segment (THyMS) (n = 80 unless otherwise stated).

Max LVWTD (mm)	6.1 (5.8–6.4)
Max LVWTD \geq 6 mm (42/80 cats)	7.1 (6.9–7.3)
LVIDd (mm) (n = 78)	21.1 (20.4–21.9)
THyMS thickness (mm) (n = 75)	1.7 (1.6–1.9)
THyMS	
LVFW	59/80 (74%)
Apical	10/80 (13%)
LVFW + apical	7/80 (9%)
IVS	4/80 (5%)
LVFS% (n = 74)	20.1 [5.2–43]
LA/Ao (n = 77)	2.4 [1.3–4.5]
LAD (mm) (n = 78)	22 [15.2–34]
LAFS% (n = 75)	7.0 [1.0–26]
MAPSE_IVS (mm) (n = 38)	2.3 [1.2–6.9]
MAPSE_LVFW (mm) (n = 31)	2.4 (2.0–2.8)
Systolic_Excursion_THyMS (mm) (n = 62)	1.3 [0.5–2.9]
Systolic_Excursion_nonTHyMS (mm) (n = 62)	3.9 [2.1–7.3]
SAM	6/80 cats (8%)
SEC	38/80 cats (48%)
LAA thrombus	8/80 cats (10%)
Pericardial effusion	28/80 cats (35%)
Mitral regurgitation	48/77 cats (62%)
MV E/A (n = 29)	3.1 (2.6–3.6)

Continuous variables are reported as mean (95% confidence interval) or median [range], and categorical variables are reported as frequency and percentage.

IVS: interventricular septum; LAA: left atrial appendage; LAD: left atrial diameter; LVFW: left ventricular free wall; LAFS%: left atrial fractional shortening; LVFS%: left ventricular fractional shortening; LVIDd: left ventricular internal diameter at end-diastole; MAPSE: mitral annular plane systolic excursion; Max LVWTD: maximal end-diastolic left ventricular wall thickness; MV E/A: mitral valve inflow ratio; n = number of cats with available data; THyMS: thin and hypokinetic myocardial segment; SAM: systolic anterior motion of the mitral valve; SEC: spontaneous echocardiographic contrast.

Thirteen cats had an echocardiogram performed a mean of 2.5 years (95% CI 1.3–3.7 years) before THyMS was detected (pre-THyMS) (Fig. 4, Video 4). Eleven (11/13) cats had HCM (mean MaxLVWT 7.5 mm (95% CI 6.7–8.3 mm)) on the first scan. Mean LVWT in the myocardial segments developing wall thinning was 6.7 mm (95% CI 5.8–7.7 mm) pre-THyMS and decreased to 1.9 mm (95% CI 1.5–2.4 mm) ($P < 0.0001$) (Figs. 5 and 6). In this subgroup, 9/13 cats had myocardial wall thinning affecting the whole LVFW (diffuse thinning from the mitral annulus to LV apex), 2/13 cats had focal LVFW thinning, and 2/13 cats had THyMS at the LV apex. All cats had other LV

segments that did not undergo wall thinning and wall thickness remained stable over time. Left ventricular ($P = 0.014$) and LA fractional shortening decreased ($P = 0.015$) and LA size increased (LA/Ao, $P = 0.042$; LA diameter, $P = 0.013$) with the development of LV wall thinning (Fig. 5). Seven of nine cats with SAM at initial presentation did not have SAM ($P = 0.016$) at the time THyMS was diagnosed. Table 3 summarizes the characteristics on the subpopulation of cats with examinations pre-THyMS.

One cat with THyMS affecting the LVFW was euthanized due to refractory CHF and their owner consented to a post-mortem microfocus computed tomography and routine pathology examination. On microfocus computed tomography, there was severe LVFW thinning associated with transmural replacement fibrosis (Fig. 7, Video 5). The latter was identified as large hypodense areas, as previously described [24]. There were no morphological abnormalities in the extramural coronary arteries associated with THyMS, and there was no evidence of thromboembolic events obstructing a main coronary artery. On histopathology, there was severe transmural scarring with replacement fibrosis of the LVFW with some areas predominantly composed of fibrofatty tissue with small amounts of remaining myocardium (Fig. 7). There was myofiber disarray and myocyte hypertrophy within the LVFW and septum. The intramural coronary arterioles walls were thickened (arteriosclerosis/small vessel disease). There were no signs of myocardial inflammation. Histological findings were suggestive of HCM with transmural LVFW scarring.

Treatment data

Sixty-five cats were in stage C (CHF), 54/65 (83%) cats received furosemide, and 12/65 (18%) cats received torasemide. Sixty-one cats (61/80, 76%) were receiving pimobendan and 65/80 (81%) cats were treated with clopidogrel. These were started at the initial presentation with THyMS. Other drugs included in the treatment regime of the study population included sotalol, amiodarone, diltiazem, thiazides, aspirin, spironolactone, and rivaroxaban.

Survival (cardiac mortality) data

Survival data were available for 56 cats (24 cats had only an initial visit recorded and no outcome data available). Forty cats experienced a cardiac death: 5/40 (12.5%) had sudden death, while 35/40 (87.5%) cats were euthanized due to CHF or ATE.

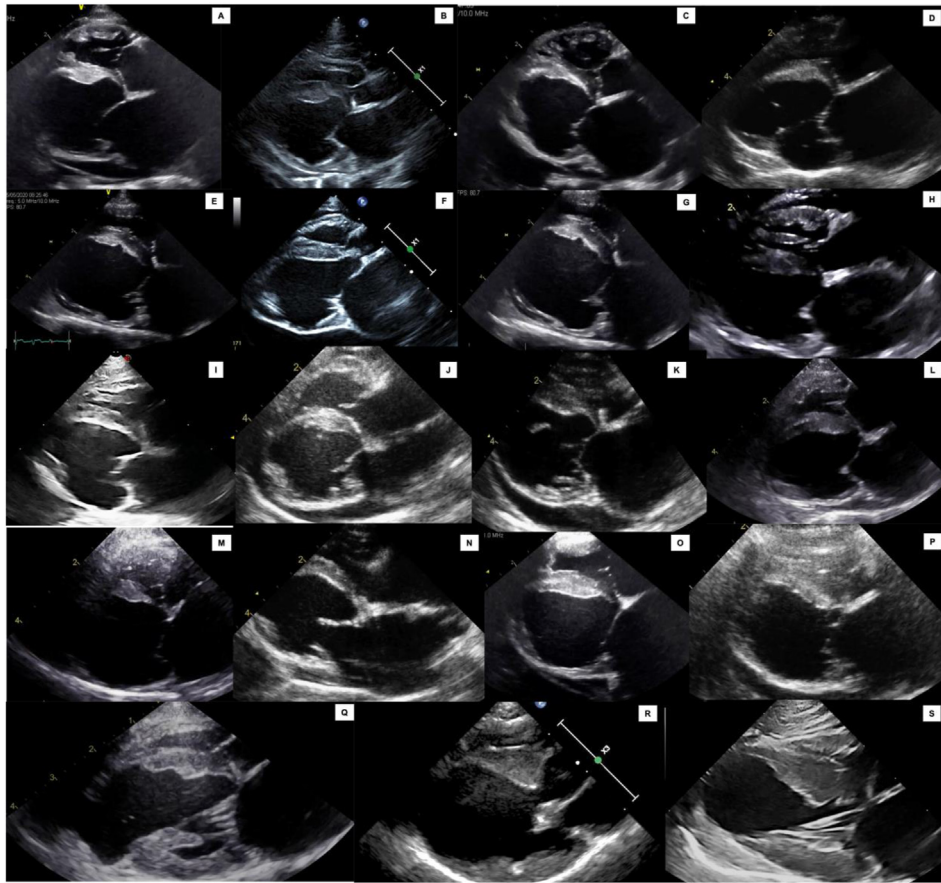


Figure 2 Representative right parasternal long-axis views of cats enrolled in the study. (A–P) Sixteen cats with a thin and hypokinetic myocardial segment (THyMS) affecting the left ventricular free wall. (Q–S) Three cats with THyMS affecting the left ventricular apex.

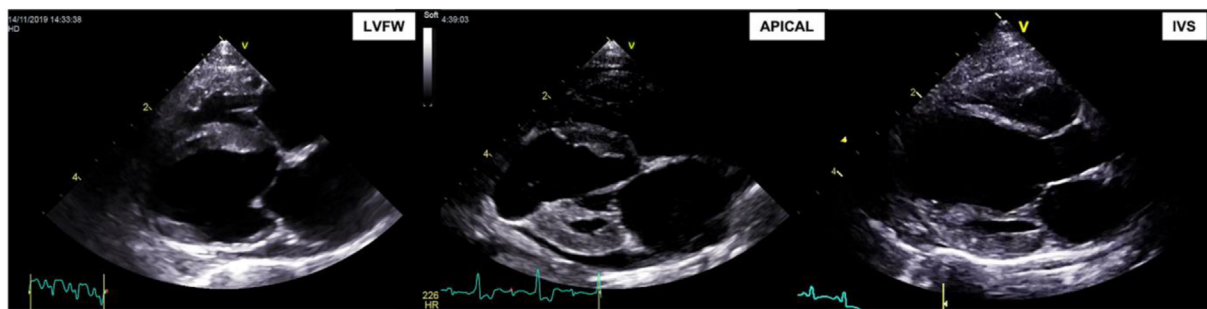


Figure 3 Thin and hypokinetic left ventricular segment affecting the left ventricular free wall (LVFW), apex (APICAL), and interventricular septum (IVS) in three different cats.

Three cats died of non-cardiac reasons. Median survival time (cardiac death) from first presentation with THyMS was 153 days (95% CI 83–223 days).

Discussion

We describe in this case series the clinical characteristics and echocardiographic features of cats

with cardiomyopathy presenting with THyMS. Our findings show that THyMS most frequently affected the LVFW. Thin and hypokinetic myocardial segments were observed in cases of advanced cardiomyopathy with severe clinical signs and poor outcome. A subcohort of our population (13/80 cats) had echocardiograms performed pre-THyMS, and in the majority, an HCM phenotype preceded LV wall thinning (Fig. 6, Video 4). Microfocus

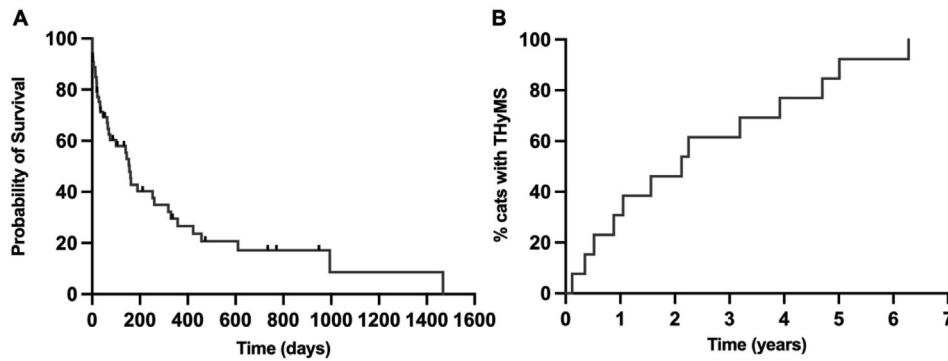


Figure 4 (A) Kaplan–Meier curve showing survival time (cardiac mortality) in cats after a thin and hypokinetic myocardial segment (THyMS) was diagnosed on echocardiography. Median survival in cats with advanced cardiomyopathy and THyMS was 153 days. (B) Kaplan–Meier curve showing percentage of cats developing THyMS over time in a subset of 13 cats that had an echocardiography pre-THyMS.

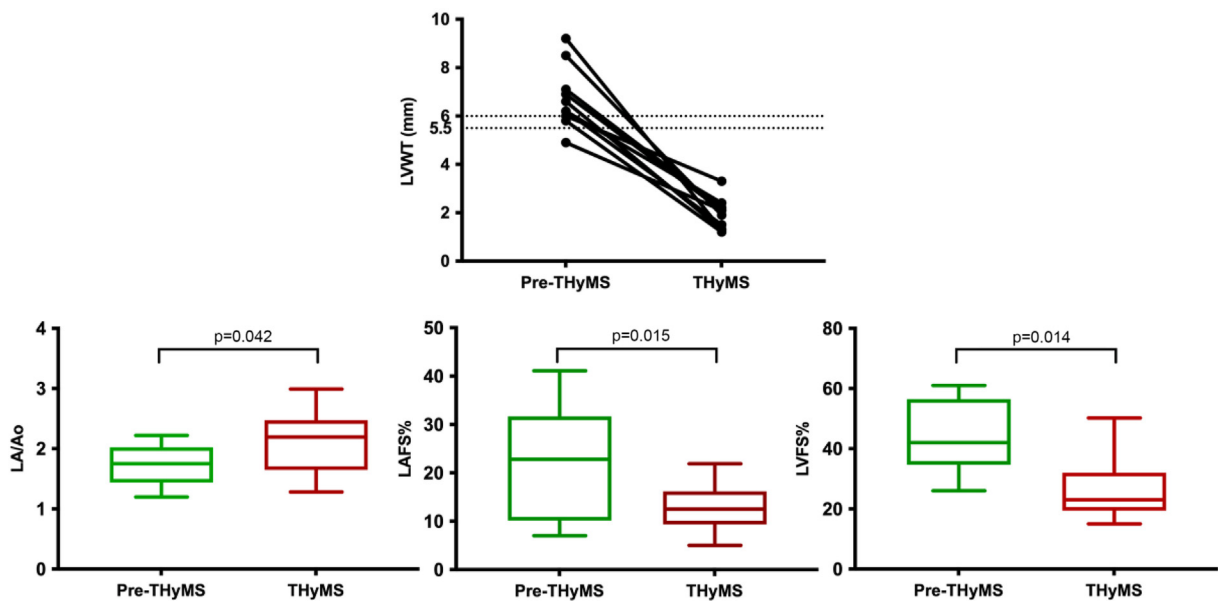


Figure 5 Left ventricular wall thickness (LVWT), left atrial size (LA/Ao), left atrial fractional shortening (LAFS%), and left ventricular fractional shortening (LVFS%) in 13 cats before (pre-THyMS) and after (THyMS) developing a thin and hypokinetic myocardial segment.

computed tomography and post-mortem examination in one cat showed that THyMS was associated with severe transmural scarring, suggesting a prior severe myocardial insult (such as ischemic damage).

In humans, diffuse or focal transmural LV myocardial scarring is sometimes seen in HCM patients [10,11]. This represents adverse cardiac remodeling caused by silent, chronic myocardial ischemia which results in myocardial replacement fibrosis, LV wall thinning, and systolic dysfunction [10–12,25]. Such adverse remodeling characterized by LV systolic dysfunction, severe LA enlargement, atrial fibrillation, reduction, or loss of SAM and LV wall thinning may occur in up to

15–20% of human patients with HCM [6–8]. The mechanism behind regional transmural LV scarring in people with HCM is not clear, as this typically occurs in the absence of extramural coronary artery disease [9,10]. Several mechanisms have been suggested, such as thromboembolism of a coronary artery, coronary spasm, oxygen supply/demand mismatch in thick myocardial LV segments, small vessel coronary artery disease (arteriolosclerosis), myocardial fibrosis caused by apoptosis, and neurohormonal changes [5,10,26–29]. Progressive and silent microvascular ischemia with subsequent replacement fibrosis might be the most likely mechanism of LV wall thinning in HCM [29] and could be caused by a

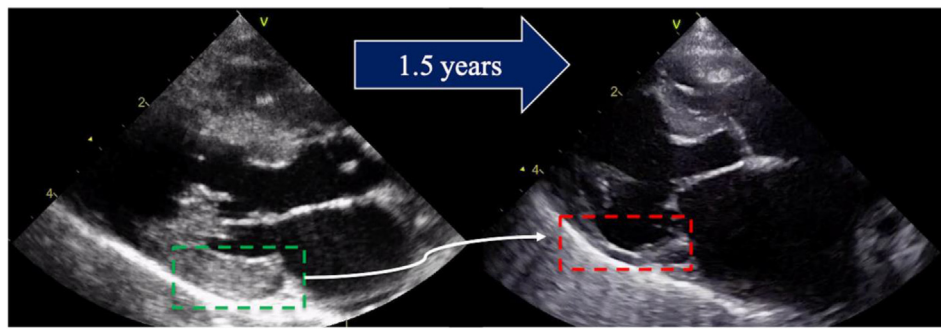


Figure 6 Right parasternal long-axis view in the same cat 1.5 years apart showing left ventricular free wall thinning over time.

combination of several factors, including increased oxygen demand associated with LV hypertrophy, microvascular dysfunction associated with small vessel disease, and LV outflow tract obstruction [8,12,29]. A chronic, slow, and silent process is corroborated by the typical absence of acute clinical signs of infarction in HCM cases with LV wall thinning and adverse remodeling, and instead, signs of advanced CHF [9,29–31].

The cases here described had advanced cardiomyopathy characterized by severe left atrial enlargement, LV systolic and diastolic dysfunction,

LV dilation, frequent ventricular arrhythmias, marked increase in cardiac troponin I, and a majority presenting with clinical signs of CHF and/or ATE. Considering that 53% (42/80) of cats with THyMS had HCM, 85% (11/13) of cats had HCM 2.5 years before developing THyMS, and one representative cat had histological hallmarks of HCM, namely myocardial disarray, myocyte hypertrophy, arteriosclerosis, and fibrosis, the cases we report here could represent an advanced form of HCM where adverse remodeling with THyMS has occurred. Although 46% of cats had a non-specific cardiomyopathy phenotype and might have had

Table 3 Clinical and echocardiographic variables in cats before (pre-THyMS) and after developing a thin and hypokinetic myocardial segment (THyMS) (n = 13 unless otherwise stated).

	pre-THyMS	THyMS	P value
Age (yrs)	6.6 (4.5–8.7)	9.1 (7.6–10.6)	
Heart murmur	9/13	5/13	0.219
VPCs	2/13	6/13	0.125
Clinical signs			
Asymptomatic	11/13	6/13	0.063
CHF	2/13	7/13	0.063
Echocardiography			
Time between scans (yrs)	2.5 (1.3–3.7)		
Max LVWTd (mm)	7.5 (6.7–8.3)	6.9 (6.2–7.7)	0.104
THyMS thickness (mm)	6.7 (5.8–7.7)	1.9 (1.5–2.4)	<0.0001
THyMS			
LVFW	NA	11/13	
Apical	NA	2/13	
LVIDd (mm) (n = 9)	17.9 (14.7–21.1)	20.9 (18.1–23.6)	0.179
LVFS% (n = 9)	45 (36–55)	26 (18–35)	0.014
LA/Ao (n = 12)	1.7 (1.5–1.9)	2.1 (1.8–2.4)	0.042
LAD (n = 10)	19.1 (16.7–21.4)	22.3 (19.8–24.8)	0.013
LAFS% (n = 10)	22 (13–31)	12.8 (8.8–16.7)	0.015
SAM	9/13 (69%)	2/13 (15%)	0.016

Continuous variables are reported as mean (95% confidence interval), and categorical variables are reported as frequency and percentage.

NA: not applicable; n = number of cats with available data; Yrs: years.

VPCs: ventricular premature complexes; CHF: congestive heart failure; LVWTd: end-diastolic left ventricular wall thickness; THyMS: Thin and hypokinetic myocardial segments; LVFW: left ventricular free wall; LVIDd: left ventricular internal diameter at end-diastole; LVFS%: left ventricular fractional shortening; LAD: left atrial diameter; LAFS%: left atrial fractional shortening.

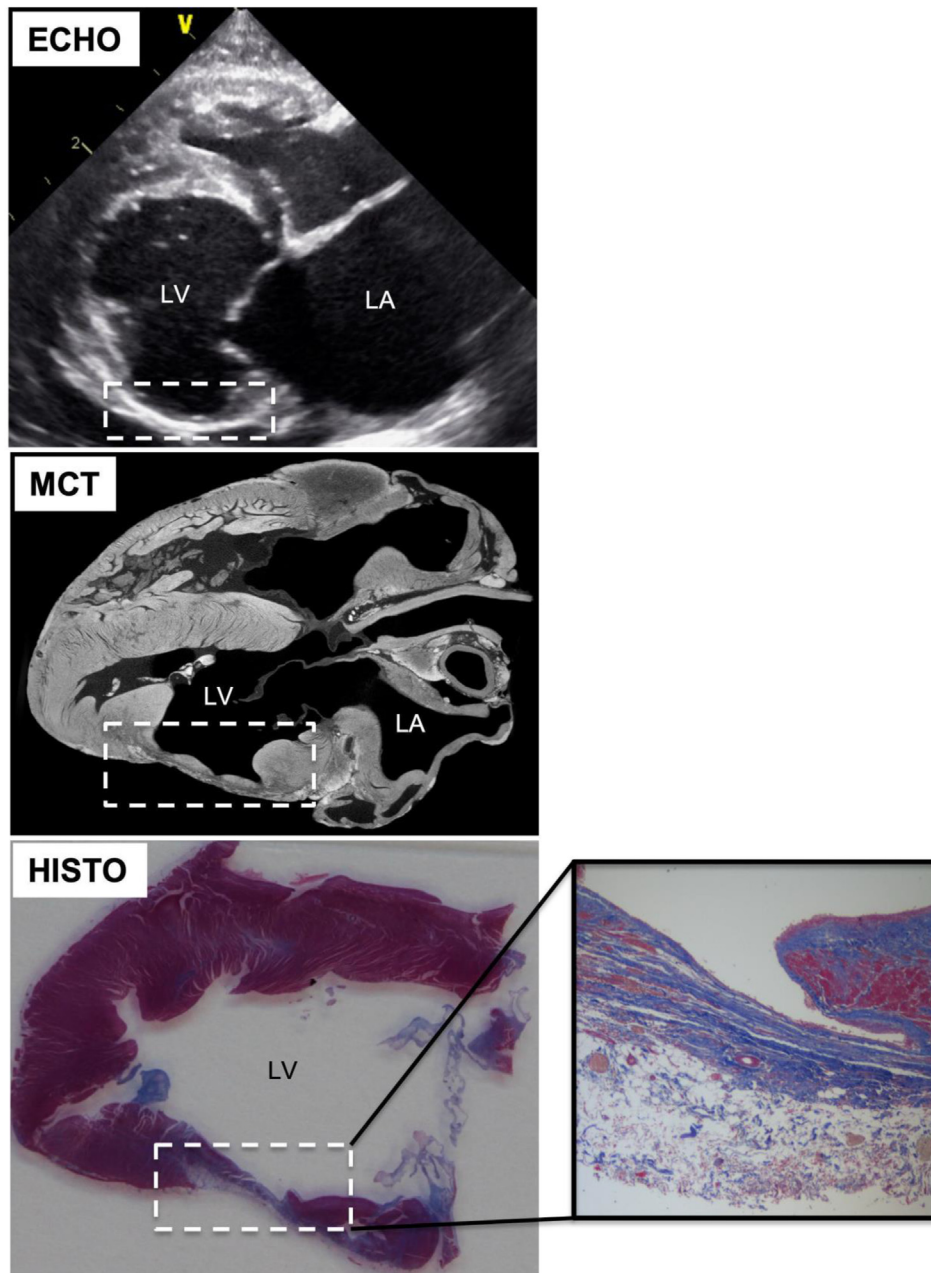


Figure 7 Left ventricular longitudinal views of a cat with a thin and hypokinetic myocardial segment affecting the left ventricular free wall. Echocardiography (ECHO), microfocus computed tomography (MCT), and histology (HISTO) showed that the thin and hypokinetic segment was caused by severe transmural myocardial fibrosis.

another type of cardiomyopathy, it is also possible that these cats had an HCM phenotype in the past. In humans, severe LV hypertrophy has an increased risk for adverse remodeling characterized by wall thinning [26,32]. In our study, most cats where an echocardiogram was available before LV wall thinning displayed marked LV hypertrophy prior to wall thinning [25,32].

There are scarce data on end-stage HCM in cats [33,34]. This has been characterized by LV dilation, LV systolic dysfunction, and wall thinning

over time, associated with extensive myocardial fibrosis [33,34]. In the present study, we described a cardiac phenotype characterized by isolated LV segments/regions with severe LV wall thinning, which differs from the diffuse LV involvement in previous reports of end-stage HCM.

In our population, THyMS most frequently affected the LVFW. Similarly, wall thinning associated with severe fibrosis was more frequently observed in the LVFW than the interventricular septum in a family of cats with end-stage HCM

[34]. It is presently unclear why the LVFW in cats seems more prone to fibrosis in cats with HCM. An apical aneurysm can develop in HCM patients with mid-ventricular obstruction [10,27]. In our cohort, two cats had an echocardiogram before developing an apical THyMS without obvious midventricular obstruction. A larger population would be required to explore this association further.

Based on the present data, THyMS was observed in cases of severe cardiomyopathy with a poor outcome. Similarly, a previous study has shown that regional wall hypokinesis, defined as a LV wall segment thinner than the other LV segments and with minimal systolic excursion, was associated with a high hazard of cardiac death in cats with HCM [14].

Our study has some limitations. The definition of normal and thin LV wall segments was arbitrary. Thin LV segments were defined as a regional LVWT at end-diastole <3 mm, which is below the mean predicted LVWT for cats weighing between 2.0 and 8.0 kg [16]. Moreover, thin segments had to show severe hypokinesis. Thus, it is unlikely for the described THyMS to represent normal myocardial segments. We only had post-mortem examinations in one cat, and thus, the etiology of THyMS remains unclear. We suspect THyMS to represent transmural myocardial scarring, where progressive myocardial ischemia associated with thick LV segments and small vessel disease resulted in transmural fibrosis, as suggested in people [5,9–12,25]. Most LV segments undergoing thinning were thick pre-THyMS, and thus, transmural replacement fibrosis by the mechanisms cited above seem plausible but cannot be proved in our study.

In the cats with pre-THyMS echo, we tried to match the echo views (pre-THyMS vs. THyMS echo) and measure the exact LV segment that developed thinning. But despite our best efforts, we might not have been able to measure the exact same region in each LV segment in the 4/13 cats with LVFW focal THyMS and apical THyMS.

We used LV%FS as a measurement of systolic function. But this is likely an inaccurate measure of global systolic function in markedly remodeled LVs. Thus, we cannot fully assess the degree of global systolic dysfunction in cats with advanced cardiomyopathy and THyMS.

Conclusions

In the present study, THyMS was observed in cats with an advanced cardiomyopathy phenotype with severe clinical signs and a poor prognosis. Left ventricular segments undergoing thinning were thick at initial evaluation. The cardiac phenotype

here described might represent a form of adverse remodeling as described in human HCM.

Conflicts of Interest Statement

The authors do not have any conflicts of interest to disclose.

Supplementary data

Supplementary data associated with this article can be found, in the online version, at <https://doi.org/10.1016/j.jvc.2023.02.002>.

Video 1	Right parasternal long- and short-axis views of a cat with a thin and hypokinetic left ventricular free wall.
Video 2	Right parasternal long-axis and left apical views of a cat with a thin and hypokinetic left ventricular apex (apical aneurysm).
Video 3	Right parasternal long-axis view of a cat with a thin and hypokinetic interventricular septum.
Video 4	Right parasternal long- and short-axis views in the same cat six years apart. Left ventricular free wall was thick in the first scan (left-hand side views, pre-THyMS) and marked wall thinning was observed six years later.
Video 5	Microfocus computed tomography of cat with hypertrophic cardiomyopathy and a thin and hypokinetic left ventricular free wall.

References

- [1] Payne JR, Brodbelt DC, Luis Fuentes V. Cardiomyopathy prevalence in 780 apparently healthy cats in rehoming centres (the CatScan study). *J Vet Cardiol* 2015;17:244–57.
- [2] Paige CF, Abbott JA, Elvinger F, Pyle RL. Prevalence of cardiomyopathy in apparently healthy cats. *J Am Vet Med Assoc* 2009;234:1398–403.
- [3] Wigle ED. The diagnosis of hypertrophic cardiomyopathy. *Heart* 2001;86:709–14.
- [4] Fox PR. Hypertrophic cardiomyopathy. clinical and pathologic correlates. *J Vet Cardiol* 2003;5:39–45.
- [5] Maron BJ, Epstein SE, Roberts WC. Hypertrophic cardiomyopathy and transmural myocardial infarction without significant atherosclerosis of the extramural coronary arteries. *Am J Cardiol* 1979;43:1086–102.
- [6] Olivetto I, Cecchi F, Poggesi C, Yacoub MH. Patterns of disease progression in hypertrophic cardiomyopathy. *Circ Heart Fail* 2012;5:535–46.

- [7] Olivetto I, Maron BJ, Appelbaum E, Harrigan CJ, Salton C, Gibson CM, Udelson JE, O'Donnell C, Lesser JR, Manning WJ, Maron MS. Spectrum and clinical significance of systolic function and myocardial fibrosis assessed by cardiovascular magnetic resonance in hypertrophic cardiomyopathy. *Am J Cardiol* 2010;106:261–7.
- [8] Soler R, Méndez C, Rodríguez E, Barriales R, Ochoa JP, Monserrat L. Phenotypes of hypertrophic cardiomyopathy. An illustrative review of MRI findings. *Insights Imaging* 2018;9:1–14.
- [9] Waller BF, Maron BJ, Epstein SE, Roberts WC. Transmural myocardial infarction in hypertrophic cardiomyopathy. A cause of conversion from left ventricular asymmetry to symmetry and from normal-sized to dilated left ventricular cavity. *Chest* 2016;79:461–5.
- [10] Fighali S, Krajcer Z, Edelman S, Leachman RD. Progression of hypertrophic cardiomyopathy into a hypokinetic left ventricle: higher incidence in patients with midventricular obstruction. *J Am Coll Cardiol* 1987;9:288–94.
- [11] Melacini P, Basso C, Angelini A, Calore C, Bobbo F, Tokajuk B, Bellini N, Smaniotto G, Zucchetto M, Iliceto S, Thiene G, Marron BJ. Clinicopathological profiles of progressive heart failure in hypertrophic cardiomyopathy. *Eur Heart J* 2010;31:2111–23.
- [12] Cardim N, Galderisi M, Edvardsen T, Plein S, Popescu BA, D'Andrea A, Bruder O, Cosyns B, Davin L, Donal E, Freitas A, Habib G, Kitsiou A, Petersen SE, Schroeder S, Lancellotti P, Camici P, Dulgheru R, Hagendorff A, Lombardi M, Muraru D, Sicari R. Role of multimodality cardiac imaging in the management of patients with hypertrophic cardiomyopathy: an expert consensus of the european association of cardiovascular imaging endorsed by the saudi heart association. *Eur Heart J Cardiovasc Imaging* 2015;16:280.
- [13] Thygesen K, Alpert JS, White HD. Universal definition of myocardial infarction. *J Am Coll Cardiol* 2007;50:2173–95.
- [14] Payne JR, Borgeat K, Connolly DJ, Boswood A, Dennis S, Wagner T, Menaut P, Maerz I, Evans D, Simons VE, Brodbelt DC, Luis Fuentes V. Prognostic indicators in cats with hypertrophic cardiomyopathy. *J Vet Intern Med* 2013; 27:1427–36.
- [15] Fox PR, Keene BW, Lamb K, Schober KA, Chetboul V, Luis Fuentes V, Wess G, Payne JR, Hogan DF, Motsinger-Reif A, Haggstrom J, Trehou-Sechi E, Fine-Ferreira DM, Nakamura RK, Lee PM, Singh MK, Ware WA, Abbott JA, Culshaw G, Riesen S, Borgarelli M, Lesser MB, Van Israel N, Côté E, Rush JE, Bulmer B, Santilli RA, Vollmar AC, Bossbaly MJ, Quick N, Bussadori C, Bright JM, Estrada AH, Ohad DG, Fernandez Del Palacio MJ, Brayley JL, Schwartz DS, Bove CM, Gordon SG, Jung SW, Brambilla P, Moise NS, Stauthammer CD, Stepien RL, Quintavalla C, Amberger C, Manczur F, Hung YW, Lobetti R, De Swarte M, Tamborini A, Mooney CT, Oyama MA, Komolov A, Fujii Y, Pariat R, Uechi M, Tachika Ohara VY. International collaborative study to assess cardiovascular risk and evaluate long-term health in cats with preclinical hypertrophic cardiomyopathy and apparently healthy cats: the reveal study. *J Vet Intern Med* 2018;32:930–43.
- [16] Schober KE, Stephanie S, Vedat Y. Reference intervals and allometric scaling of two-dimensional echocardiographic measurements in 150 healthy cats. *J Vet Med Sci* 2017;79: 1764–71.
- [17] Lang RM, Badano LP, Mor-Avi V, Afilalo J, Armstrong A, Ernande L, Flachskampf FA, Foster E, Goldstein SA, Kuznetsova T, Lancellotti P, Muraru D, Picard MH, Rietzschel ER, Rudski L, Spencer KT, Tsang W, Voigt JU. Recommendations for cardiac chamber quantification by echocardiography in adults: an update from the american society of echocardiography and the european association of cardiovascular imaging. *Eur Heart J Cardiovasc Imaging* 2015;16:233–70.
- [18] Pellikka PA, Arruda-Olson A, Chaudhry FA, Chen MH, Marshall JE, Porter TR, Sawada SG. Guidelines for performance, interpretation, and application of stress echocardiography in ischemic heart disease: from the american society of echocardiography. *J Am Soc Echocardiogr* 2019; 33:1–41.
- [19] Luis Fuentes V, Abbott J, Chetboul V, Côté E, Fox PR, Häggström J, Kittleson MD, Schober KE, Stern JA. ACVIM consensus statement guidelines for the classification, diagnosis, and management of cardiomyopathies in cats. *J Vet Intern Med* 2020;34:1062–77.
- [20] Abbott JA, MacLean HN. Two-dimensional echocardiographic assessment of the feline left atrium. *J Vet Intern Med* 2006;20:111–9.
- [21] Schober KE, Maerz I, Ludewig E, Stern JA. Diagnostic accuracy of electrocardiography and thoracic radiography in the assessment of left atrial size in cats: comparison with transthoracic two-dimensional echocardiography. *J Vet Intern Med* 2007;21:709–18.
- [22] Spalla I, Payne JR, Borgeat K, Pope A, Luis Fuentes V, Connolly DJ. Mitral annular plane systolic excursion and tricuspid annular plane systolic excursion in cats with hypertrophic cardiomyopathy. *J Vet Intern Med* 2017;31: 691–9.
- [23] Wilkie LJ, Smith K, Luis Fuentes V. Cardiac pathology findings in 252 cats presented for necropsy: a comparison of cats with unexpected death versus other deaths. *J Vet Cardiol* 2015;17:329–40.
- [24] Novo Matos J, Canadilla PG, Simcock IC, Hutchinson JC, Dobromylskyj M, Guy A, Arthurs OJ, Cook AC, Luis Fuentes V. Micro-computed tomography (micro-CT) for the assessment of myocardial disarray, fibrosis and ventricular mass in a feline model of hypertrophic cardiomyopathy. *Sci Rep* 2020;10:1–14.
- [25] Elliott PM, Anastasakis A, Borger MA, Borggrefe M, Cecchi F, Charron P, Hagege AA, Lafont A, Limongelli G, Mahrholdt H, McKenna WJ, Mogensen J, Nihoyannopoulos P, Nistri S, Pieper PG, Pieske B, Rapezzi C, Rutten FH, Tillmanns C, Watkins H. 2014 ESC guidelines on diagnosis and management of hypertrophic cardiomyopathy. The task force for the diagnosis and management of hypertrophic cardiomyopathy of the european society of cardiology (ESC). *Eur Heart J* 2014;35:2733–79.
- [26] Thaman R, Gimeno JR, Murphy RT, Kubo T, Sachdev B, Mogensen J, Elliott PM, McKenna WJ. Prevalence and clinical significance of systolic impairment in hypertrophic cardiomyopathy. *Heart* 2005;91:920–5.
- [27] Gravanis MB, Robinson PH, Hertzler GL. Hypertrophic cardiomyopathy evolving into a hypokinetic and dilated left ventricle: coronary embolization as a probable pathogenetic mechanism. *Clin Cardiol* 1990;13:500–5.
- [28] Ino T, Nishimoto K, Okubo M, Akimoto K, Yabuta K, Kawai S, Okada R, Sueyoshi N. Apoptosis as a possible cause of wall thinning in end-stage hypertrophic cardiomyopathy. *Am J Cardiol* 1997;79:1137–41.
- [29] Maron BJ, Spirito P. Implications of left ventricular remodeling in hypertrophic cardiomyopathy. *Am J Cardiol* 1998;81:1339–44.
- [30] Assenza GE, Spirito P, Musumeci MB, Lombardi M, Quarta G, Autore C. Severe left ventricular wall thinning and extensive fibrosis without evolution to end stage disease in a patient with hypertrophic cardiomyopathy. *J Am Soc Echocardiogr* 2009;22. 1196.e1-1196.

- [31] Ommen SR, Mital S, Burke MA, Day SM, Deswal A, Elliott P, Evanovich LL, Hung J, Joglar JA, Kantor P, Kimmelstiel C, Kittleson M, Link MS, Maron MS, Martinez MW, Miyake CY, Schaff HV, Semsarian C, Sorajja P. 2020 AHA/ACC guideline for the diagnosis and treatment of patients with hypertrophic cardiomyopathy a report of the american college of cardiology/american heart association joint committee on clinical practice guidelines. *J Am Coll Cardiol* 2020;76: 159–240.
- [32] Biagini E, Coccolo F, Ferlito M, Perugini E, Rocchi G, Bacchi-Reggiani L, Lofiego C, Boriani G, Prandstraller D, Picchio FM, Branzi A, Rapezzi C. Dilated-hypokinetic evolution of hypertrophic cardiomyopathy prevalence, incidence, risk factors, and prognostic implications in pediatric and adult patients. *J Am Coll Cardiol* 2005;46:1543–50.
- [33] Baty CJ, Malarkey DE, Atkins CE, DeFrancesco TC, Sidley J, Keene BW. Natural history of hypertrophic cardiomyopathy and aortic thromboembolism in a family of domestic shorthair cats. *J Vet Intern Med* 2001;15:595–9.
- [34] Cesta MF, Baty CJ, Keene BW, Smoak IW, Malarkey DE. Pathology of end-stage remodelling in a family of cats with hypertrophic cardiomyopathy. *Vet Pathol* 2005;42:458–67.

Available online at www.sciencedirect.com

ScienceDirect