

This is the peer-reviewed, manuscript version of the following article:

Hedley, J. (2016) 'Anatomy and Disorders of the Oral Cavity of Reptiles and Amphibians', *Veterinary Clinics of North America: Exotic Animal Practice*, 19(3), 689-706.

© 2016. This manuscript version is made available under the CC-BY-NC-ND 4.0 license <http://creativecommons.org/licenses/by-nc-nd/4.0/>.

The full details of the published version of the article are as follows:

TITLE: Anatomy and Disorders of the Oral Cavity of Reptiles and Amphibians

AUTHORS: Joanna Hedley

JOURNAL: *Veterinary Clinics of North America: Exotic Animal Practice*

PUBLISHER: Elsevier

PUBLICATION DATE: September 2016

DOI: [10.1016/j.cvex.2016.04.002](https://doi.org/10.1016/j.cvex.2016.04.002)

Anatomy and Disorders of the Oral Cavity of Reptiles and Amphibians

Joanna Hedley BVM&S DZooMed (Reptilian) DipECZM (Herpetology) MRCVS*

RVC Exotics Service

Royal Veterinary College

Royal College Street

London

NW1 0TU

The Author has nothing to disclose.

Keywords: Reptile, amphibian, oral, stomatitis, neoplasia

*corresponding author for proof and reprints

jhedley@rvc.ac.uk

Phone number: 00 44 207 387 8134

KEY POINTS

- A wide variety of disorders may be seen affecting the reptile and amphibian oral cavity. Problems can be easily missed by owners until they are at an advanced stage due to the difficulty of examining the oral cavity at home.
- Many problems are secondary to an inappropriate environment or diet and may be related to systemic disease, so a full history and clinical examination is always required.
- Treatment of oral disorders requires a holistic approach including correction of any predisposing factors in order for long-term successful resolution of the problem.

Anatomy and Physiology of the oral cavity

The oral cavity in reptiles and amphibians can vary significantly between the different orders and even between species. A clear understanding of the normal anatomy is therefore important, in order to be able to identify and understand abnormalities that may occur.

The reptile oral cavity

Reptiles are usually divided by their skull structures into two groups; either anapsids or diapsids.¹ Anapsids have a simple skull structure lacking true temporal openings, and chelonians are the only extant members of this group. Other reptiles have a diapsid or modified diapsid skull structure with temporal openings, which are particularly well developed in lizards and snakes.

Dentition varies among different families, but if present, teeth are composed of enamel, dentine and cement similar to those of other vertebrates². However, teeth are typically homodont (the same shape) and lack a periodontal membrane, so instead are directly ankylosed to the surrounding bone. In many species, teeth are reabsorbed and replaced

multiple times throughout their life, a process known as polyphyodonty. A new tooth generally appears lingually to the older tooth, which is subsequently shed. Usually this process occurs in waves starting at the back of the oral cavity and progressing to the front. Those snakes and lizards hatching from eggs also possess an “egg tooth” modified from the premaxillary teeth in order to rupture the shell. Chelonians, crocodylians and tuatara instead possess an “egg caruncle” composed of horny tissue, which serves the same purpose. This is lost or reabsorbed soon after hatching.

Skin folds or lips seal the oral cavity in squamates, but are absent in chelonians and crocodylians. The oral cavity itself is lined by a mucous membrane consisting of squamous non-keratinized epithelial cells, ciliated epithelial cells, columnar epithelial cells and mucous glands³. Mucous membranes can vary in color and may be pigmented, but should normally be moist. Salivary glands are present but vary between groups of reptiles, and tongue morphology is also variable depending on species. The glottis is located at the base of the tongue in chelonians and most lizards, whereas in snakes it can be easily visualised further rostrally. The palate is incomplete in all reptiles except crocodylians, which have evolved their own unique adaptations to separate the oral and respiratory systems and allow them to hunt underwater. The oral cavity and nasal cavity in other reptiles are linked by a pair of recesses (choanal openings). Eustachian tubes connect the oral cavity to the middle ear in those species in which a middle ear is present.

Chelonians

Chelonians have a relatively simple yet sturdy skull structure, and unlike other reptiles can only open their mouth by lowering the mandible. They also lack teeth, so cannot chew their food. Instead, they have a keratinised horny beak (rhamphotheca) similar to that of birds,

which overlies the osseous jaws. This is used for prehension, and ridges in the hard palate are also present in herbivores to help them grip and tear pieces of food. Despite their lack of teeth, the bite of a chelonian can be strong due to the adductor muscles running through a trochlear pulley system increasing their force¹. Some species such as Snapping turtles (*Chelydra* spp.) also have very sharp cutting edges to their jaws, so bites can cause significant damage.

Within the oral cavity, a short fleshy tongue is present with the glottis at its base (Fig. 1). The tongue aids with swallowing food and numerous taste buds are present both on the tongue and elsewhere in the oral epithelium. Simple salivary glands are present, which produce mucus but no digestive enzymes.

Lizards

Lizards have a more developed kinetic skull, which allows them to both lift their maxilla and lower their mandible simultaneously, resulting in a large gape. They also have a quadrate bone without any firm connection, which can easily move backwards and forwards. This process is known as streptostyly, which further increases the potential gape of the mandible. This process combined with strong adductor muscles can result in a powerful bite.¹ Dentition in lizards depends on species and feeding habits, but unlike chelonians and snakes, lizards can chew their food. Lizard species can generally be split into those that have pleurodont dentition such as iguanids and varanids, and those that have acrodont dentition such as agamids and chameleonids.² Pleurodont teeth are attached to the lingual side of the jawbone and are shed and replaced regularly throughout the animal's life. In contrast, acrodont teeth are firmly attached to the crest of the jaw bone, and are rarely replaced. Hence, the dental disorders seen in this group of lizards.

The morphology of the tongue also depends on species, but in general, lizards possess a mobile protrusible tongue with the glottis present at its base (Fig. 2). The tongue may be used for catching food, swallowing, lapping water, or to bring scent particles to the Jacobson's organ for olfaction. For example, varanids and teiids have a forked tongue resembling that of a snake, and appear to use it to collect chemical scents in a similar way. In other lizards such as the Green iguana (*Iguana iguana*) the rostral tip of the tongue is a darker color, which is a completely normal finding¹. Taste buds appear abundant in those species with fleshy tongues but poorly developed in those with keratinized tongues. Salivary glands are present, and specialised oral glands include the venom glands found in the Mexican beaded lizard (*Heloderma horridum*) and Gila monster (*Heloderma suspectum*).⁴ In these species, neurotoxic venom is produced from the sublingual glands in the lateral lower mandible and secreted via ducts on the labial surface. Grooved teeth lie adjacent to these ducts to ensure that venom can be transferred to its target.

Snakes

The snake skull is even more kinetic than the lizard skull, being composed of very flexible mobile bones and a loosely connected quadrate bone, which can move forwards and backwards freely. Snakes however, have no mandibular symphysis with the overlying flexible skin allowing an even greater range of movement of the two sides of the mandibles than is possible in lizards. Each half of the skull can be moved separately to allow the snake to clamp down on large prey and then gradually advance the jaw forward, one side at a time to push the prey further back within the oral cavity. After eating, snakes will often be seen to gape widely to reposition the jaw bones.¹

Dentition in snakes is pleurodont and most species also possess an extra maxillary arcade of teeth² (Fig. 3). Teeth are long, curved and point caudally within the oral cavity. Food is not

chewed but swallowed whole, so teeth usually function solely for food prehension. Numerous salivary glands are present which produce copious amounts of saliva to aid with swallowing.⁴ Venomous species have maxillary teeth modified into fangs and venom is produced in modified labial salivary glands. Different species have different compositions of venom but its composition often includes a mixture of collagenases, proteases and phospholipases. In rear-fanged (opisthoglyphous) species such as some colubrids, venom is produced in a gland behind the eye and just above the lips called the Duvernoy's gland. Venom is transferred from here by modified grooved fangs at the caudal maxilla. In front-fanged snakes, the venom glands are found separate from the labial glands behind the eye and linked by a duct to fangs at the rostral maxilla. In proteroglyphous species such as elapids, fangs remain erect at all times whereas in solenoglyphous species such as viperids, fangs are folded backwards within a sheath when the oral cavity is closed. These can then be raised by contraction of the pterygoid muscles when required for striking. The tongue is generally very mobile with a slender, long, forked appearance and kept in a sheath under the glottis. A notch at the rostral aspect of the oral cavity allows the tongue to be protruded even when the mouth is closed. The glottis is very mobile and can be shifted to one side when eating large prey to allow the snake to keep breathing.

· *Crocodylians*

Crocodylians have a true diapsid skull structure with extremely strong adductor muscles able to close the jaws with great force. The muscles which open the mouth are in contrast fairly weak, so the jaws can be easily taped shut for safe handling if examination of the oral cavity is not required⁵. Dentition in crocodylians is different from other reptiles as teeth are embedded within a bony socket similar to mammals but without the periodontal membranes.² This arrangement is known as thecodont. Teeth are conical; they are shed and replaced

approximately every two years (Fig. 4). The new tooth develops from germinal tissue within the socket and eventually dislodges the pre-existing tooth. Food is not chewed; instead pieces are swallowed whole. The tongue cannot protrude from the oral cavity due to its strong attachment to the ventral surface and even within the mouth is relatively immobile. At the caudal margin, the tongue fuses with a transverse fold separating the oral cavity from the pharynx. This overlaps with a transverse fold formed by the end of the palate ensuring complete separation of the oral cavity from the respiratory system and allowing the animal the capability to hold prey underwater without drowning.⁵ The tongue being immobile cannot aid in swallowing, so the snout must be raised to allow food to fall backwards into the pharynx instead.

The amphibian oral cavity

Amphibian skull structures can be highly variable and are often incompletely ossified.¹ However, all adult amphibians are carnivorous and generally have a large wide oral cavity (Fig. 5).

If present, teeth are jointed, composed of a crown loosely attached to a base or pedicel which is then attached to the jaw. Similar to some reptiles, teeth are shed and replaced thoroughly life and generally pointed caudally. They are not generally used for chewing, but simply for prehending food. The layout of teeth depends on species; for example, salamanders, caecilians and some anurans have one or two arcades of maxillary and mandibular teeth, whereas ranid frogs do not have any mandibular teeth. On the roof of the mouth, small groups of teeth may also be present, known as the vomerine and palatine tooth patches. Tongue morphology varies depending on species, but can often be very flexible, extending up to 80% of the total length of the animal to prehend food in some species. Swallowing occurs

by the animal raising the floor of the mouth and closing the eyelids to force the globes ventrally and push the food caudally into the pharynx. Most species have salivary glands but these simply produce mucus rather than aiding in digestion.

Disorders of the oral cavity in reptiles

Infectious stomatitis

Stomatitis is a common presentation in captive reptiles and may occur for a variety of reasons. However, it is usually secondary to an underlying deficit in husbandry or diet leading to immunosuppression. Examples include inappropriate environmental temperatures, inappropriate hibernation or nutritional disease.⁶ Stomatitis may also be seen secondary to the disruption of normal oral tissue due to trauma or neoplasia, or alternatively in association with concurrent problems such as renal disease. If left untreated, disease may progress to involve the surrounding bone and respiratory tract and eventually lead to septicaemia and death.

Bacterial stomatitis

The normal oropharynx contains a wide range of aerobic and anaerobic micro-organisms including both Gram-positive and Gram-negative bacteria.⁷ However, the Gram-negative bacteria are usually the most common organisms to overgrow in cases of stomatitis, and result in pathology. *Pseudomonas*, *Aeromonas*, *Proteus* and *Escherichia coli* are all commonly isolated from cases of stomatitis.⁸ Anaerobic bacteria may also be isolated including *Bacteroides*, *Fusobacterium*, *Clostridium* and *Peptostreptococcus*.⁹ Animals may

be presented due to non-specific symptoms such as reduced appetite and lethargy, or owners may have noticed visible changes in the oral cavity. On clinical examination, the oral mucosa often appears erythematous and swollen with pockets of abscessation (Fig. 6, 7). Lesions should be distinguished from the white tophi deposited in visceral gout, which may also be seen within the oral cavity.

The initial diagnostic approach to stomatitis should include a full history and clinical examination to identify any predisposing factors or systemic disease. Hematology and biochemistry may be indicated if systemic disease is suspected. Radiography of the skull is advised in moderate to severe cases of stomatitis to identify the extent of any potential bone involvement. This will usually need to be performed under general anaesthesia to obtain adequate views. Following initial assessment, oral lesions can then be sampled for microbiological culture and sensitivity to help guide selection of appropriate antibiotic therapy. Pending results, third generation cephalosporins, fluoroquinolones and aminoglycosides have all been used successfully in the treatment of bacterial stomatitis due to the prevalence of Gram-negative bacteria usually seen.¹⁰ General anaesthesia may need to be considered to allow debridement, flushing and initial topical treatments, although follow up treatments may potentially be performed in the conscious animal. Topical treatments include dilute chlorhexidine, dilute povidone-iodine and silver sulphadiazine ointment. Analgesia will also be required for this potentially very painful condition. Non-steroidal anti-inflammatories are most commonly used, but it is important to ensure that the animal is well hydrated and there are no concerns with renal function. As many of these animals have been anorexic for a prolonged time period, rehydration and supportive feeding may initially be required.

In the case of chronic non-healing lesions within the oral cavity, infection with atypical bacteria such as *Mycobacterium* species should also be considered.¹¹ These cases often

present as granulomatous or haemorrhagic lesions within the oral cavity (Fig. 8). More non-specific symptoms of mycobacteriosis such as lethargy and weight loss may also be seen if infection has spread systemically. Treatment is generally unsuccessful and due to the zoonotic implications, euthanasia should be considered.

- *Viral stomatitis*

Viral stomatitis may be seen as either a primary or secondary problem in reptiles. Potential pathogens include herpesviruses in chelonians¹² and lizards,^{13,14} and ranaviruses in chelonians¹⁵. Herpesvirus infection in chelonians appears common throughout the captive population, often in association with *Mycoplasma* infection. Animals may be presented for lethargy, reduced appetite, hypersalivation, dysphagia or sometimes concurrent respiratory signs including ocular or nasal discharges. On oral examination, yellow diphtheritic lesions may be visualised within the oral cavity. They can be very large, to the point that they impair the animal's ability to eat. Diagnosis can be confirmed by taking an oral swab for polymerase chain reaction (PCR). False negatives can however occur, as the herpesvirus can lie dormant within the body, only resulting in a clinical problem at times of immunosuppression. Treatment is mainly symptomatic although oral acyclovir has been trialled at 40-80 mg/kg every 8-24 hours with variable success.

- *Fungal stomatitis*

Fungal stomatitis usually occurs secondary to inappropriate husbandry and often in association with bacterial stomatitis. Pathogens reported include *Candida albicans*, *Aspergillus*, *Sporothrix schenkii* and *Paecilomyces spp.*^{16,17} Diagnosis is based on fungal culture of affected lesions. Treatment with systemic antifungals is usually required in

addition to topical agents as infection is often systemic. Treatment may need to be continued for at least 4-6 weeks.

· *Parasitic stomatitis*

Parasitic stomatitis is rarely seen, as most parasites carry out their life cycle further within the alimentary system, but occasional parasites may be found encysted within the oral cavity.¹⁸ An example would be the pentastomids (tongue worms) which may be seen in wild-caught reptiles, especially snakes. Animals may be presented for respiratory symptoms or excessive mucus in the mouth. Parasites can be found in the pharynx where they bury deeply into tissues resulting in inflammation and secondary infection and may need to be physically removed. An intermediate host is required for the parasite to complete its life cycle so infections are generally self-limiting in captivity. However, these parasites do have zoonotic potential so care should be taken when dealing with parasitized infected animals.¹⁹

Infectious cheilitis

Although primarily a dermatological problem, infection with the gram positive rod, *Devriesia agamarum* may result in significant cheilitis in some species, especially spiny-tailed lizards (*Uromastyx spp*)²⁰ (Fig. 9). Unlike bearded dragons (*Pogona spp.*) which usually carry this bacteria asymptotically as part of their normal oral flora,²¹ infection in spiny-tailed lizards appears to result in severe hyperkeratotic dermatitis and cheilitis. Infection can normally be confirmed by bacterial culture and can be successfully treated with intramuscular administration of ceftiofur at 5 mg/kg every 24 hours for an average of 12 days in *Uromastyx spp.*²² If left untreated however, signs may progress to potentially result in septicemia and death.

Periodontal disease

Periodontal disease is generally seen in acrodont lizards such as bearded dragons, and appears to be a disease of captivity.^{23,24} Inappropriate diets such as too many soft fruits or waxworms are thought to result in the development of plaque, subsequent bacterial colonisation and then gingivitis and calculus formation. Initial bacteria involved are normally Gram-positive aerobic cocci, but as the disease progresses anaerobic bacteria, Gram-negative bacteria and spirochetes may also become involved and underlying bone may become affected. The animal may be presented for reduced appetite or lethargy, but often the owner is unaware of the extent of the problem and periodontal disease is only detected incidentally on clinical examination. Gingival erythema, proliferation and calculus deposition is normally obvious on oral examination (Fig. 10, 11). In more advanced cases, abscessation and discoloration of the associated bone may also be seen. As in cases of stomatitis, radiography under general anaesthesia is recommended to assess the extent of infection. An ultrasonic dental scaler may then be used to remove calculus, and an antibacterial solution such as 0.05% chlorhexidine can be used to clean and flush the oral cavity. Prevention of periodontal disease involves dietary changes to reduce bacterial build up and increase removal of plaque.

Neoplasia

A variety of tumors have been identified in the oral cavity in reptiles including squamous cell carcinoma, fibroma, fibrosarcoma, fibropapilloma, melanoma, iridophoroma and ameloblastoma.²⁵⁻³¹ Tumors may vary widely in appearance and initially often resemble lesions seen in infectious stomatitis. Biopsies are therefore strongly recommended for any

non-resolving cases of presumed infectious stomatitis. Surgical excision is the preferred option for treatment of oral tumors if complete excision is possible. Radiation therapy has been trialled and is a potential option depending on the location of the tumor.^{25,32} Otherwise treatment is generally palliative including treatment of any secondary infections, analgesia as appropriate and dietary modifications as necessary. Ultimately if neoplasia is progressing to potentially cause pain or impact on the animal's ability to feed, euthanasia should be considered.

Congenital

Congenital disorders are not uncommonly seen in reptiles including maxillary brachygnathism, mandibular brachygnathism and defects of the palate.³³ Causes are often unknown but may include genetic defects or environmental factors during incubation or gravidity such as inappropriate temperatures or chemical exposure. Many animals can live with mild defects as long as their ability to feed is not compromised. In more severe cases, euthanasia may need to be considered.

Nutritional

Nutritional secondary hyperparathyroidism

Nutritional secondary hyperparathyroidism may result in a range of clinical signs, but oral disorders are generally associated with changes in the facial bones. Mandibles may appear thickened and swollen due to fibrous osteodystrophy. Over time, significant deformities may be seen due to the pressures applied by the attached jaw muscles (Fig. 12). Stomatitis may

result from constant gingival and mucosal exposure in those animals unable to fully close their mouth. On clinical examination, the jaw may feel extremely flexible and care needs to be taken not to cause iatrogenic mandibular fractures when examining the oral cavity (Fig. 13).

Alternatively in some species such as chameleons the muscles of the tongue may be seen to noticeably weaken resulting in difficulties extending and retracting and subsequent damage.³⁴ Diagnosis is usually based on clinical signs but radiography will confirm reduced bone density. Other causes of metabolic bone diseases such as renal hyperparathyroidism should also be ruled out. Long-term treatment consists of improving diet and supplementation to provide an appropriate level of calcium, phosphorus and vitamin D, in addition to correction of any environmental deficits such as inappropriate temperatures or UVB light provision. Analgesia should be considered especially in cases with mandibular fractures. Supportive feeding may also be required. The need for additional feeding and medication should however, be balanced with the potential pain and stress of opening the oral cavity in these animals. Placement of an esophagostomy tube may therefore be preferred in order to avoid excessive handling in some patients. However, euthanasia should be considered for advanced cases, especially if return to normal feeding is not considered likely and the animal's quality of life is judged to be compromised.

Hypovitaminosis C

In the majority of reptiles, Vitamin C is synthesised in the kidneys and therefore not required in the diet. However, hypovitaminosis C has been reported in boas and pythons and could potentially result in signs of spontaneous gingival bleeding similar to scurvy in other animals. This could therefore be a potential differential diagnosis for lesions in these species.³³

Hypovitaminosis E and selenium deficiency

Hypovitaminosis E and selenium deficiency has been suggested to be the cause of a nutritional myopathy seen in a veiled chameleon (*Chamaeleo calyptratus*).³⁵ The chameleon was presented for a progressive inability to open its mouth and use its tongue. Post-mortem examination revealed histopathological lesions of myodegeneration and myolysis consistent with those seen in other animals with nutritional myopathy. A similar syndrome has also been reported in another veiled chameleon unable to open its mouth, but in this case histopathologic lesions were consistent with a fibrosing myopathy and cause could not be determined.³⁶

Trauma

Reptiles can often sustain severe trauma to the oral cavity. In captive animals, one of the most commonly seen examples of this is rostral trauma. This appears especially common in flighty species such as water dragons (*Physignathus spp.*) who often run head first into the sides of their enclosure when startled³⁴ (Fig. 14). Damage to the snout may also be seen in some snakes which may fail to perceive glass barriers and attempt to strike through them. In mild cases with only superficial abrasions, lesions are often self-limiting as long as the environmental cause is corrected. Providing an appropriate quiet secluded environment with plenty of areas to hide should reduce traumatic incidents. Placing opaque material such as tape on any glass surfaces should also reduce the risks of a snake not perceiving the glass wall and striking at it. However, with repeated injuries, the underlying tissue may become secondarily infected and both stomatitis and osteomyelitis may result. These cases will need more intensive management with both topical and systemic antibiotics and analgesia as described under treatment of stomatitis.

However, traumatic injuries are not just a result of captivity, and skull fractures have been reported in both wild and captive reptiles. These injuries may interfere with oral function (Fig. 15). Imaging is required for full assessment of the fracture and advanced imaging modalities such as computed tomography can be particularly useful in cases where surgical stabilisation is to be performed. In one case of a wild Eastern bluetongue skink (*Tiliqua scincoides scincoides*) with both maxillary and mandibular fractures, successful stabilisation was achieved using a combination of non-absorbable suture material and an intramedullary pin.³⁷ In another case of a captive Fly River Turtle (*Carretochelys insculpta*) with multiple fractures, an external skeletal fixator was used in combination with pins and cerclage wire for successful fracture repair.³⁸ Alternatively non-surgical treatment using a tape muzzle and intra-oral plate has also been reported to be successful in a bluetongue skink. In this case, placement of an esophagostomy tube was also required to provide nutrition during the healing process.³⁹

Trauma may also occur to soft tissue structures within the oral cavity such as the tongue. This may happen during ingestion of prey or due to ingestion of inappropriate objects by mistake, such as hair or string. Thermal burns may also be seen especially in snakes which are fed prey which has been overheated.¹⁰ Lesions should be cleaned, analgesia provided and secondary infections treated as necessary.

Toxins

The ingestion of toxins usually results in more obvious systemic effects in reptiles, but occasionally stomatitis may be seen. For example, suspected oak (*Quercus*) leaf toxicity has

been reported in an African Spurred tortoise (*Geochelone sulcata*)⁴⁰. Post-mortem, significant oral mucosal ulcerations were noted which was attributed to tannin toxicity. Alternatively, local irritation or gingivitis may also occur following accidental ingestion of any caustic food or liquid.

Beak overgrowth

Beak overgrowth is often seen in captive chelonians in association with accelerated growth, due to either the feeding of high-protein food items or alternatively just large quantities of food. However, other factors such as trauma, congenital defects, hypovitaminosis A or altered keratin synthesis secondary to hepatic disease or dietary deficiency should be considered.⁴¹ Deformities may also be seen in association with metabolic bone diseases as discussed above. Animals often present with deformed upper and lower beaks, nail abnormalities and shell abnormalities such as pyramiding (Fig. 16). As a keratinous structure, the beak can be easily trimmed without sedation in most animals, and use of a tool such as Dremel® or a professional dental burr is advised in order to accurately restore normal beak shape (Fig. 17). Diet should be fully reviewed to identify and correct any predisposing cause, but once the beak is deformed, regular trims are likely to be necessary. Some authors consider lack of abrasive substrate may be a factor, and if so then feeding the animal on an abrasive surface would be recommended to help wear down the beak.⁶

Disorders of the oral cavity in amphibians

Amphibians are susceptible to many of the same oral disorders as those seen in reptiles, but a few common problems are discussed below.

Infectious stomatitis

Stomatitis in amphibians usually occurs secondary to rostral abrasions. Pathogens which may be involved include *Aeromonas hydrophila*, *Citrobacter freundii* and *Pseudomonas spp.* but a variety of Gram-negative bacteria may be isolated.⁴² Secondary fungal infection may also occur. There is little soft tissue overlying the bone in this region, so prompt treatment is vital to prevent infection spreading systemically with potential fatal consequences. Lesions should be gently cleaned and debrided with saline solution and treatment with topical silver sulfadiazine ointment is recommended. Systemic antibiotics or antifungal therapy may then be initiated, ideally based on cytology or culture results.

Neoplasia

A variety of tumors affecting the oral cavity have been reported in amphibians including fibroma, lymphosarcoma, and neuroepithelioma of olfactory origin.^{43,44} Diagnosis has historically been confirmed post-mortem but surgical excision would be the recommended treatment of choice when detected at an early stage.

Nutritional causes

Nutritional secondary hyperparathyroidism is commonly encountered in captive amphibians. Signs may include mandibular thickening and protrusion.⁴⁵ Although the causes and pathogenesis for metabolic bone diseases are similar to those seen in reptiles, Vitamin D3

may play a more significant role. In amphibians, transport of 25-hydroxycholecalciferol relies on availability of lipoproteins.⁴⁶ Inappropriate levels of fatty acids and fats in the diet may therefore lead to reduced availability of the active Vitamin D3 metabolite and the development of metabolic bone disease, despite adequate dietary calcium, phosphorus and Vitamin D3. Otherwise the approach to diagnosis and treatment is similar to that in reptiles.

Hypovitaminosis A is also seen in captive amphibians and has recently been described in association with “short tongue syndrome” in the Wyoming toad (*Anaxyrus baxteri*).⁴⁷ The term originated from early observations that the animals were unable to strike successfully at their prey as their tongue appeared to be too short. Histopathology revealed that the normal non-keratinising, glandular, mucus-producing epithelium of the tongue had been disrupted by squamous metaplasia and consequently the tongue was no longer fully functional.

Hypovitaminosis A should be considered in any captive amphibian fed a primarily insectivorous diet. Diagnosis is usually based on history and clinical signs, as sampling is not normally practical in the live animal. Treatment involves supplementation with Vitamin A which can result in resolution of mild lesions. The diet should ideally be modified in the longer term to prevent further problems.

Trauma

Rostral abrasions are some of the most commonly seen traumatic injuries seen in captive amphibians, especially in particularly nervous animals, who may collide with the sides of their enclosure similar to the behavior seen in the nervous water dragon. Salamanders and newts have also been reported with stomatitis lesions secondary to burrowing attempts when

kept on inappropriate substrate, a syndrome known as atrophic mandibular stomatitis.⁴² As discussed above, prompt treatment is necessary as lesions can progress quickly with potentially fatal consequences.

Foreign body ingestion and subsequent gastrointestinal impaction is commonly seen in amphibians due to their wide gape, but a slightly more unusual presentation was reported in an American toad (*Anaxyrus americanus*), which presented with a reduced appetite and abnormal vocalisation. Examination revealed a firm mass under the tongue which was removed and found to be composed of keratinocytes and necrotic cell debris consistent with impaction of ingested epidermal shed.⁴⁸ Ingestion of shed skin is a normal behaviour and in this case the underlying cause for the impaction was not determined. However, it highlighted abnormal vocalisation as an unexpected clinical sign of oral pathology due to pressure on the glottis in this case.

Summary

A wide variety of disorders may be seen affecting the reptile and amphibian oral cavity. Problems can be easily missed by owners until they are at an advanced stage due to the difficulty of examining the oral cavity at home. Since many problems are secondary to an inappropriate environment or diet and may be related to systemic disease, a full history and clinical examination is always required. Treatment of oral disorders also requires a holistic approach including correction of any predisposing factors in order for long-term successful resolution of the problem.

Figure legends

Figure 1. The normal oral cavity of a tortoise showing the horny beak and short fleshy tongue.

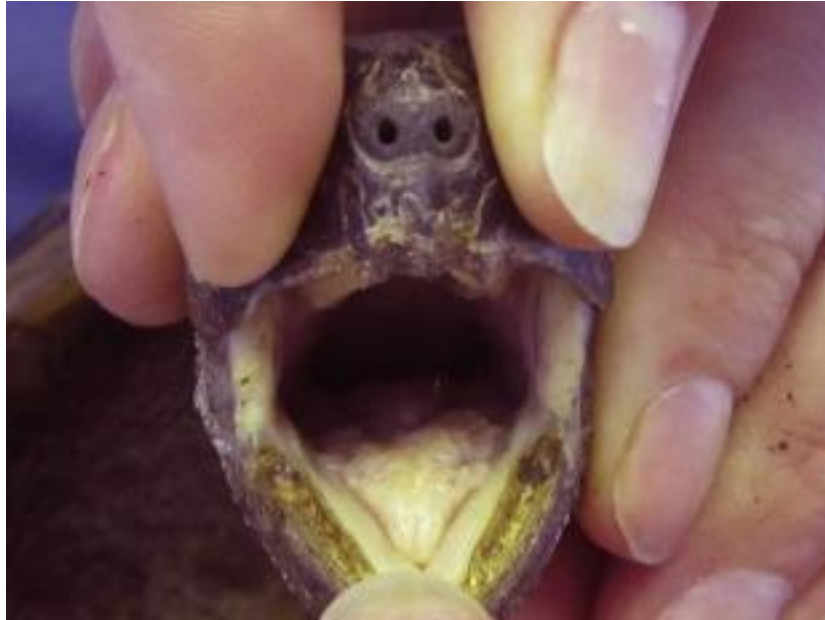

Figure 2. The normal extensible blue tongue of the Blue tongued skink (*Tiliqua scincoides*).



Figure 3. The normal oral cavity of a Corn snake (*Pantherophis guttatus*) showing the extra arcades of teeth (arrows pointing to the left arcade).

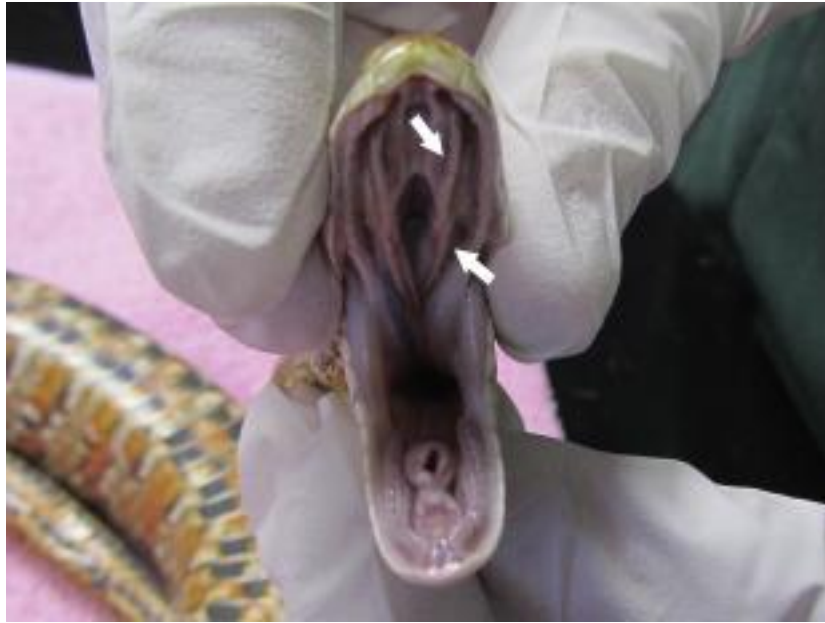

Figure 4. The normal oral cavity of an American crocodile (*Crocodylus acutus*) showing the conical teeth and large gape.



Figure 5. The normal oral cavity of a cane toad (*Rhinella marina*) post-mortem with an endotracheal tube pointing to the glottis.

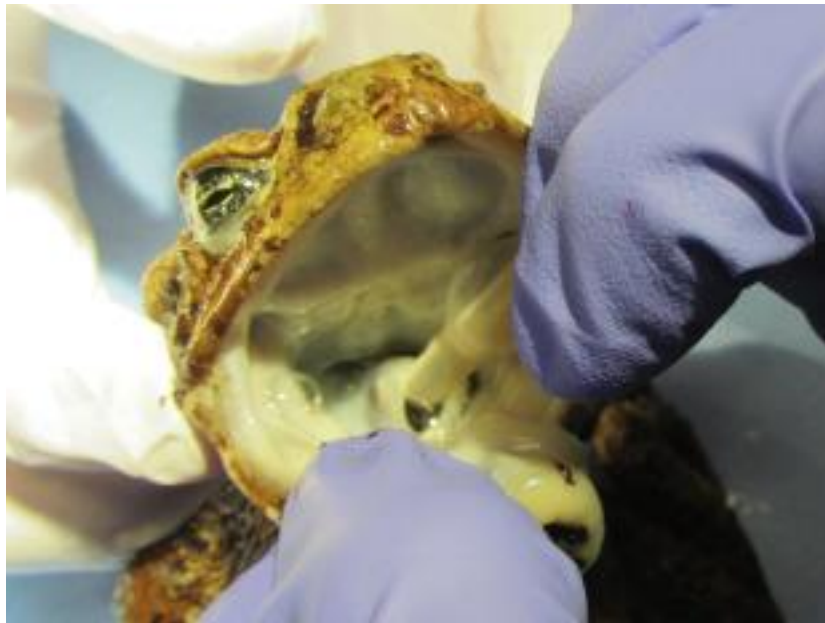


Figure 6. Mild stomatitis in a Red-tailed boa (*Boa constrictor*).

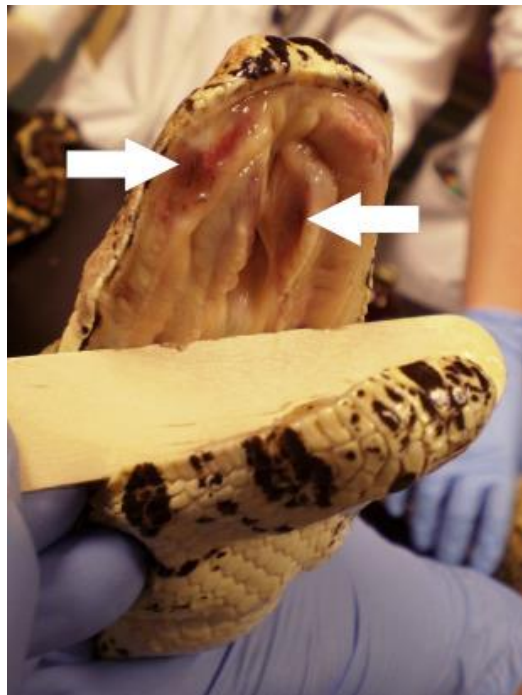


Figure 7. Severe stomatitis in a Corn snake (*Pantherophis guttatus*) (used with permission from Nadene Stapleton, MRCVS).

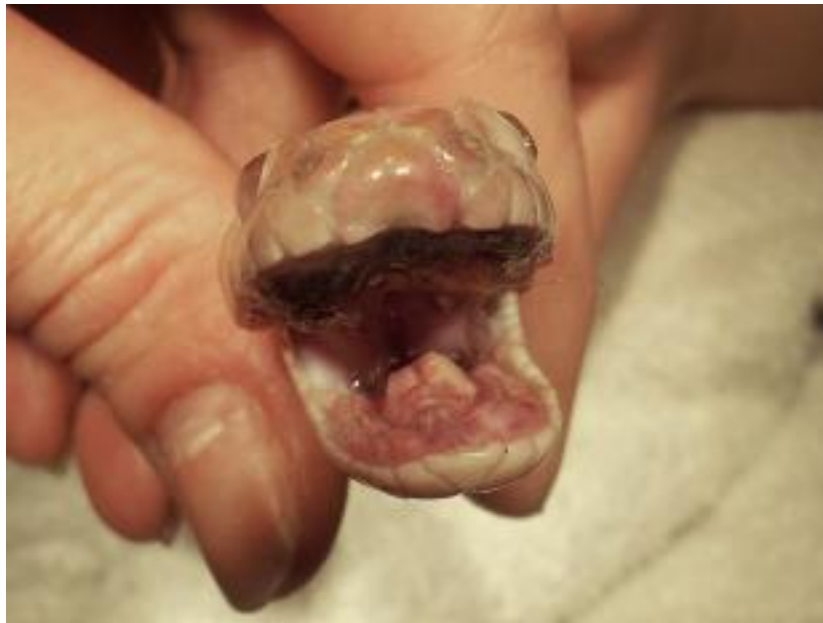

Figure 8. Mycobacterial lesions can present as chronic granulomas as seen in this Red-tailed boa (*Boa constrictor*).

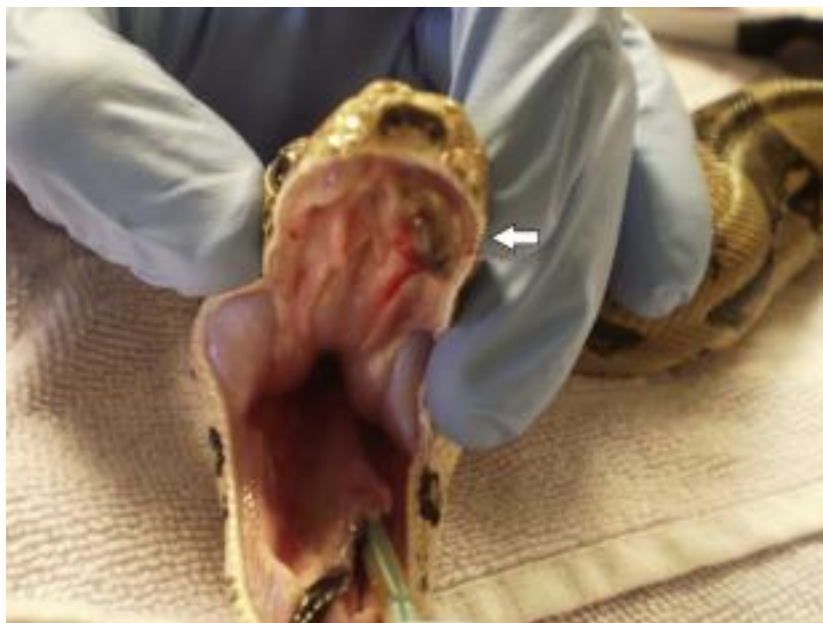

Figure 9. *Devriesia agamarum* infection may result in significant cheilitis as shown in this Bell's Dabb lizard (*Uromastyx acanthinura*).



Figure 10. Periodontal disease in a Bearded dragon (*Pogona vitticeps*).

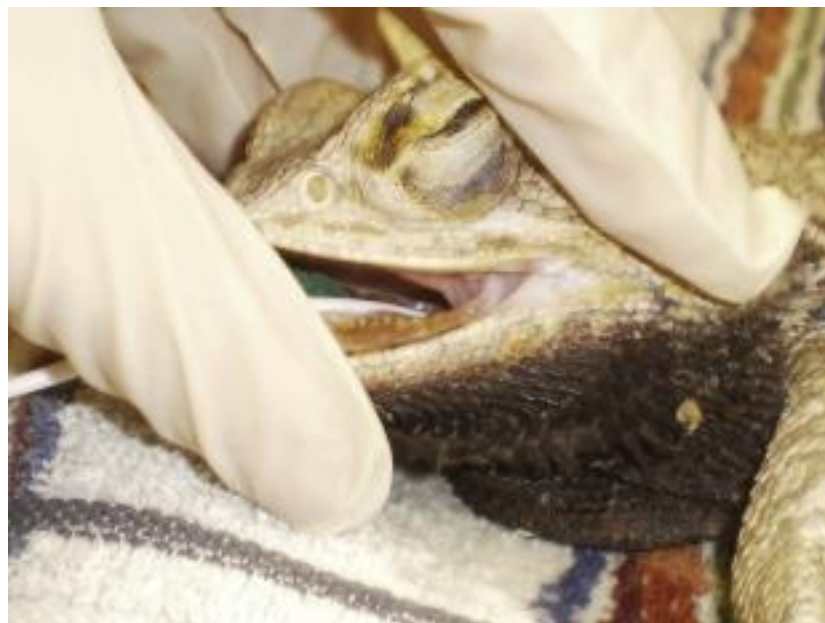

Figure 11. Advanced periodontal disease with gingivitis and osteomyelitis in a Chinese Water dragon (*Physignathus cocincinus*) (used with permission from Marie Kubiak, MRCVS).

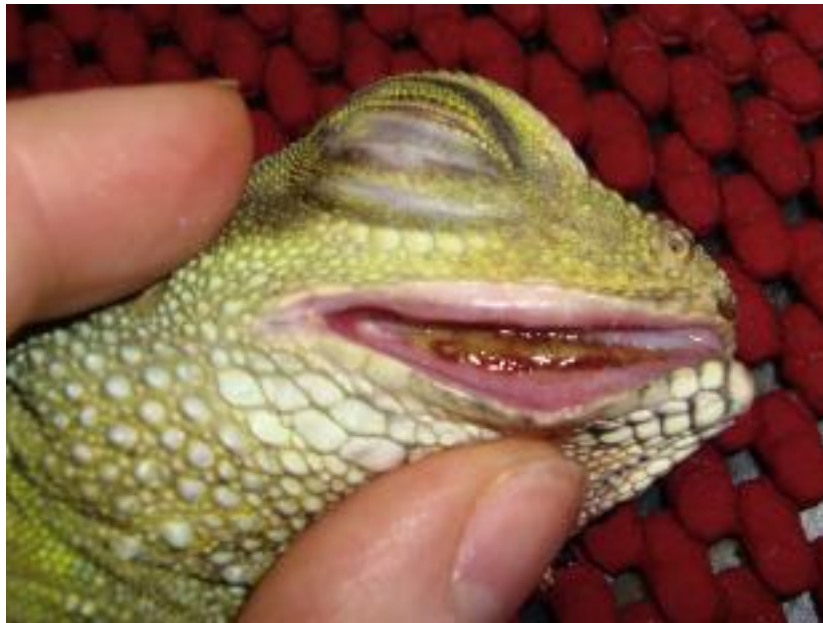

Figure 12. Deformities of the facial bones are a common consequence of nutritional secondary hyperparathyroidism, as seen in this Bearded dragon (*Pogona vitticeps*) which is unable to close its mouth.



Figure 13. The mandible can become very flexible as a consequence of nutritional secondary hyperparathyroidism as seen in this Leopard gecko (*Eublepharis macularius*).

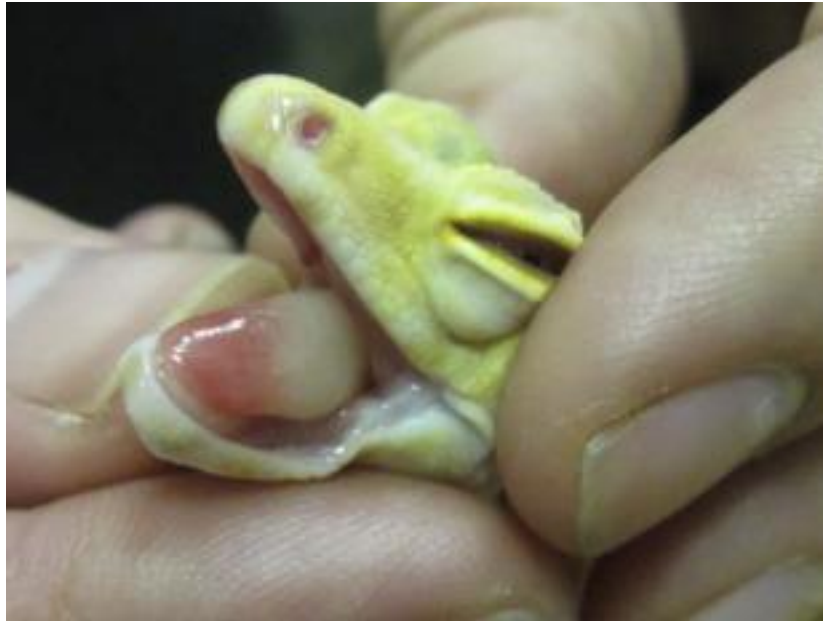

Figure 14. Rostral abrasions and secondary infection in a Chinese Water dragon (*Physignathus cocincinus*) (used with permission from Marie Kubiak, MRCVS).

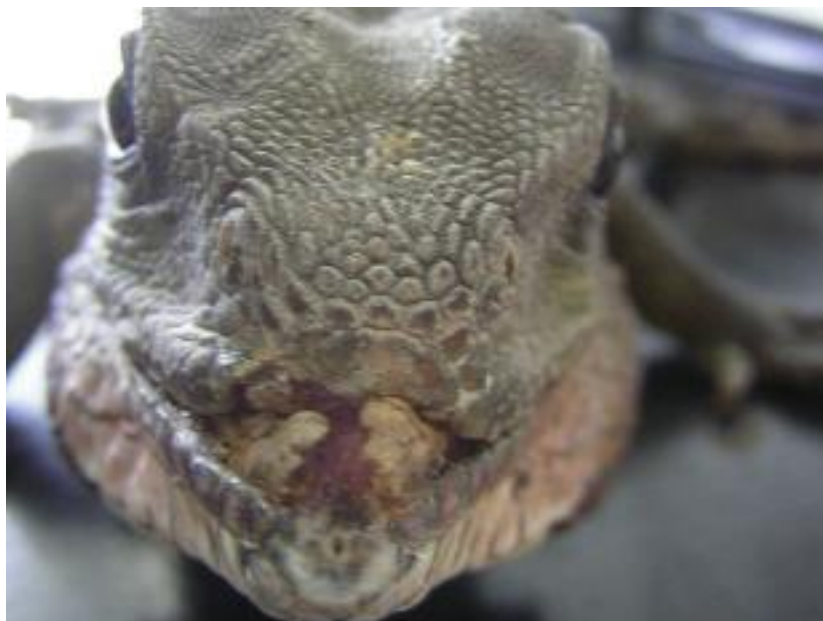

Figure 15. Fracture of the mandible with disruption of the associated oral mucosa and dental arcade in a Chinese Water dragon (*Physignathus cocincinus*).

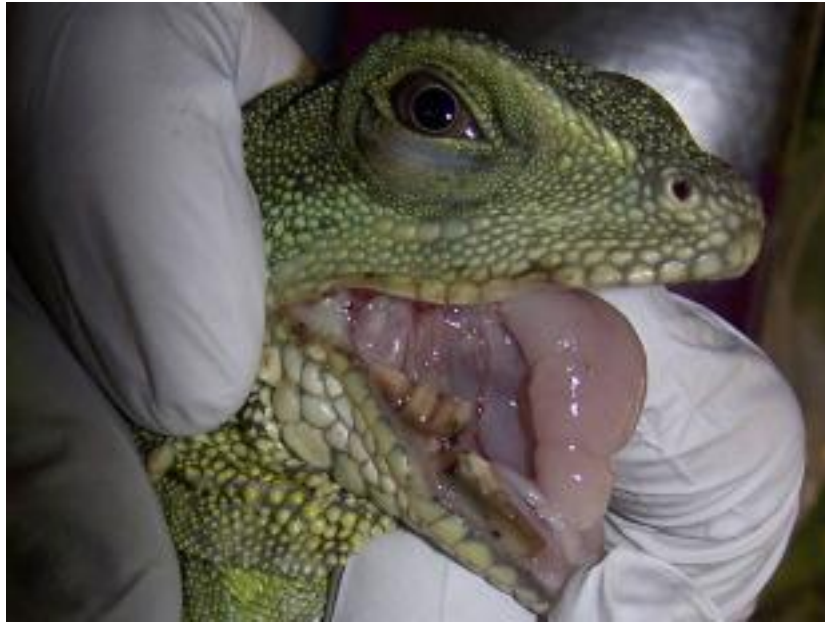
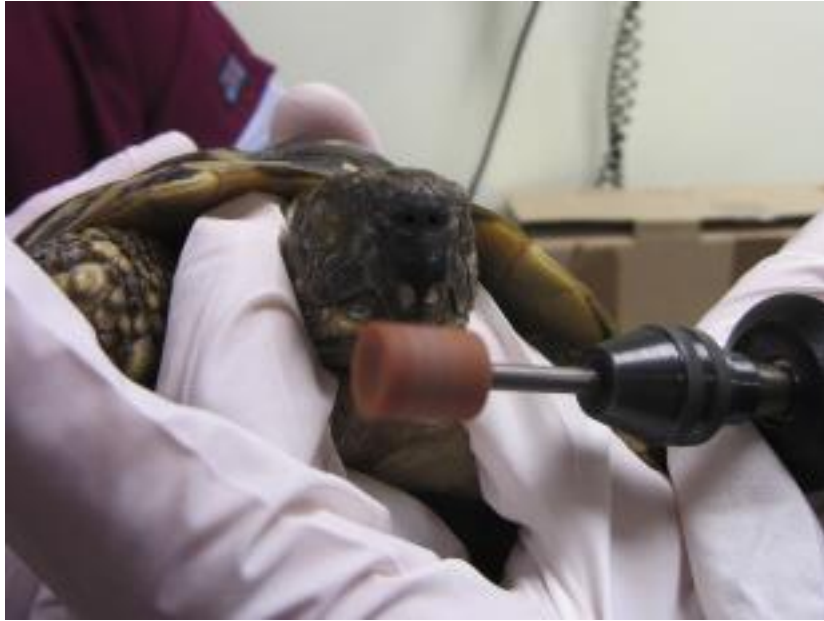
Figure 16. Overgrowth of the rhinotheca in a Hermann's tortoise (*Testudo hermanni*).



Figure 17. Tortoise beaks may be burred using a hand power tool such as a Dremel®.



References

1. O'Malley B. *Clinical Anatomy and Physiology of Exotic Species*. Germany: Elsevier Saunders; 2005.
2. Edmund A. Dentition. In: Gans C, ed. *Biology of the Reptilia, Volume 1, Morphology A*. London: Academic Press; 1970:117-194.
3. Luppia H. Histology Of The Digestive Tract. In: Gans C, Parsons T, eds. *Biology of the Reptilia, Volume 6, Morphology E*. London: Academic Press; 1977:225-313.
4. Kochva E. Oral Glands Of The Reptilia. In: Gans C, Gans K, eds. *Biology of the Reptilia, Volume 8, Physiology B*. New York: Academic Press; 1978:43-161.
5. Lane T. Crocodylians. In: Mader D, ed. *Reptile Medicine and Surgery*. 2nd ed. St Louis, Missouri: Saunders Elsevier; 2006:100-118.
6. McArthur S. Problem-Solving Approach To Common Diseases. In: *Medicine and Surgery of Tortoises and Turtles*. Oxford: Blackwell Publishing Ltd; 2004:301-377.
7. Dipineto L, Russo T, Calabria M, et al. Oral Flora Of *Python regius* Kept As Pets. *Lett Appl Microbiol*. 2014;58(5):462-465.
8. Draper C, Walker R, Lawler H. Patterns Of Oral Bacterial Infection In Captive Snakes. *J Am Vet Med Assoc*. 1981;179(11):1223-1226.
9. Stewart J. Anaerobic Bacterial Infections In Reptiles. *J Zoo Wildl Med*. 1990;21(2):180-184.
10. Mehler S, Bennett R. Upper Alimentary Tract Disease. In: Mader D, ed. *Reptile Medicine and Surgery*. 2nd ed. Malabar: Saunders Elsevier; 2006:924-930.
11. Quesenberry K, Jacobson E, Allen J, Cooley A. Ulcerative Stomatitis And Subcutaneous Granulomas Caused By *Mycobacterium chelonae* In A Boa Constrictor. *J Am Vet Med Assoc*. 1986;189(9):1131.
12. Soares J, Chalker V, Erles K, Holtby S, Waters M, McArthur S. Prevalence Of *Mycoplasma Agassizii* And Chelonian Herpesvirus In Captive Tortoises (*Testudo Sp.*) In The United Kingdom. *J Zoo Wildl Med*. 2004;35(1):25-33.

13. Wellehan J, Nichols D, Li L, Kapur V. Three Novel Herpesviruses Associated With Stomatitis In Sudan Plated Lizards (*Gerrhosaurus major*) And A Black-Lined Plated Lizard (*Gerrhosaurus nigrolineatus*). *J Zoo Wildl Med.* 2004;35(1):50-54.
14. Wellehan J, Johnson A, Latimer K, et al. Varanid Herpesvirus 1: A Novel Herpesvirus Associated With Proliferative Stomatitis In Green Tree Monitors (*Varanus prasinus*). *Vet Microbiol.* 2005;105(2):83-92.
15. Johnson A, Pessier A, Wellehan J, et al. Ranavirus Infection Of Free-Ranging And Captive Box Turtles And Tortoises In The United States. *J Wildl Dis.* 2008;44(5):851-863.
16. Heatley J, Mitchell M, Williams J, Smith J, Tully T. Fungal Periodontal Osteomyelitis In A Chameleon (*Furcifer pardalis*). *J Herpetol Med Surg.* 2001;11(4):7-12.
17. Cheatwood J, Jacobson E, May P, et al. An Outbreak Of Fungal Dermatitis And Stomatitis In A Free-Ranging Population Of Pigmy Rattlesnakes (*Sistrurus miliarius barbouri*) In Florida. *J Wildl Dis.* 2003;39(2):329-337.
18. Griffiths A, Jones H, Christian K. Effect Of Season On Oral And Gastric Nematodes In The Frillneck Lizard From Australia. *J Wildl Dis.* 1998;34(2):381-385.
19. Jacobson E. Parasites And Parasitic Diseases Of Reptiles. In: *Infectious Diseases and Pathology of Reptiles*. Boca Raton: CRC Press; 2007:571-666.
20. Martel A, Pasmans F, Hellebuyck T, Haesebrouck F, Vandamme P. *Devriesea agamarum* Gen. Nov., Sp. Nov., A Novel Actinobacterium Associated With Dermatitis And Septicaemia In Agamid Lizards. *Int J Syst Evol Microbiol.* 2008;58(9):2206-2209.
21. Devloo R, Martel A, Hellebuyck T, Vranckx K, Haesebrouck F, Pasmans F. Bearded Dragons (*Pogona Vitticeps*) Asymptomatically Infected With *Devriesea agamarum* Are A Source Of Persistent Clinical Infection In Captive Colonies Of Dab Lizards. *Vet Microbiol.* 2011;150(3):297-301.
22. Hellebuyck T, Pasmans F, Haesebrouck F, Martel A. Designing A Successful Antimicrobial Treatment Against *Devriesea agamarum* Infections In Lizards. *Vet Microbiol.* 2009;139(1):189-192.
23. McCracken H. Periodontal Disease. In: Fowler M, Miller R, eds. *Zoo and Wild Animal Medicine*. 4th ed. Philadelphia: WB Saunders; 1999.

24. Simpson S. Dragon Breath: Periodontal Disease In Central Bearded Dragons. In: *Proceedings of the Association of Reptile and Avian Veterinarians*. Orlando; 2014:42.
25. Steeil J, Schumacher J, Hecht S, et al. Diagnosis And Treatment Of A Pharyngeal Squamous Cell Carcinoma In A Madagascar Ground Boa (*Boa madagascariensis*). *J Zoo Wildl Med*. 2013;44(1):144-151.
26. Brot S de, Sydler T, Nufer L, Ruetten M. HISTOLOGIC, Immunohistochemical, And Electron Microscopic Characterization Of A Malignant Iridophoroma In A Dwarf Bearded Dragon (*Pogona henrylawsoni*). *J Zoo Wildl Med*. 2015;46(3):583-587.
27. Thompson K, Campbell M, Levens G, Agnew D. Bilaterally Symmetrical Oral Amelanotic Melanoma In A Boa Constrictor (*Boa constrictor constrictor*). *J Zoo Wildl Med*. 2015;46(3):629-632.
28. Idowu A, Golding R, Ikede B, Hill D, Cunningham J, Akerele S. Oral Fibroma In A Captive Python. *J Wildl Dis*. 1975;11(2):201-204.
29. Comolli J, Olsen H, Seguel M, et al. Ameloblastoma In A Wild Black Rat Snake (*Pantherophis alleghaniensis*). *J Vet Diagnostic Investig*. 2015;27(4):536-539.
30. Salinas E, Arriaga B, Lezama J, Bernal A, Garrido S. Oral Fibrosarcoma In A Black Iguana (*Ctenosaura pectinata*). *J Zoo Wildl Med*. 2013;44(2):513-516.
31. Work T, Balazs G, Rameyer R, Morris R. Retrospective Pathology Survey Of Green Turtles *Chelonia mydas* With Fibropapillomatosis In The Hawaiian Islands, 1993-2003. *Dis Aquat Organ*. 2004;62:163-176.
32. Bishop T, Cumming B. Treatment Of A Squamous Cell Carcinoma In A Bearded Dragon (*Pogona vitticeps*) Using Radiation Therapy. In: *Proceedings of Assoc Avian Vet (AC) & Unusual/Exotic Pets*. ; 2014.
33. Frye F. *Biomedical and Surgical Aspects of Captive Reptile Husbandry. Vols I and II*. 2nd ed. Malabar: Krieger Publishing Co; 1991.
34. McArthur S, McLellan L, Brown S. Gastrointestinal System. In: Girling S, Raiti P, eds. *BSAVA Manual of Reptiles*. 2nd ed. Gloucester: BSAVA; 2004:210-229.
35. Rowland M. Fibrosing Myopathy Of The Temporal Muscles Causing Lockjaw In A Veiled Chameleon (*Chamaeleo calytratus*). *Vet Rec*. 2011;169(20):527.

36. Cole G, Rao D, Steinberg H. Suspected Vitamin E And Selenium Deficiency In A Veiled Chameleon (*Chamaeleo calytratus*). *J Herpetol Med Surg*. 2008;18(3-4):113-116.
37. Scheelings T. Surgical Management Of Maxillary And Mandibular Fractures In An Eastern Bluetongue Skink, *Tiliqua scincoides scincoides*. *J Herpetol Med Surg*. 2008;17(4):136-140.
38. Tuxbury KA, Clayton LA, Avian D, Snakard EP, Fishman EK. Multiple Skull Fractures In A Captive Fly River Turtle (*Carretochelys insculpta*): Diagnosis , Surgical Repair , And Medical Management. *J Herpetol Med Surg*. 2010;20(1):11-19.
39. Köchli B, Schmid N, Hatt J, Dennler M, Steinmetz H. Nonsurgical Treatment Of A Bilateral Mandibular Fracture In A Blue-Tongued Skink. *Exot DVM*. 2008;10(2):25-28.
40. Rotstein D, Lewbart G, Hobbie K, J K, C B. Suspected Oak *Quercus* Toxicity In An African Spurred Tortoise, *Geochelone sulcata*. *J Herpetol Med Surg*. 2003;13(3):20-21.
41. Chitty J, Raftery A. *Essentials of Tortoise Medicine and Surgery*. Chichester: Wiley Blackwell; 2013.
42. Wright K. Trauma. In: Wright K, Whitaker B, eds. *Amphibian Medicine and Captive Husbandry*. Melbourne: Krieger Publishing Co; 2001:233-238.
43. Balls M. Spontaneous Neoplasms In Amphibia: A Review And Descriptions Of Six New Cases. *Cancer Res*. 1962;22(10):1142-1154.
44. Brunst V, Roque A. Tumors In Amphibians. I. Histology Of A Neuroepithelioma In *Siredon mexicanum*. *J Natl Cancer Inst*. 1967;38(2):193-204.
45. Antwis R, Browne R. Ultraviolet Radiation And Vitamin D 3 In Amphibian Health, Behaviour, Diet And Conservation. *Comp Biochem Physiol Part A Mol Integr Physiol*. 2009;154(2):184-190.
46. Hay A, Watson G. The Plasma Transport Proteins Of 25-Hydroxycholecalciferol In Fish, Amphibians, Reptiles And Birds. *Comp Biochem Physiol Part B Comp Biochem*. 1976;53(2):167-172.

47. Pessier A. Short Tongue Syndrome And Hypovitaminosis A. In: Mader D, Divers S, eds. *Current Therapy in Reptile Medicine & Surgery*. St Louis, Missouri: Elsevier Saunders; 2014:271-276.
48. Selig M. Subglossal Impaction In An American Toad (*Anaxyrus americanus*). *J Herpetol Med Surg*. 2011;21(1):3-4.